

# 3D Bond™

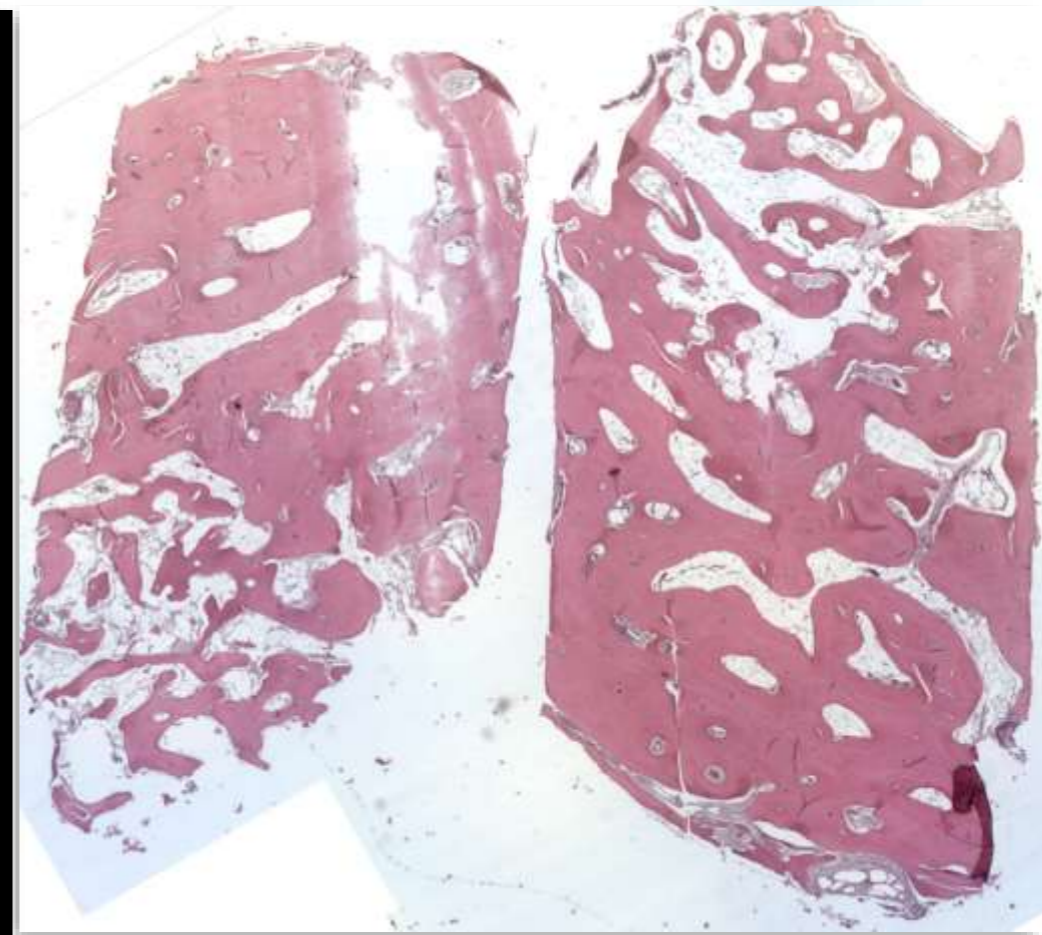


Can be used:

- **By itself** -socket preservation
- **As a composite graft**
- **As a barrier**

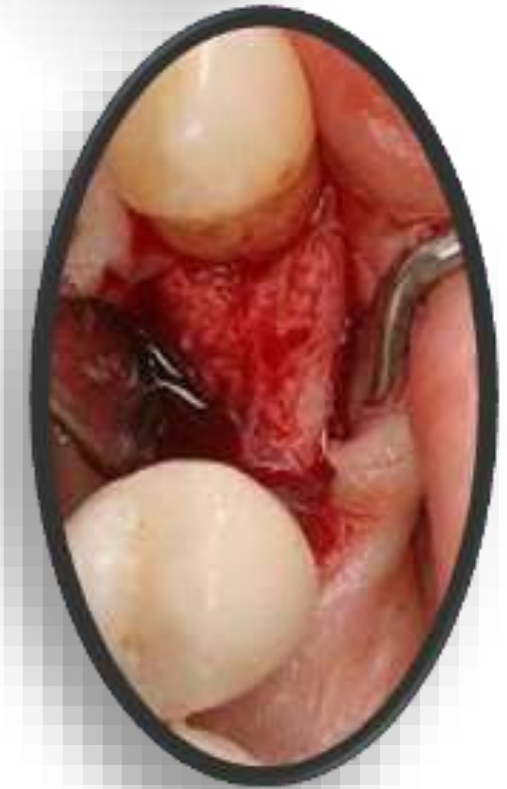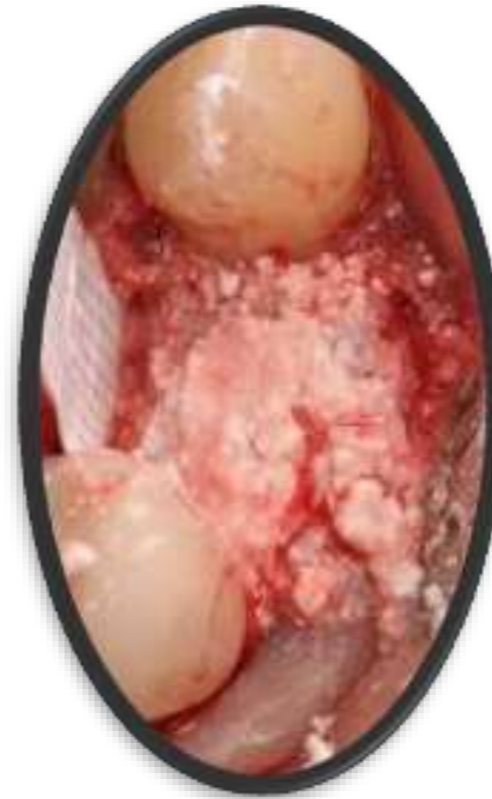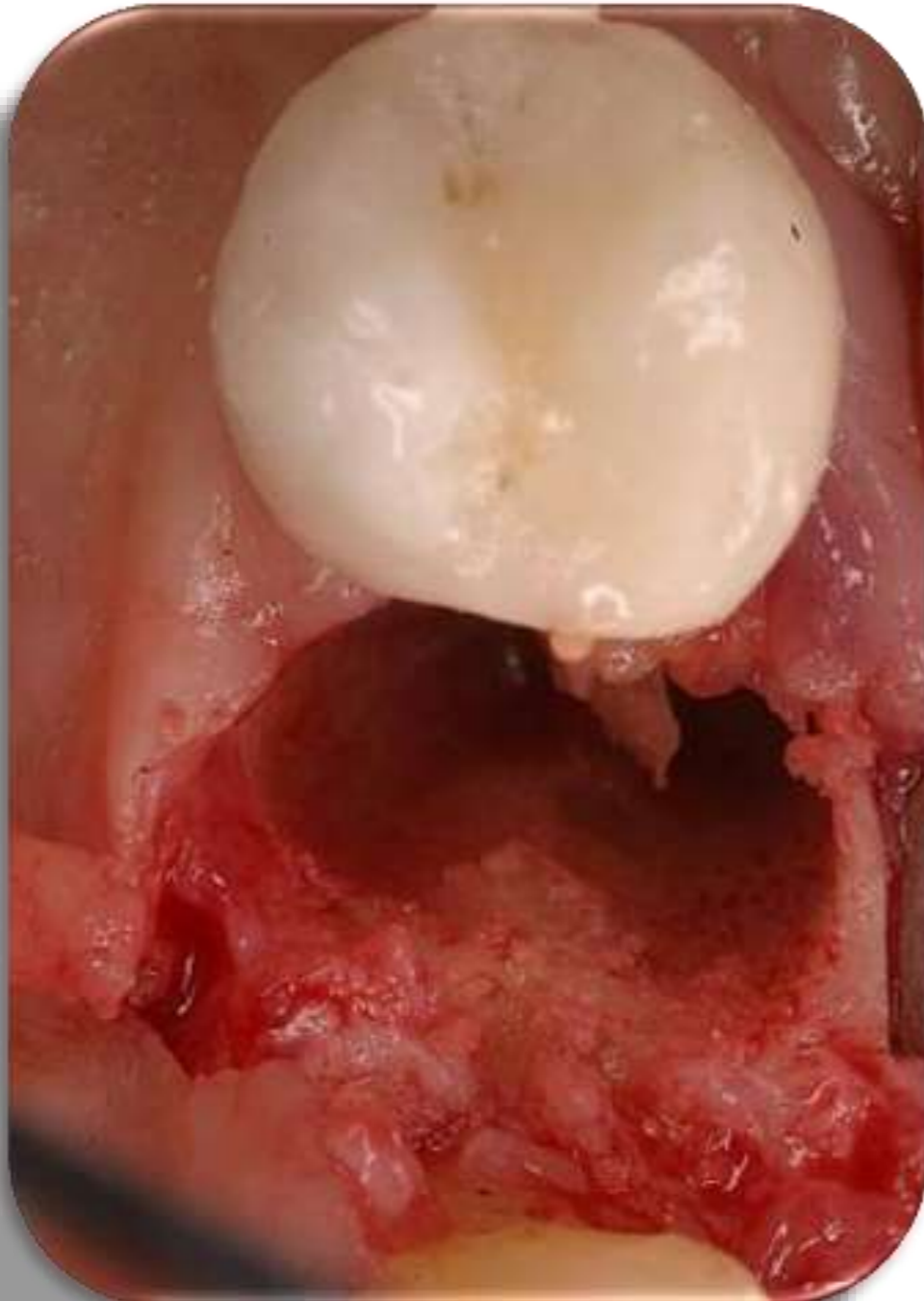


# 100% Regeneration





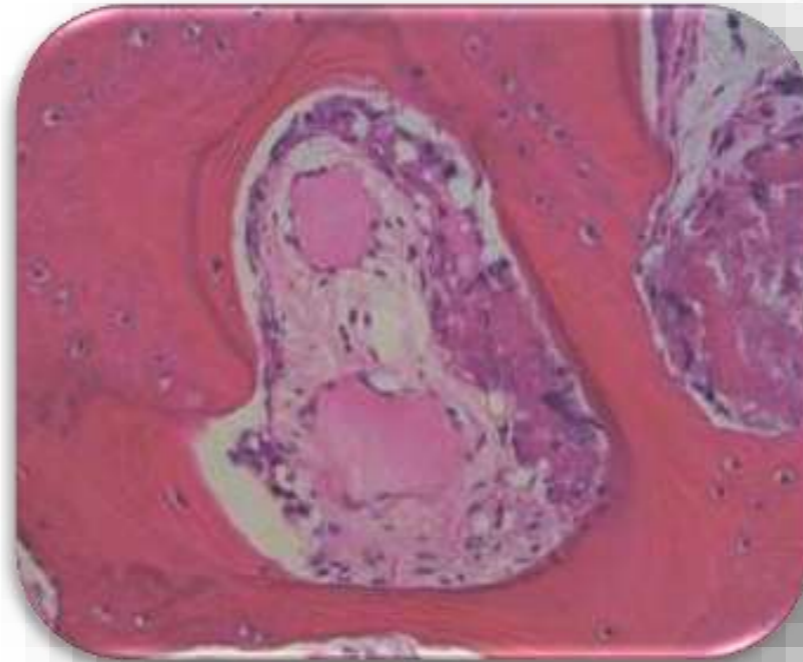
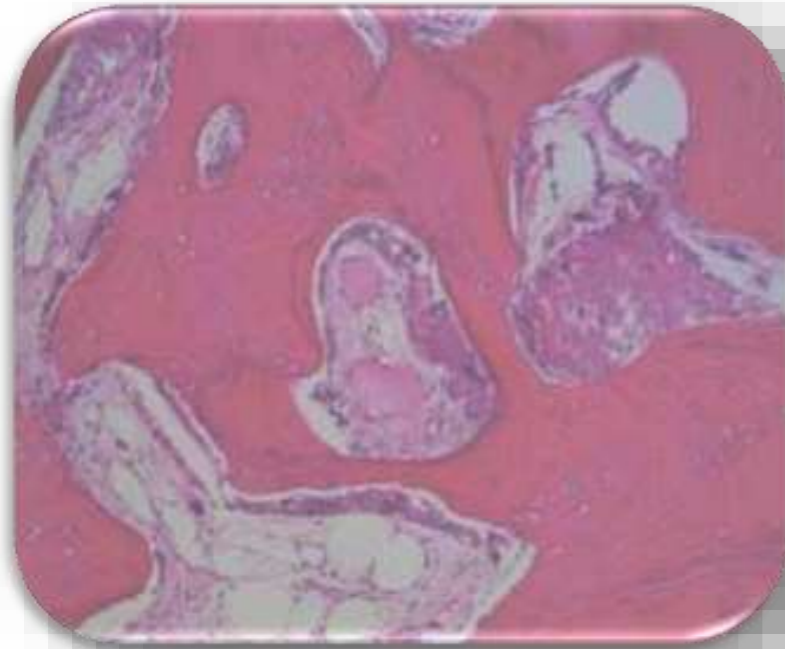
# Socket preservation



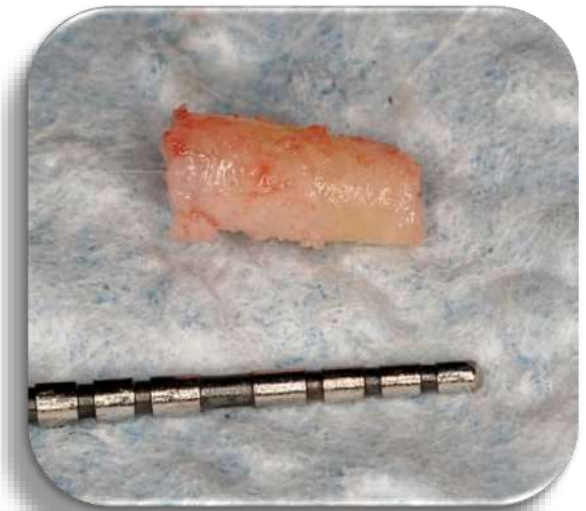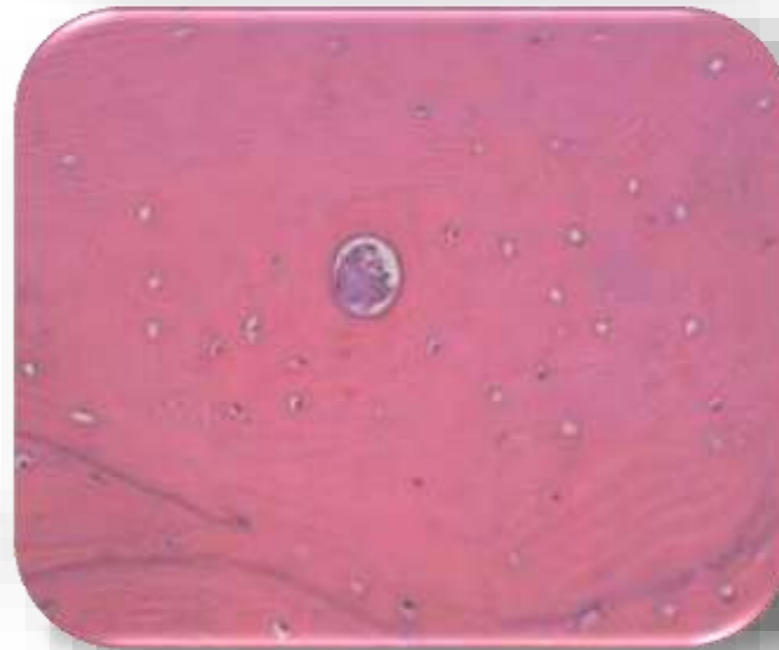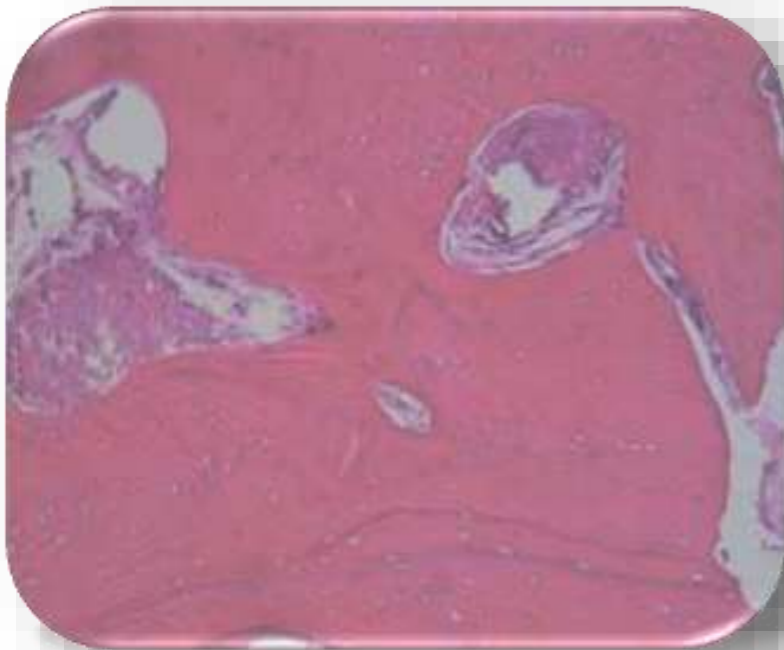**3DBond™**  
Graft Binder Cement

  
**Augma**  
BIOMATERIALS

Surgery was performed by Dr. Robert A. Horowitz, DDS (USA)



New dense lamellar bone can be seen

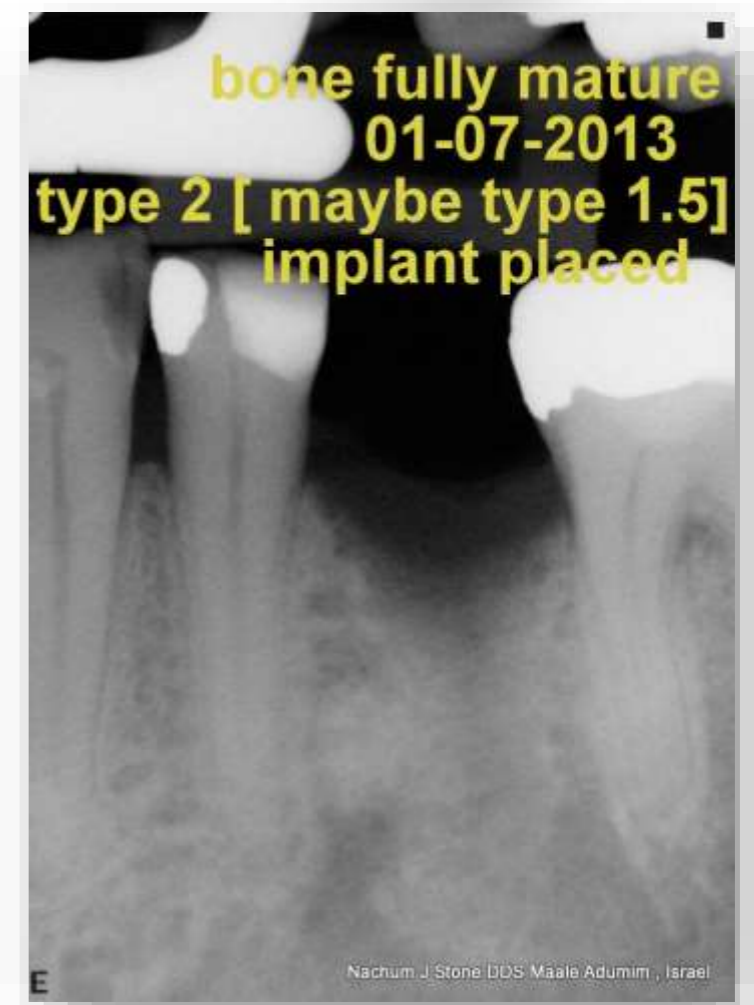
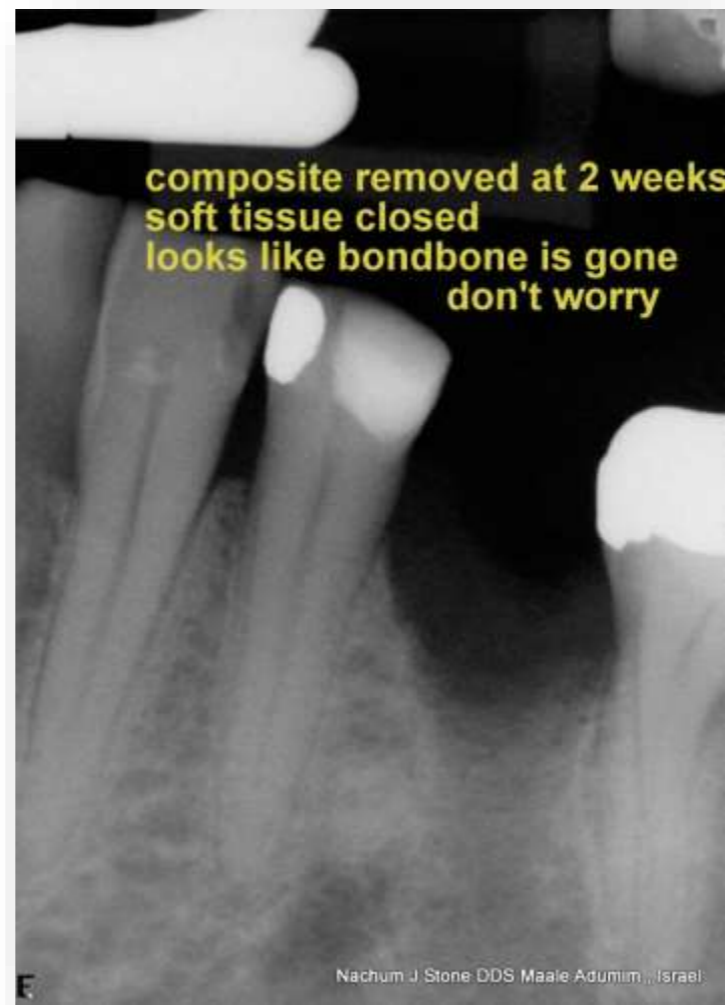
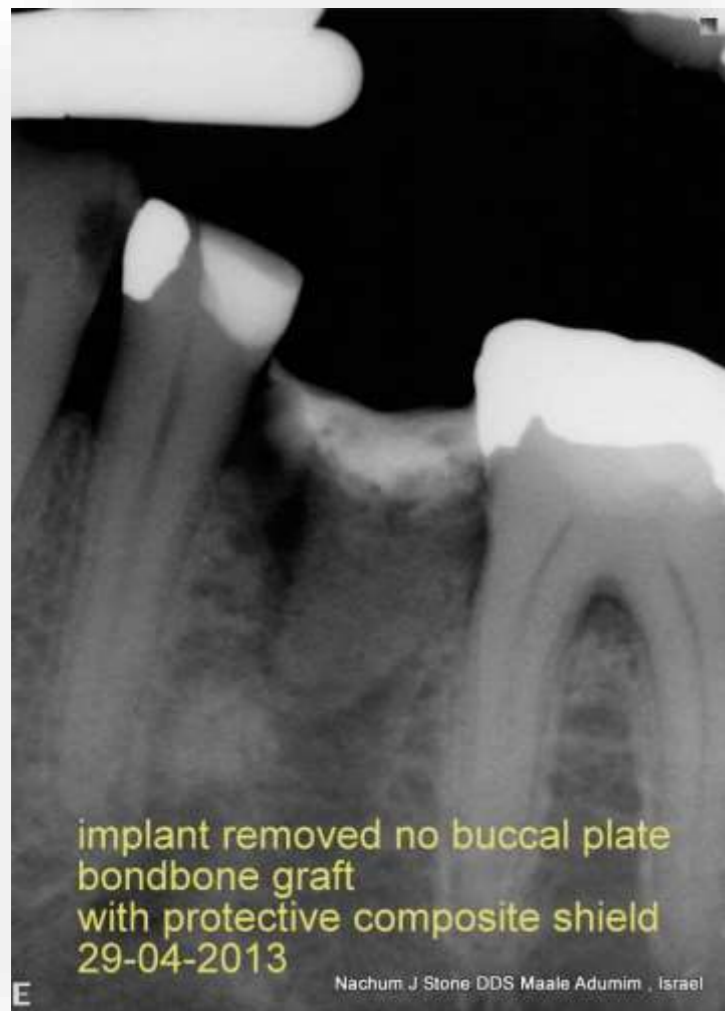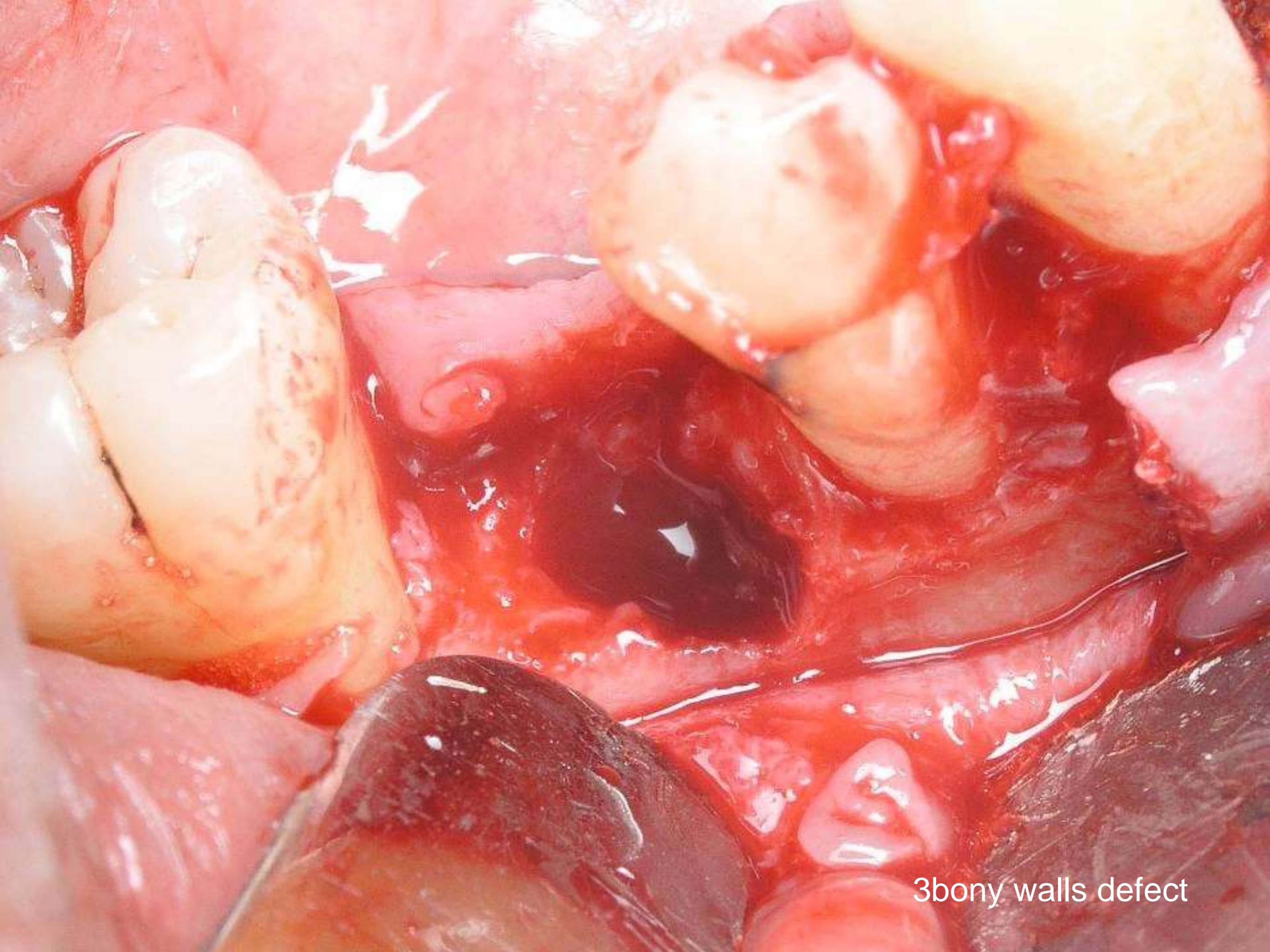
**3DBond™**  
Graft Binder Cement

**Augma**  
BIOMATERIALS

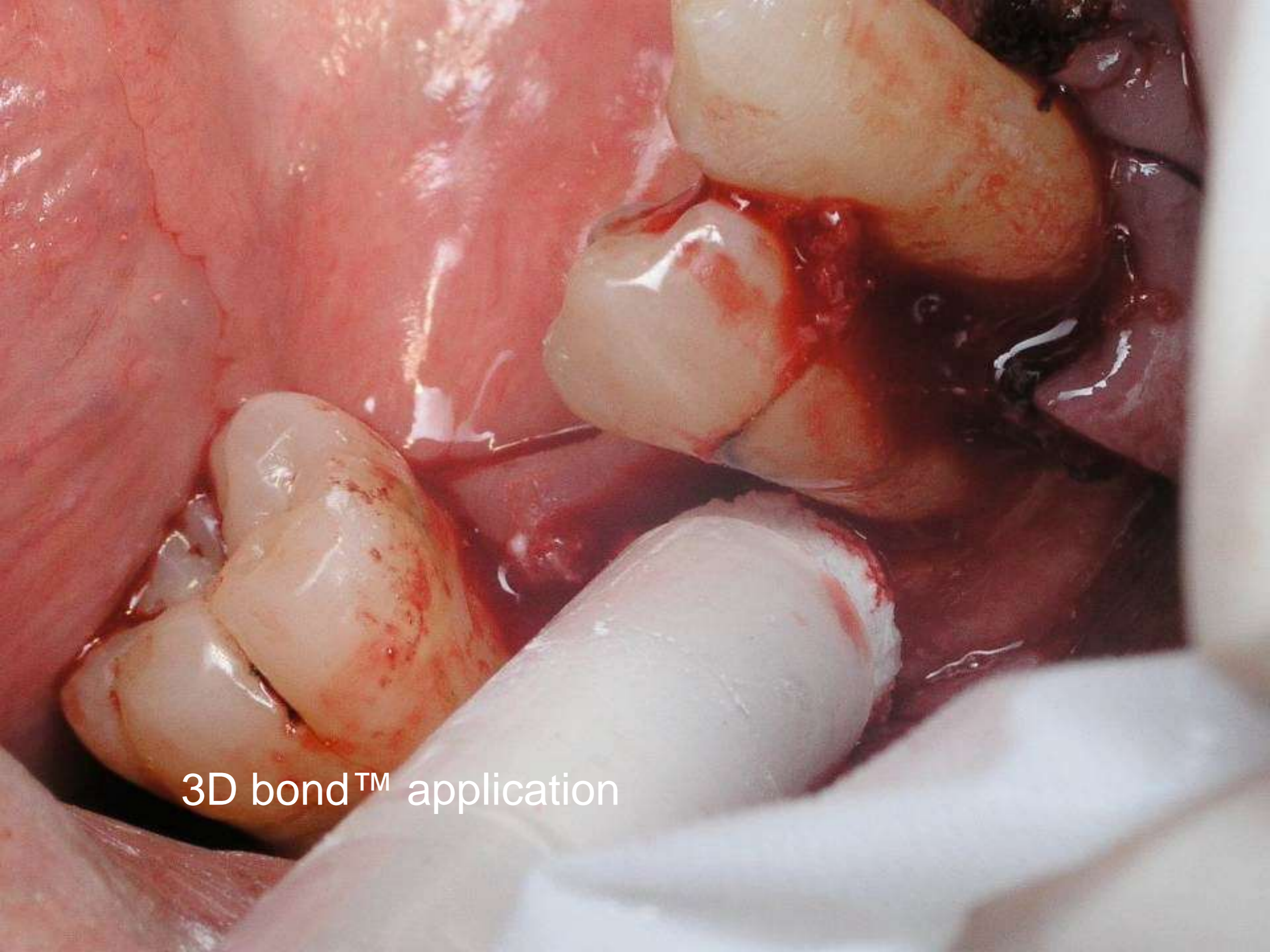
Surgery was performed by Dr. Robert A. Horowitz, DDS (USA)

# 3D bond radiografing behavior during healing

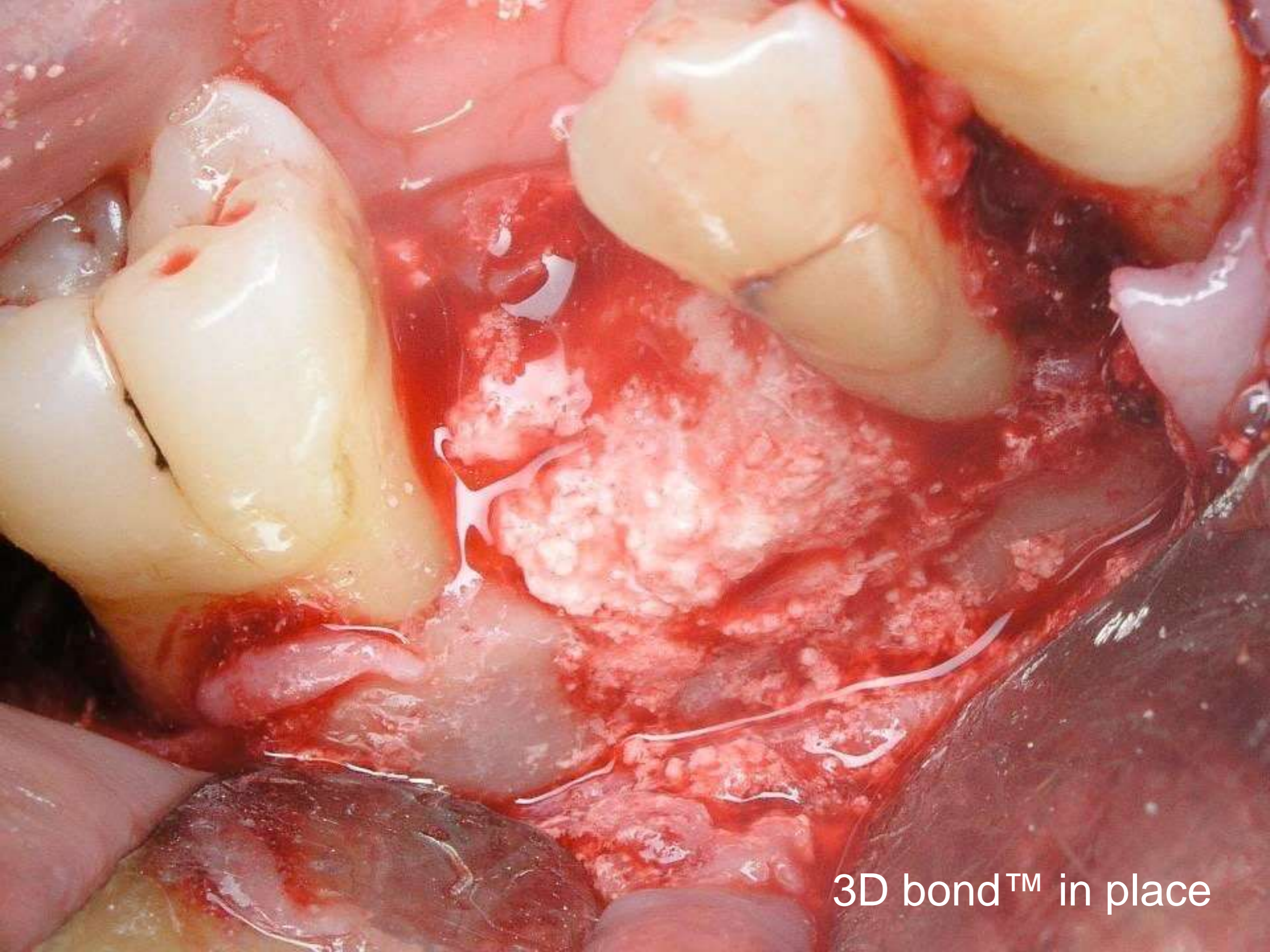




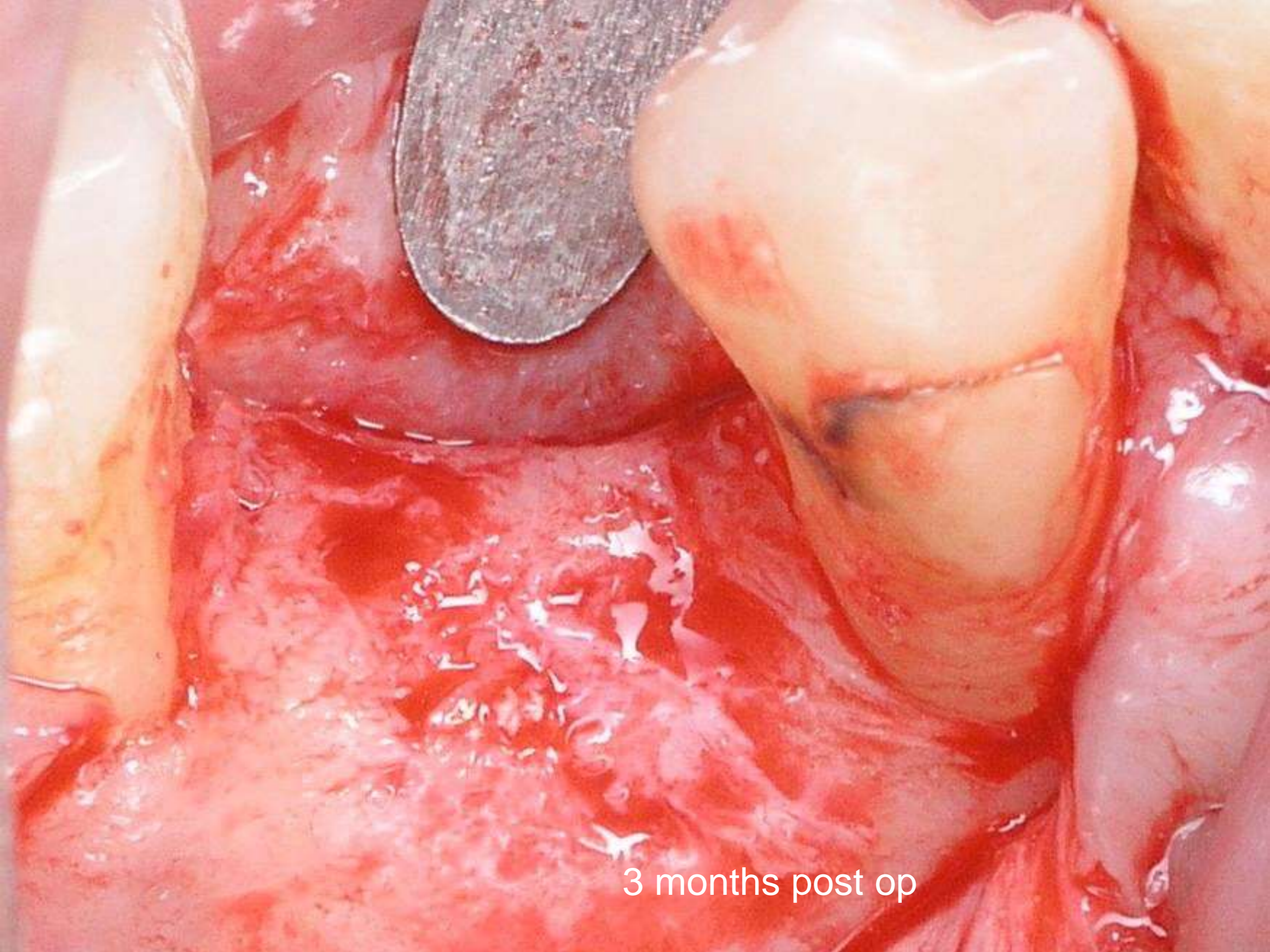
3bony walls defect



3D bond™ application

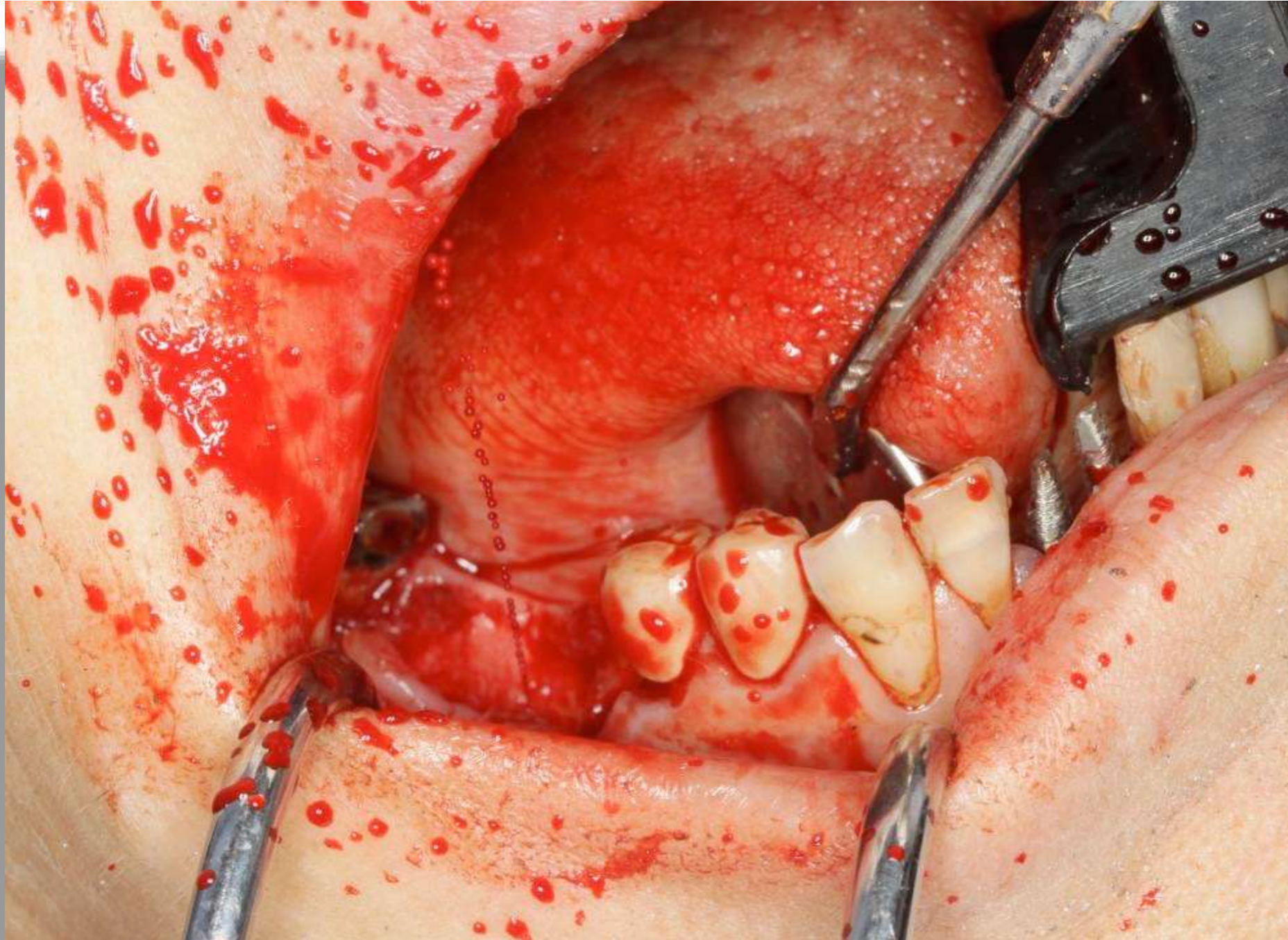


3D bond™ in place



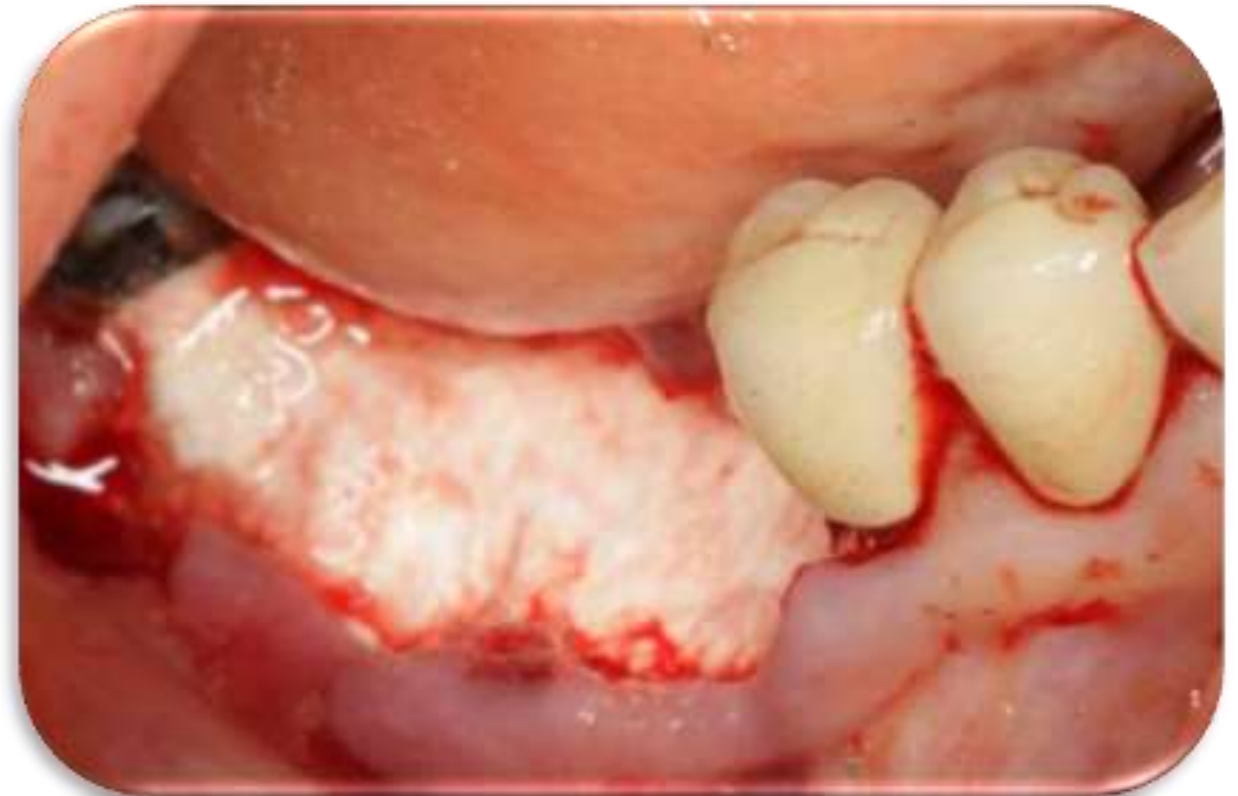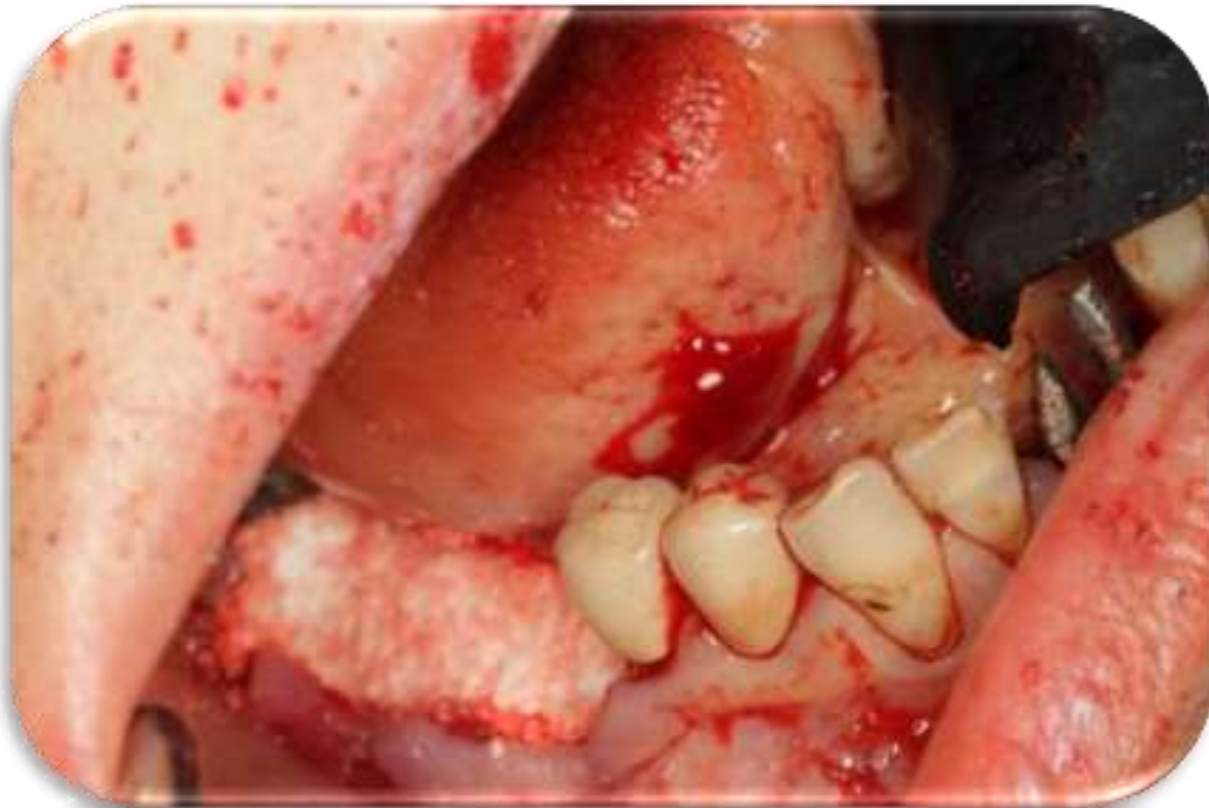3 months post op

# Using 3D Bond™ to control bleeding





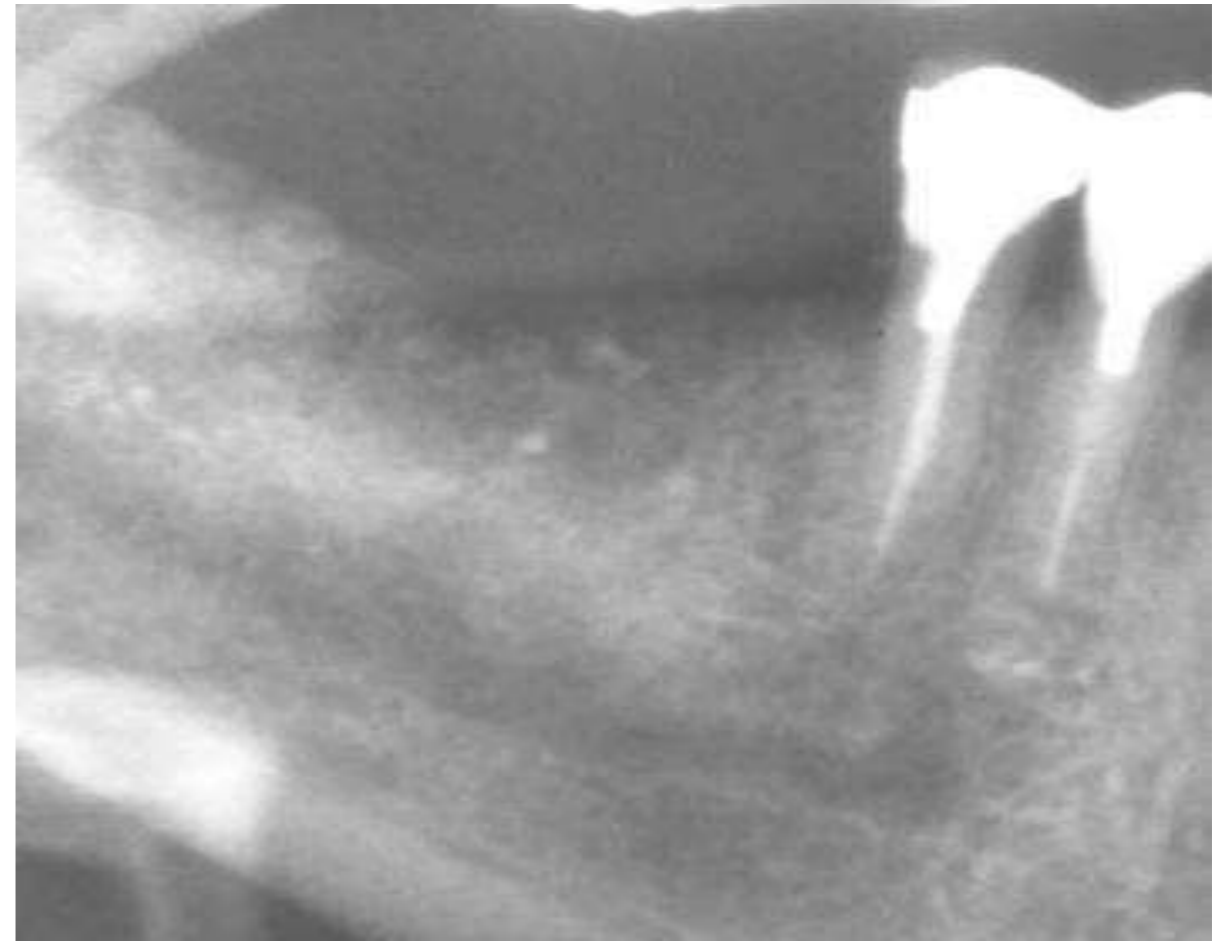
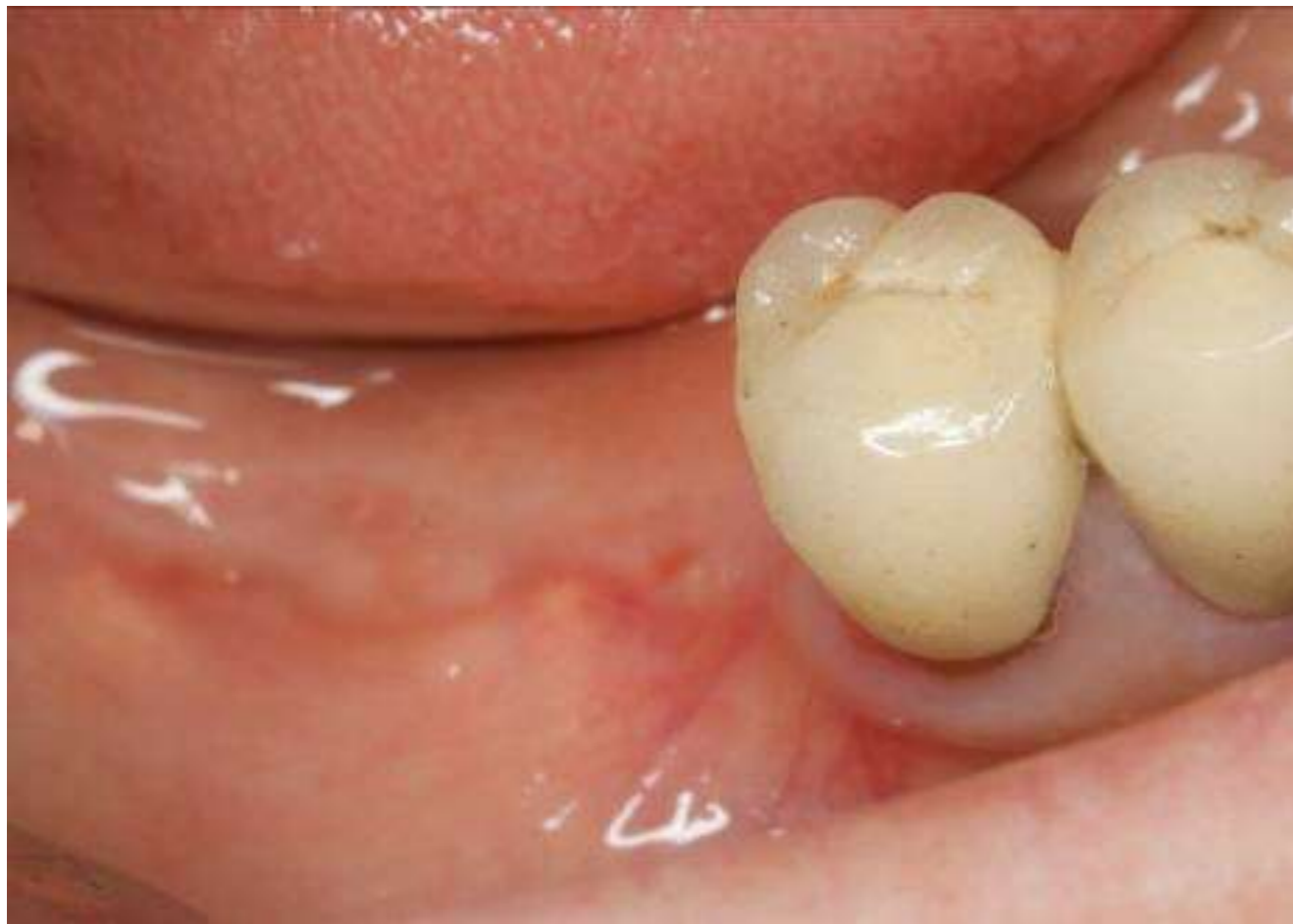Bleeding is stopped instantly after BCS application



# Using BCS to control bleeding



## After 3 months



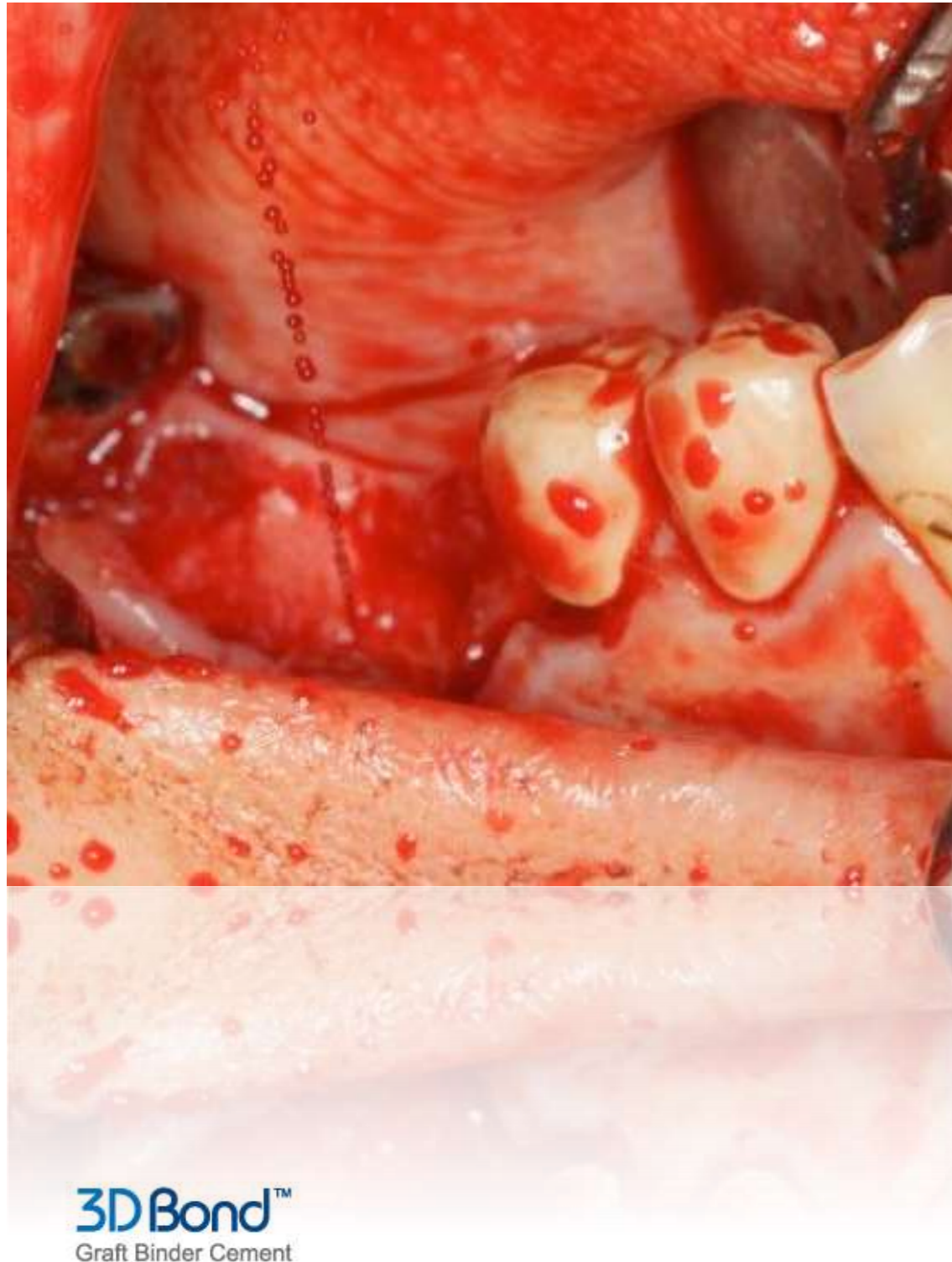**3DBond™**  
Graft Binder Cement

  
**Augma**  
BIOMATERIALS

# Using BCS to control bleeding

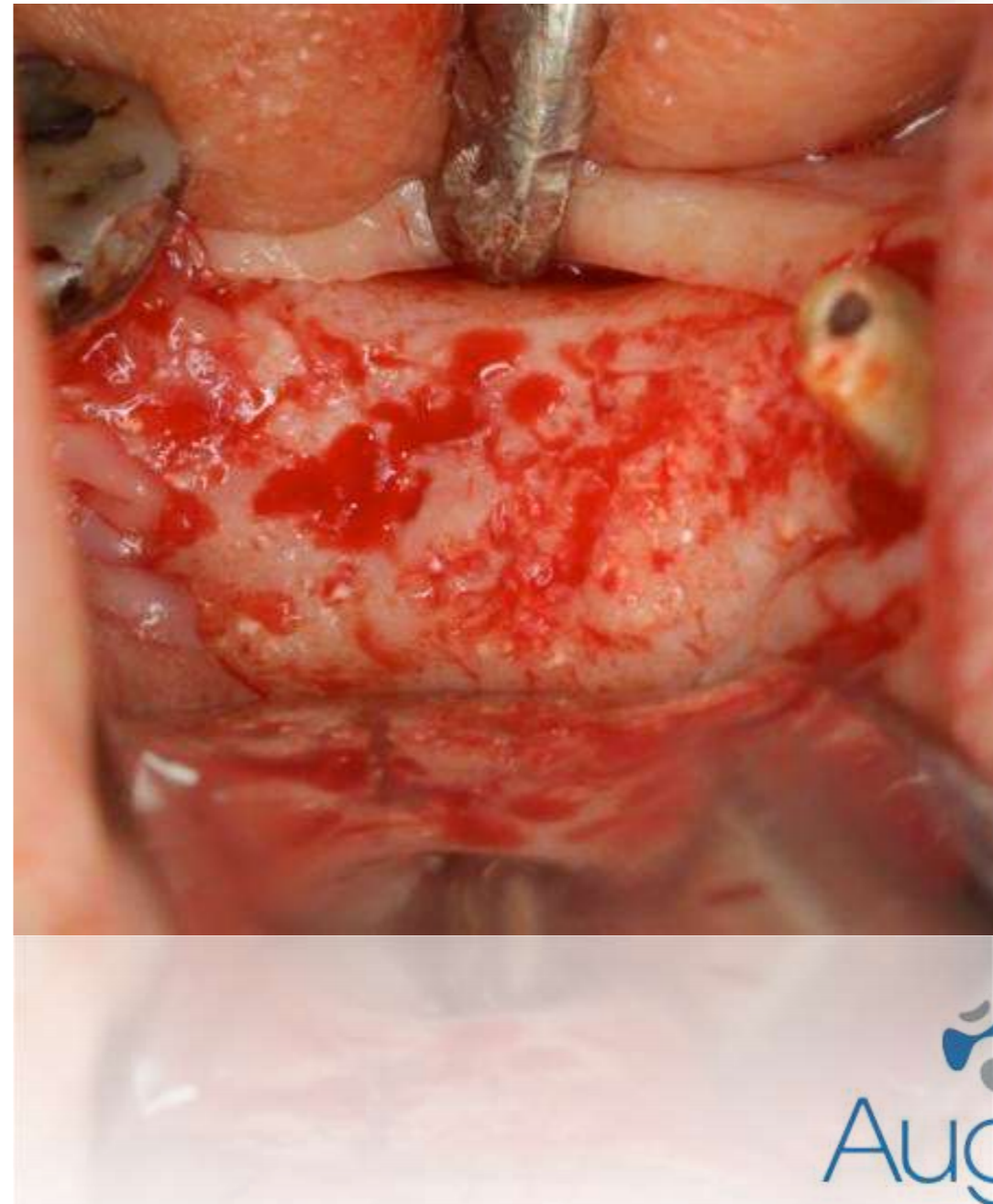

Before



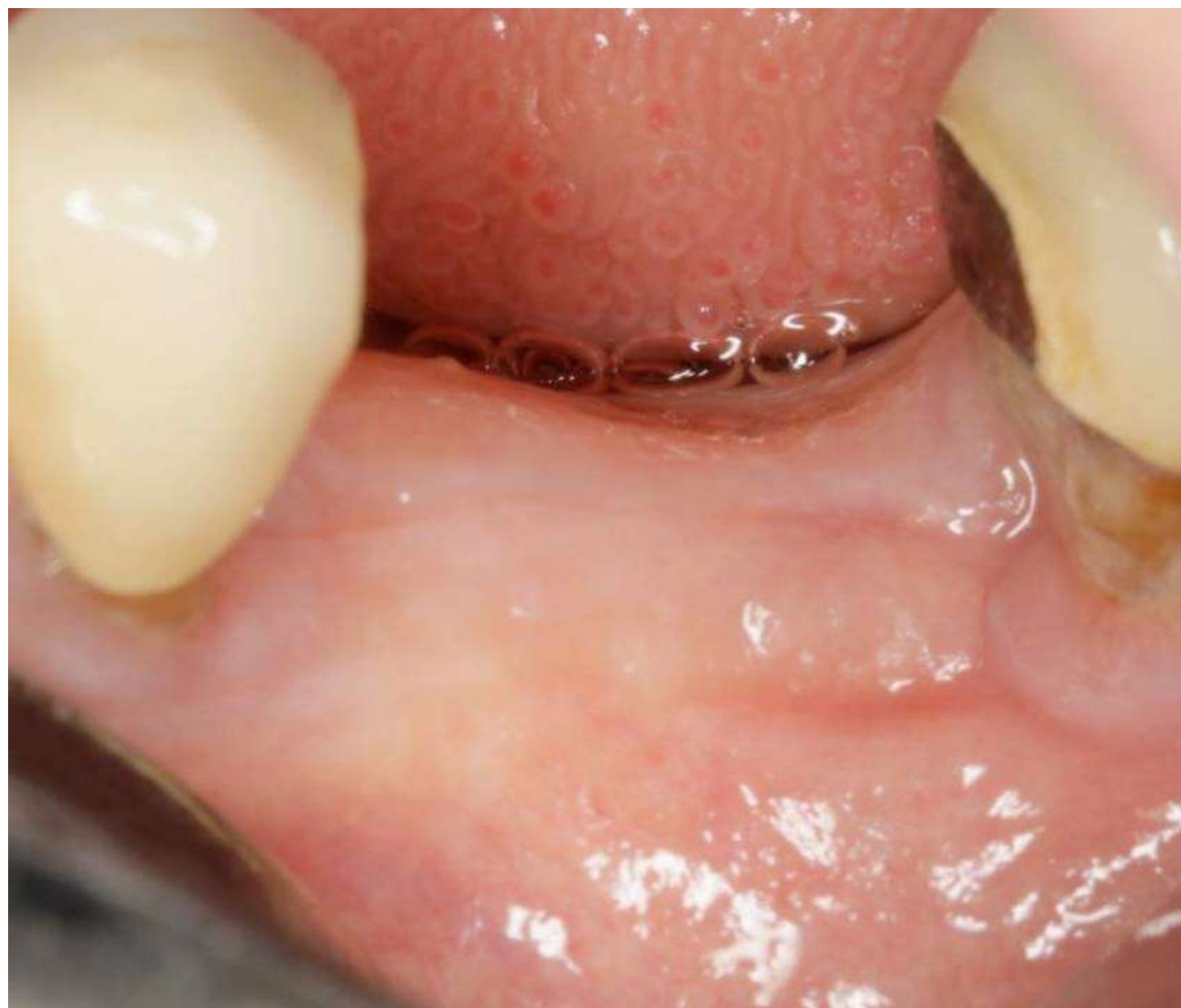**3DBond™**  
Graft Binder Cement

Reenter after 3 months

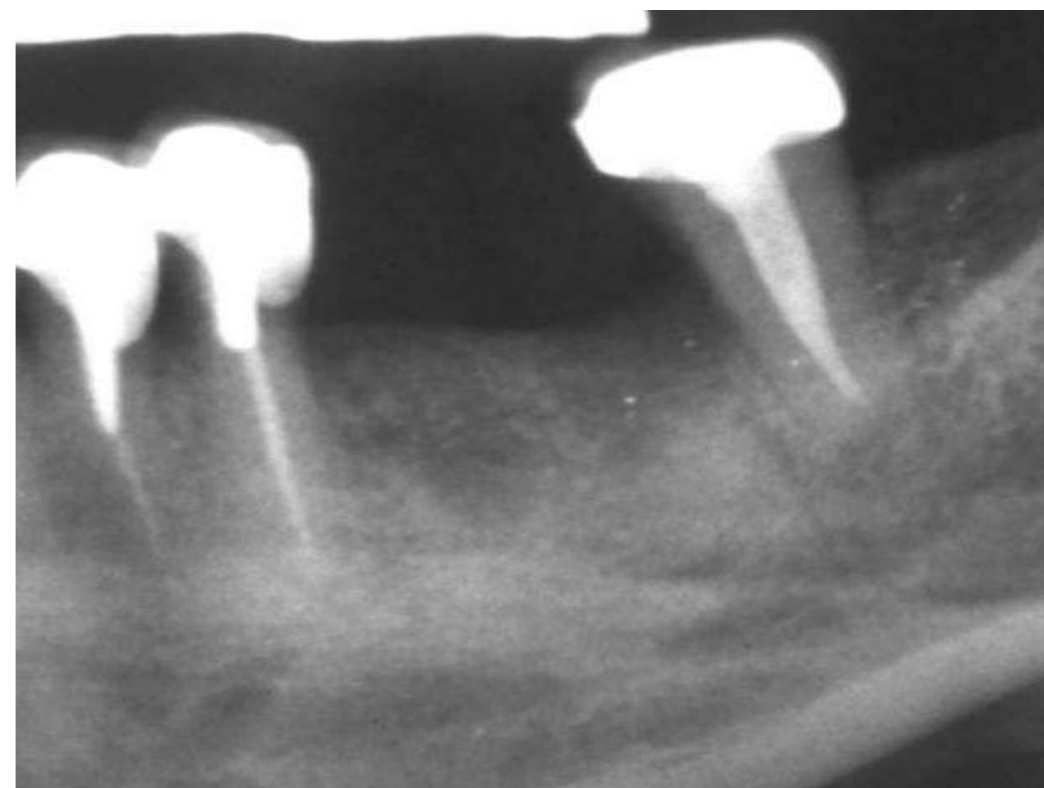

  
**Augma**  
BIOMATERIALS

After 3 months



Radiography



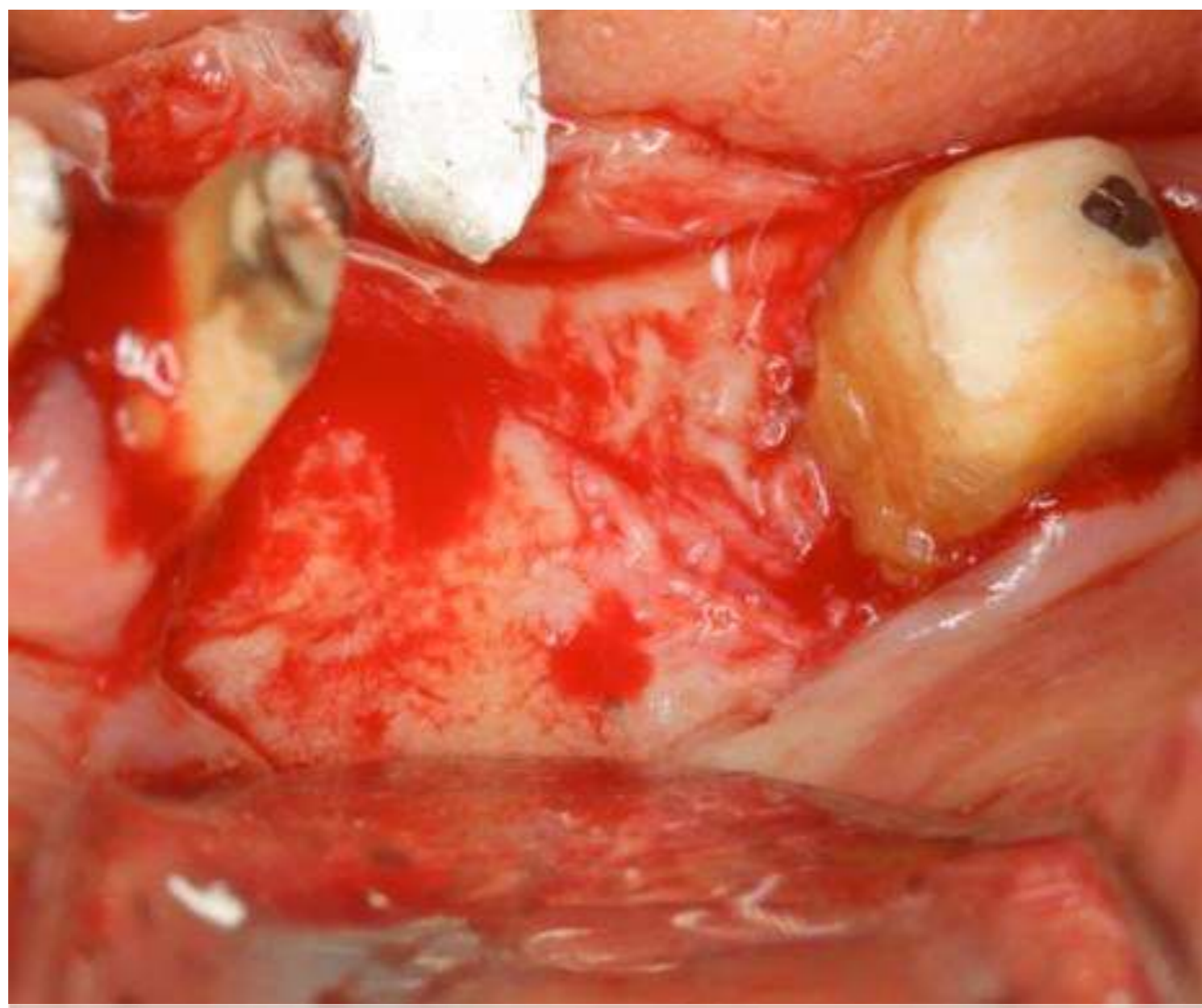
3DBond™  
Graft Binder Cement

  
Augma  
BIOMATERIALS

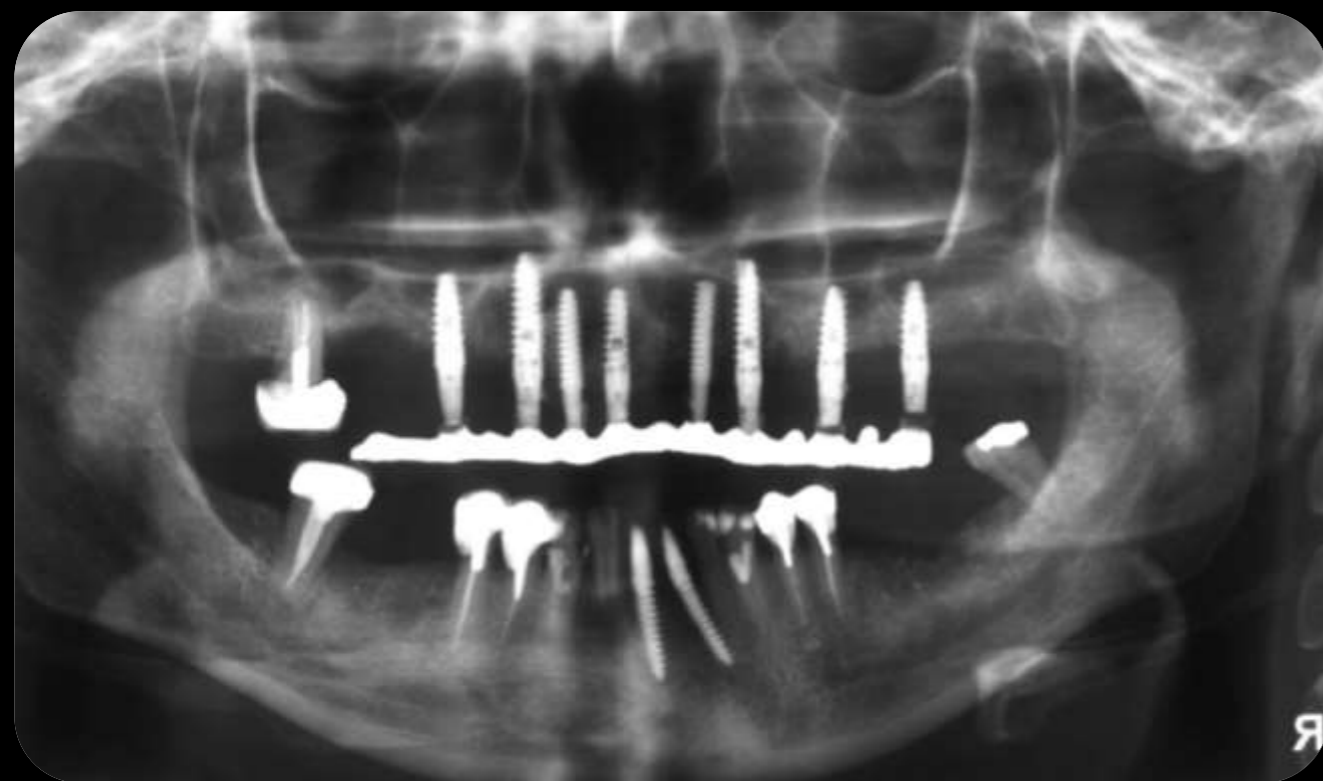
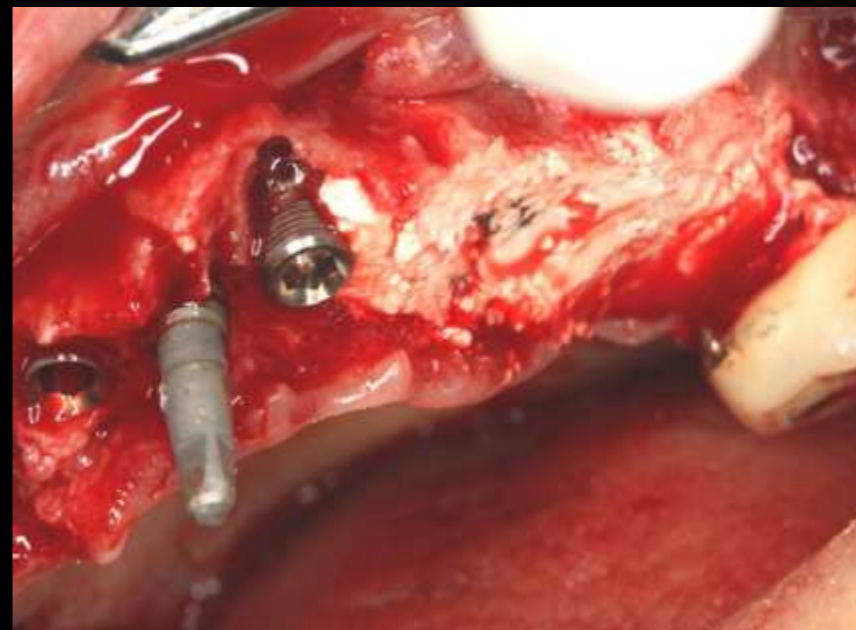
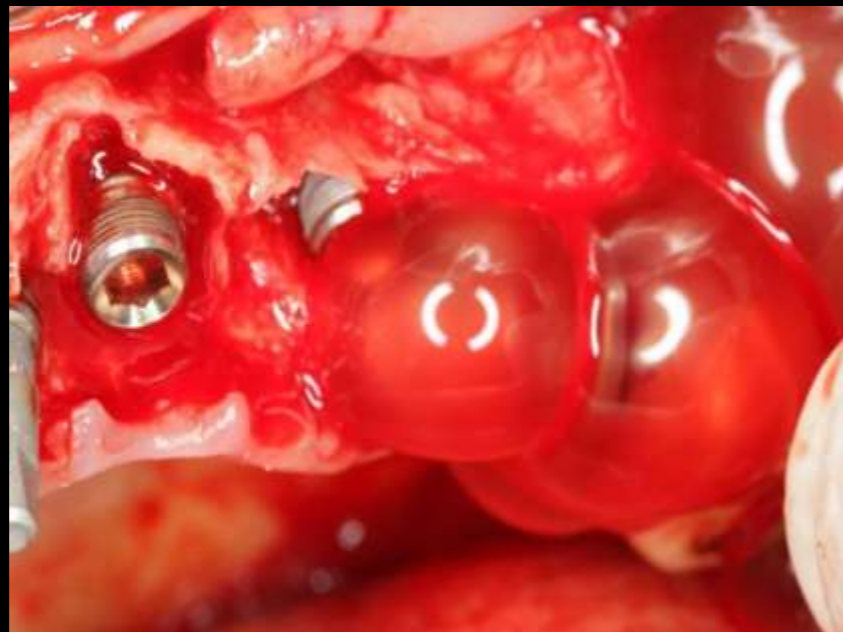




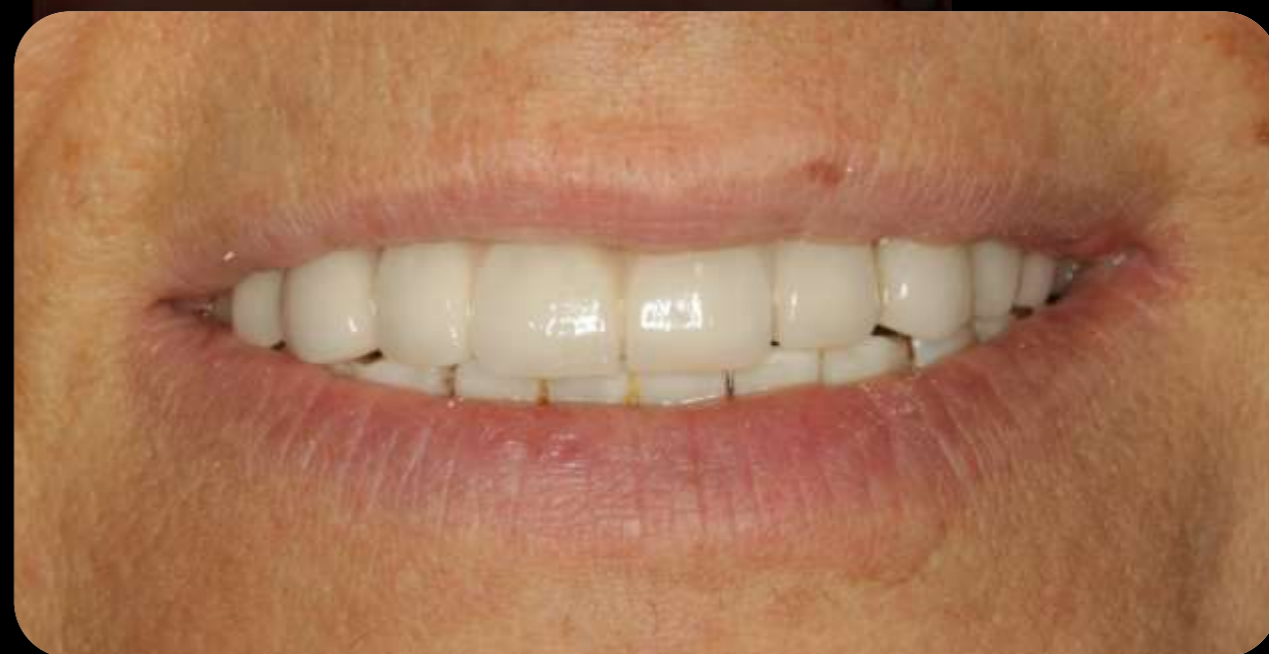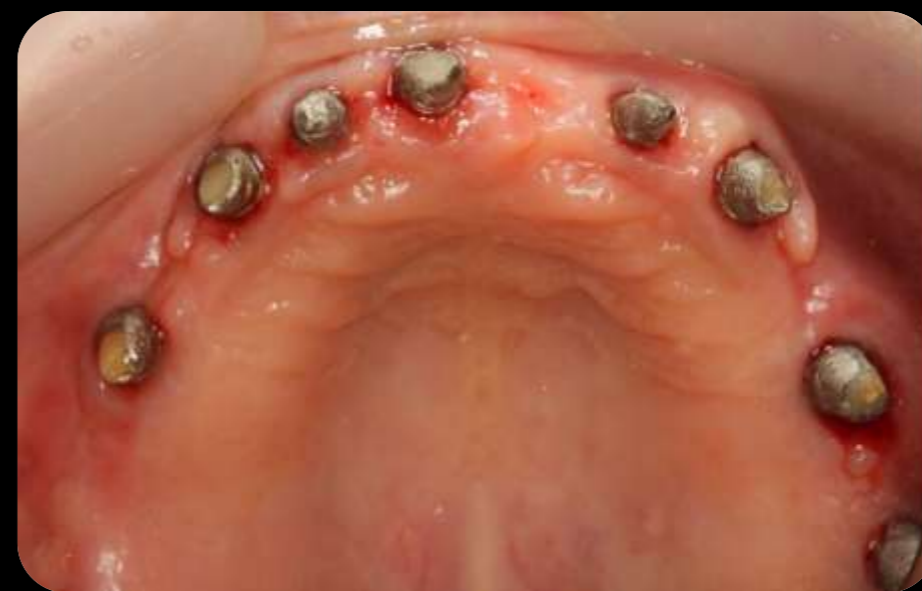## Reenter after 3 months



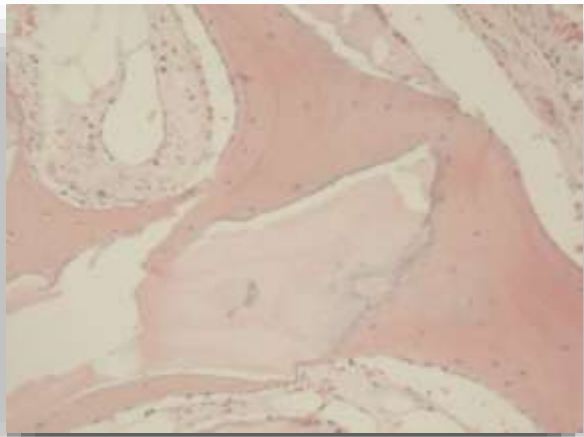
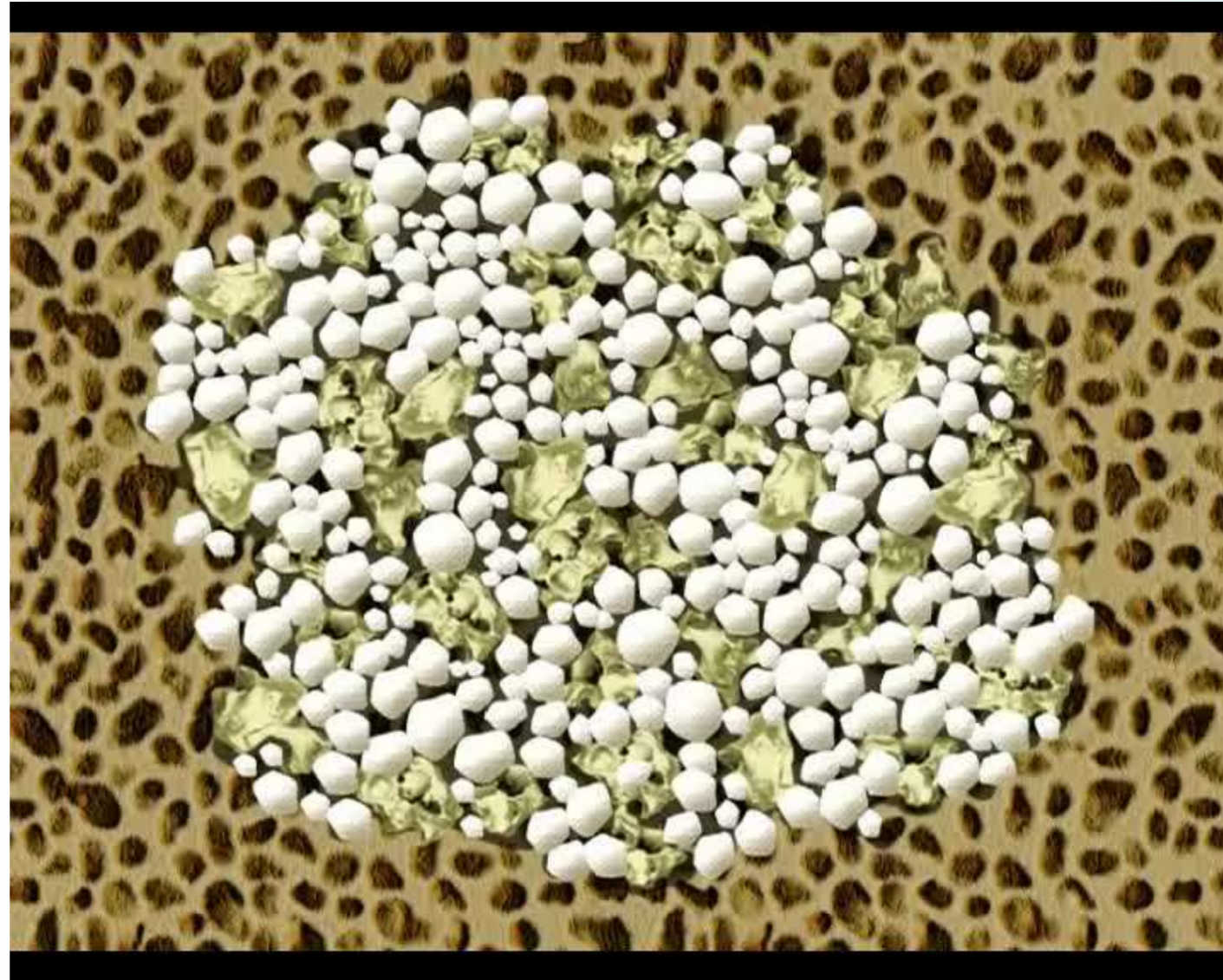
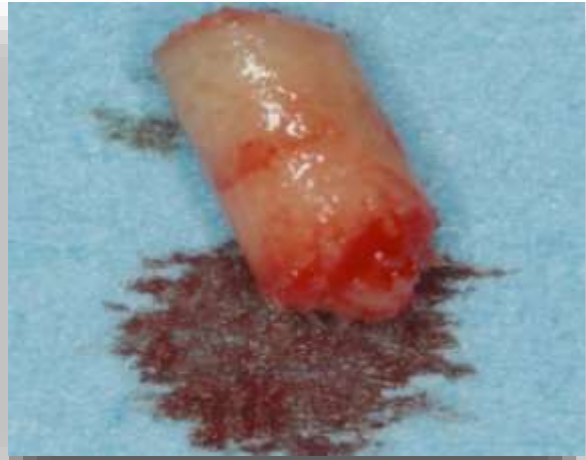



3 months post op



# Bone Formation When a Composite Graft is Used




# Composite Graft : magnification 40



# Composite Graft : magnification




100




400

# Composite Graft : magnification 2000 and 4000

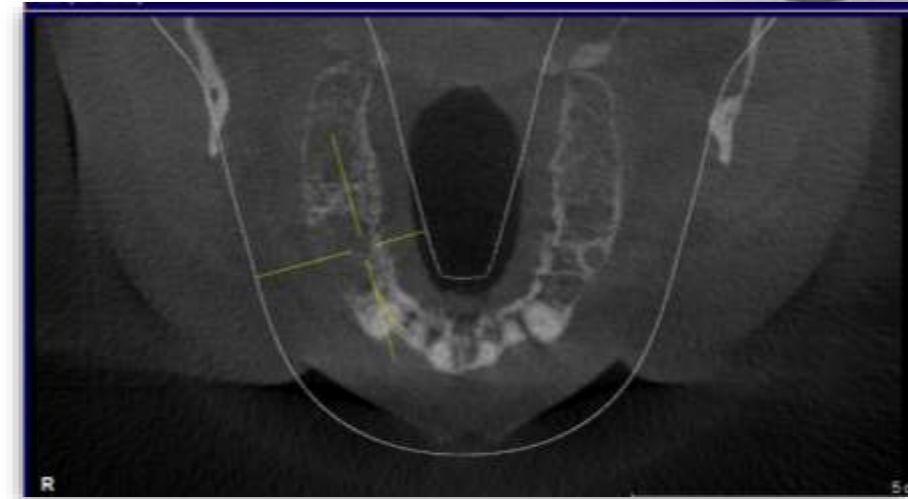
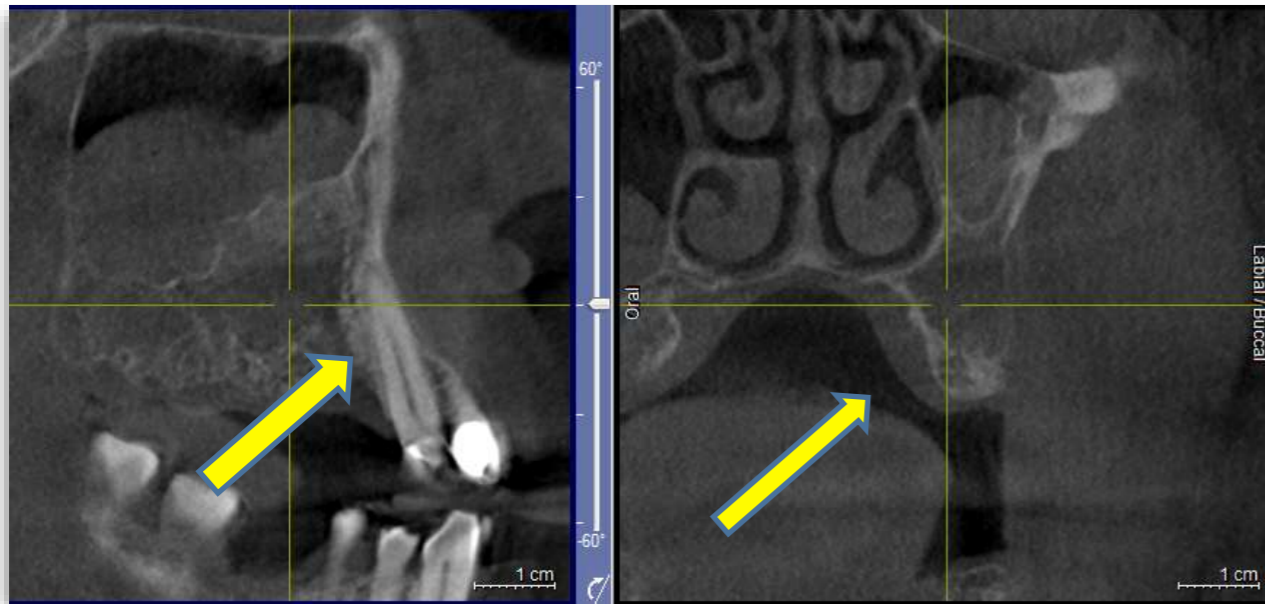


2000

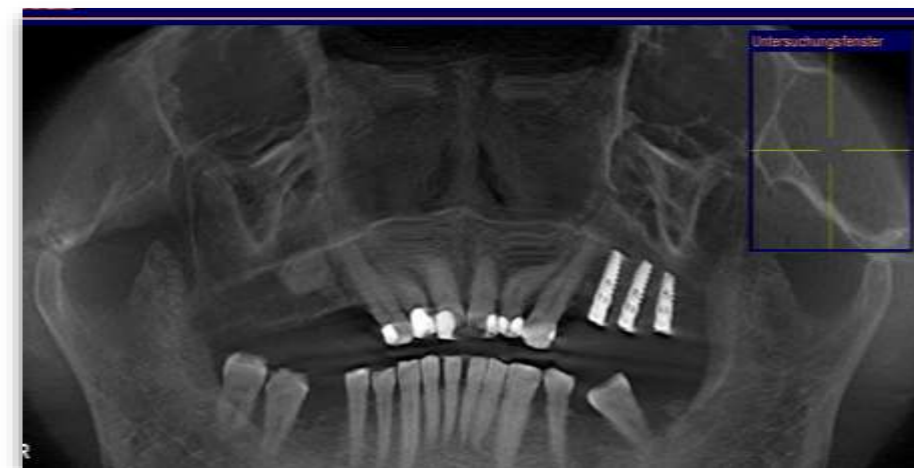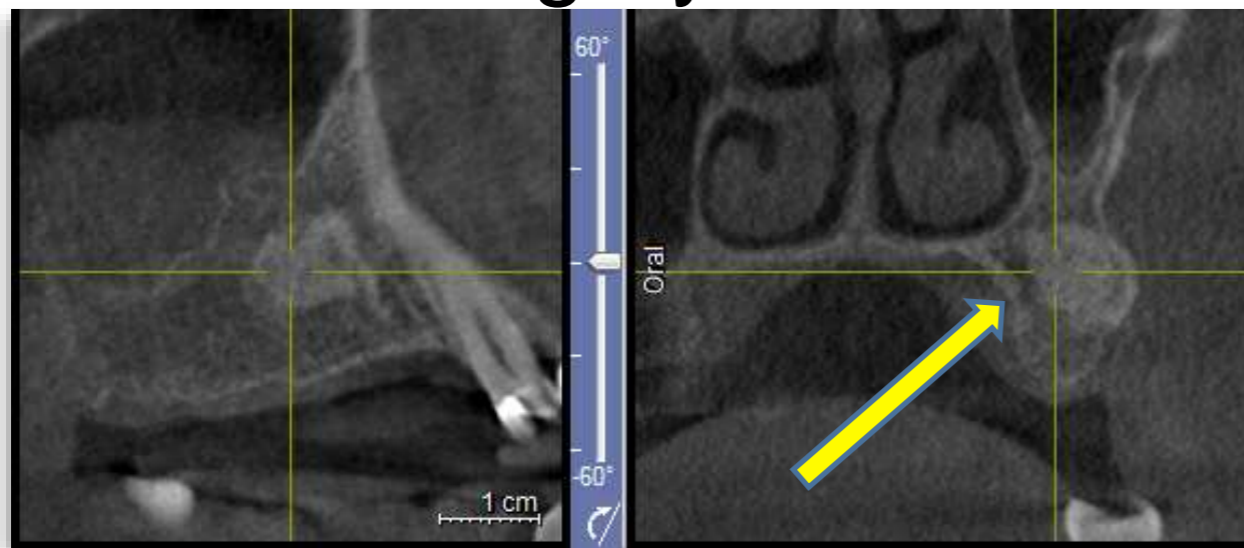


4000

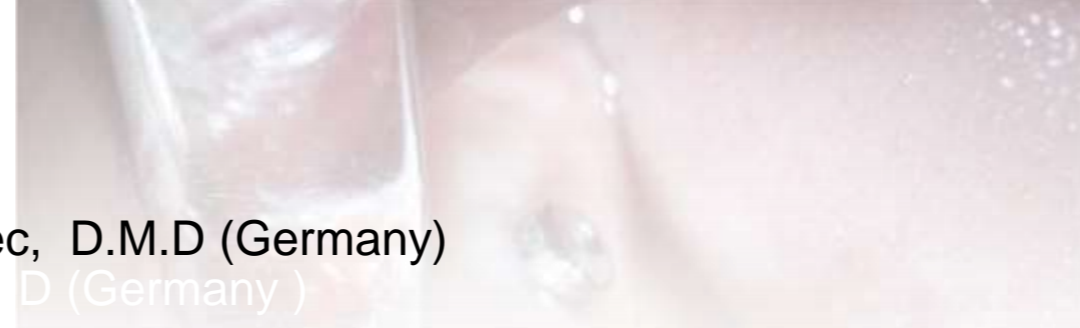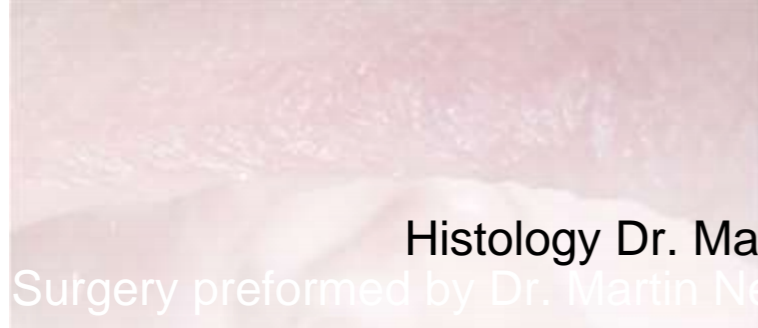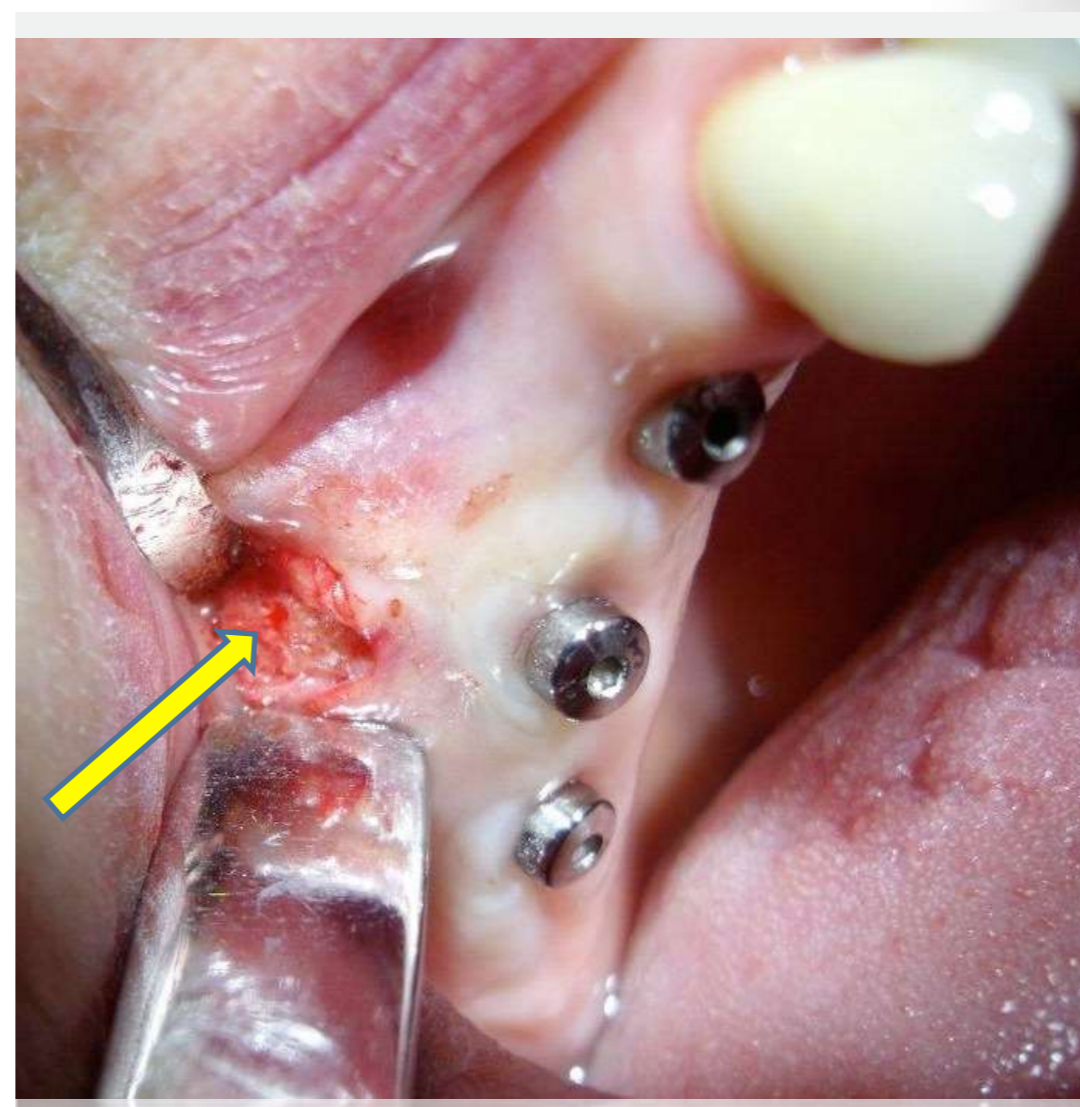

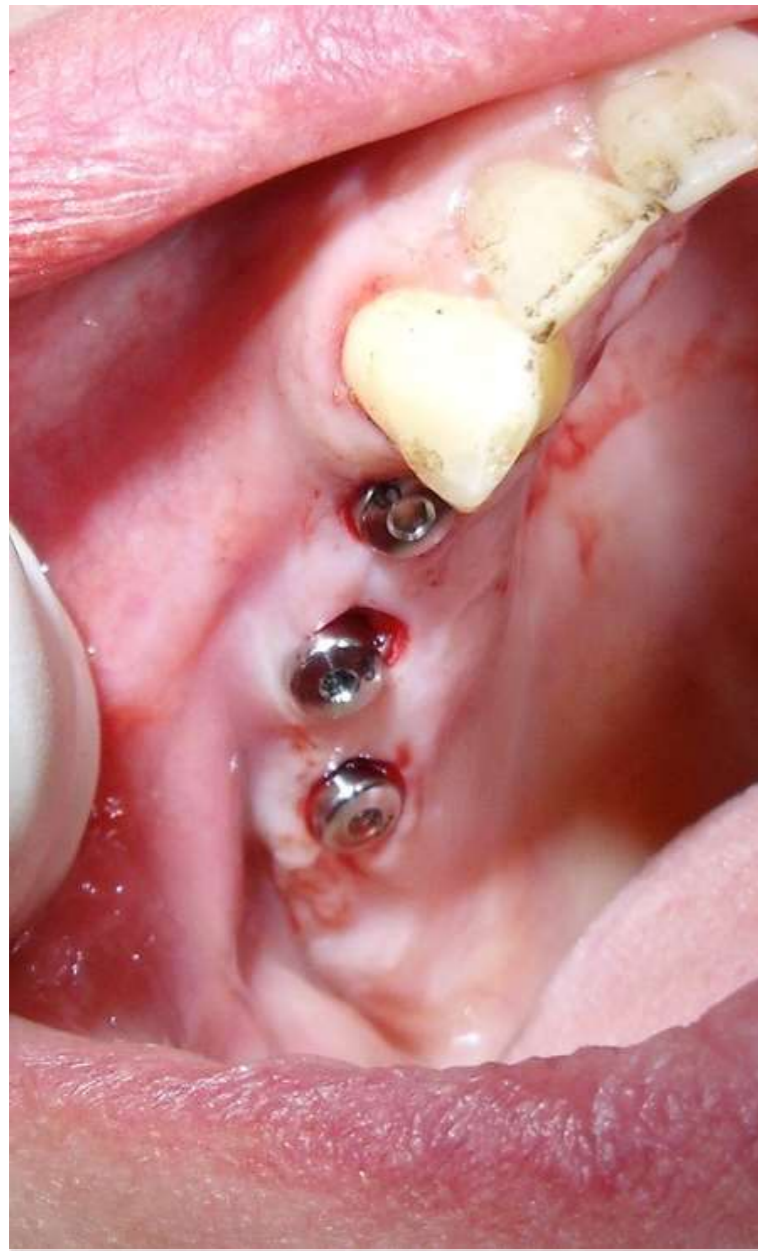# Bone cyst augmentation Using 3D Bond™ with Bio-Oss®



## After surgery



# Core harvesting for histology evaluation and implant placement

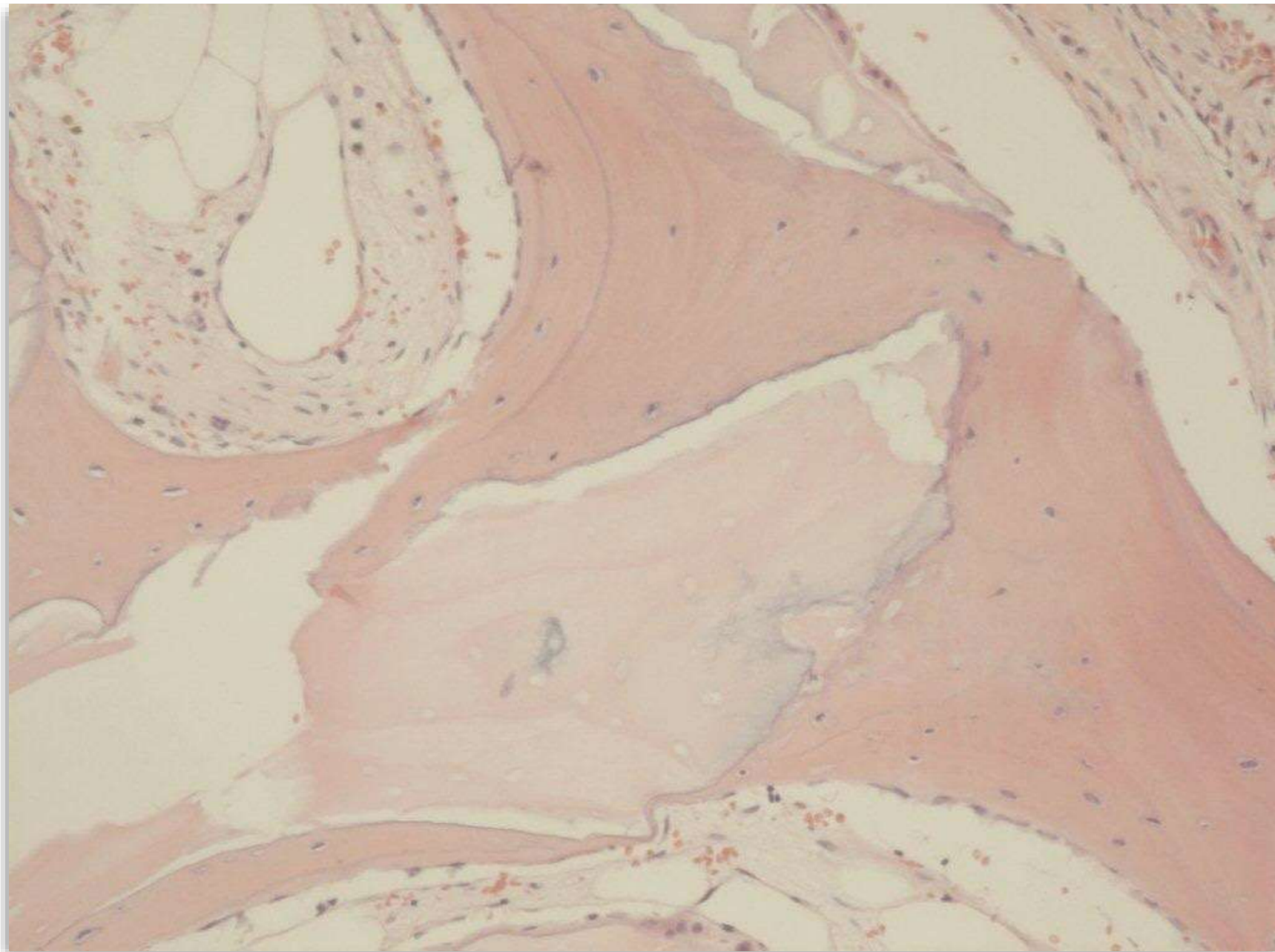


Histology Dr. Martin Nemeč, D.M.D (Germany)

Surgery performed by Dr. Martin Nemeč, D.M.D (Germany)

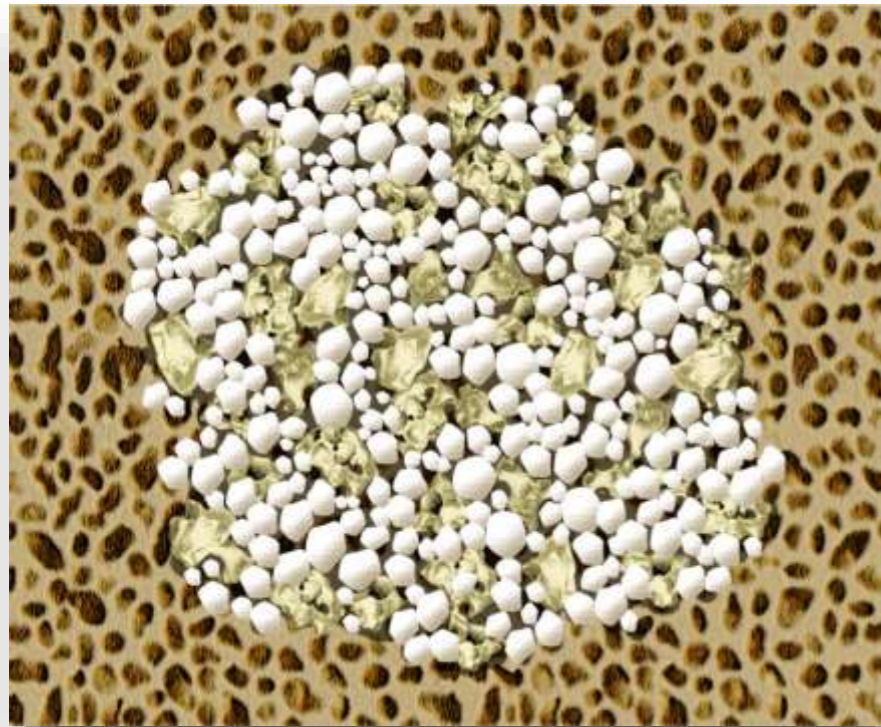
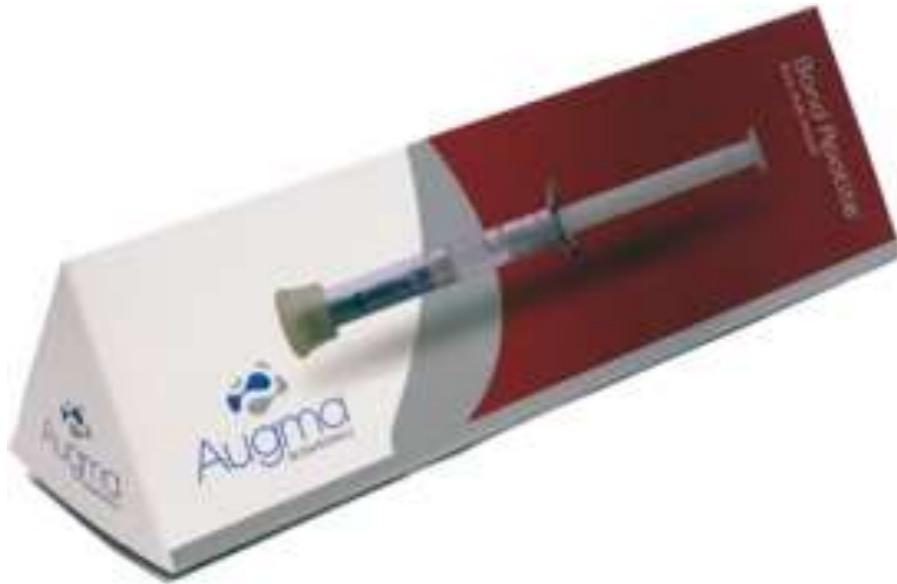


*Histology of composite graft using 3D Bond™ +  
Bio-Oss® one year post operation*



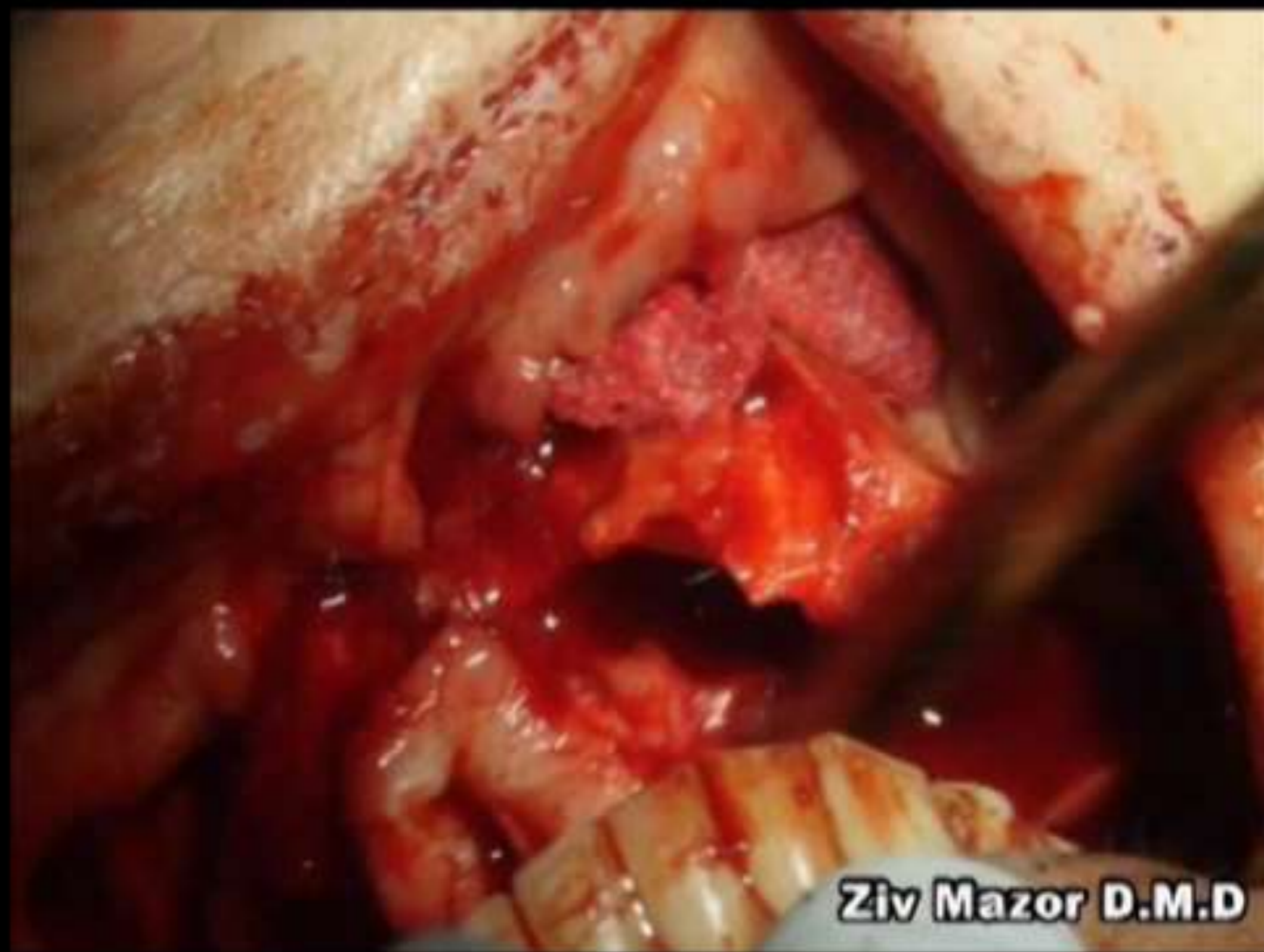
Histology Dr. Martin Nemec, D.M.D (Germany)

# Bond Apatite® Composite Graft




**Bond Apatite®**  
Bone Graft Cement


  
**Augma**  
BIOMATERIALS



**Ziv Mazor D.M.D**



HV	WD	Mag	Det	Sig	100.0 μm
15.0 kV	10.5 mm	1000x	SSD	BSE	
					CG 6



HV	WD	Mag	Det	Sig
15.0 kV	10.5 mm	4000x	ETD	SE

20.0µm  
CG 6

# Bond Apatite<sup>®</sup>

## 3 steps ahead

The fastest, easiest and most efficient bone graft that the market has ever seen.

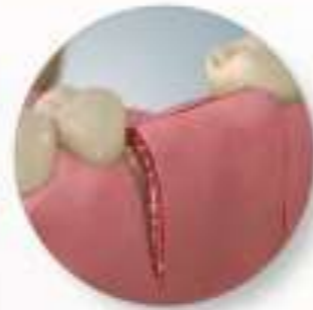From now on, graft placement and stabilization will take less than 1 minute! **Just...**



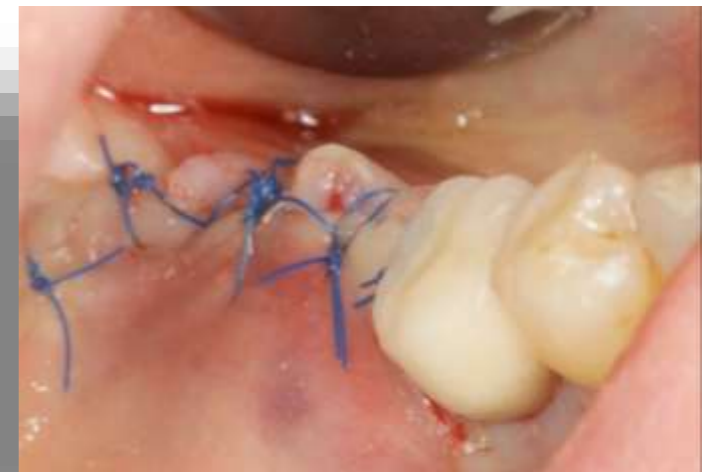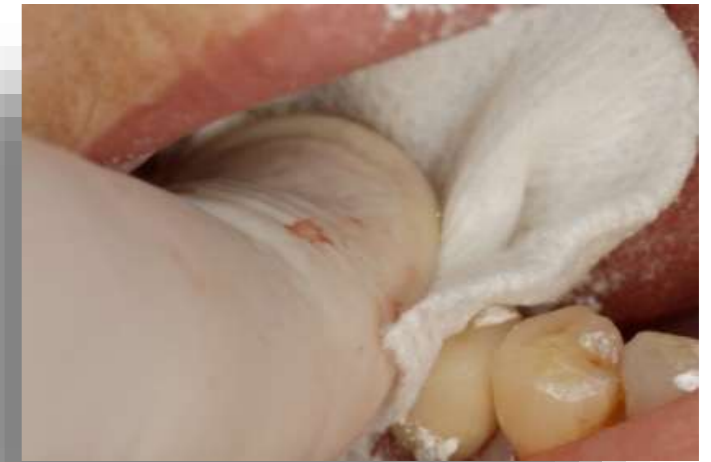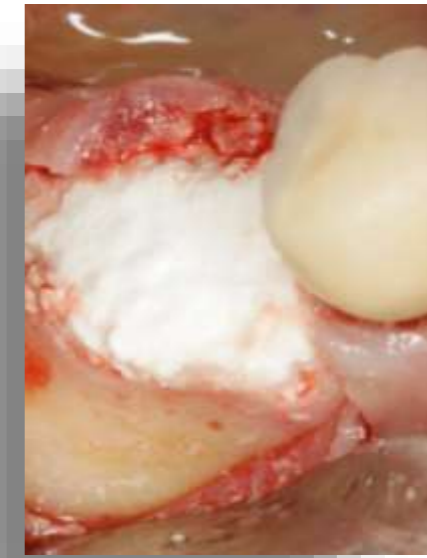Place

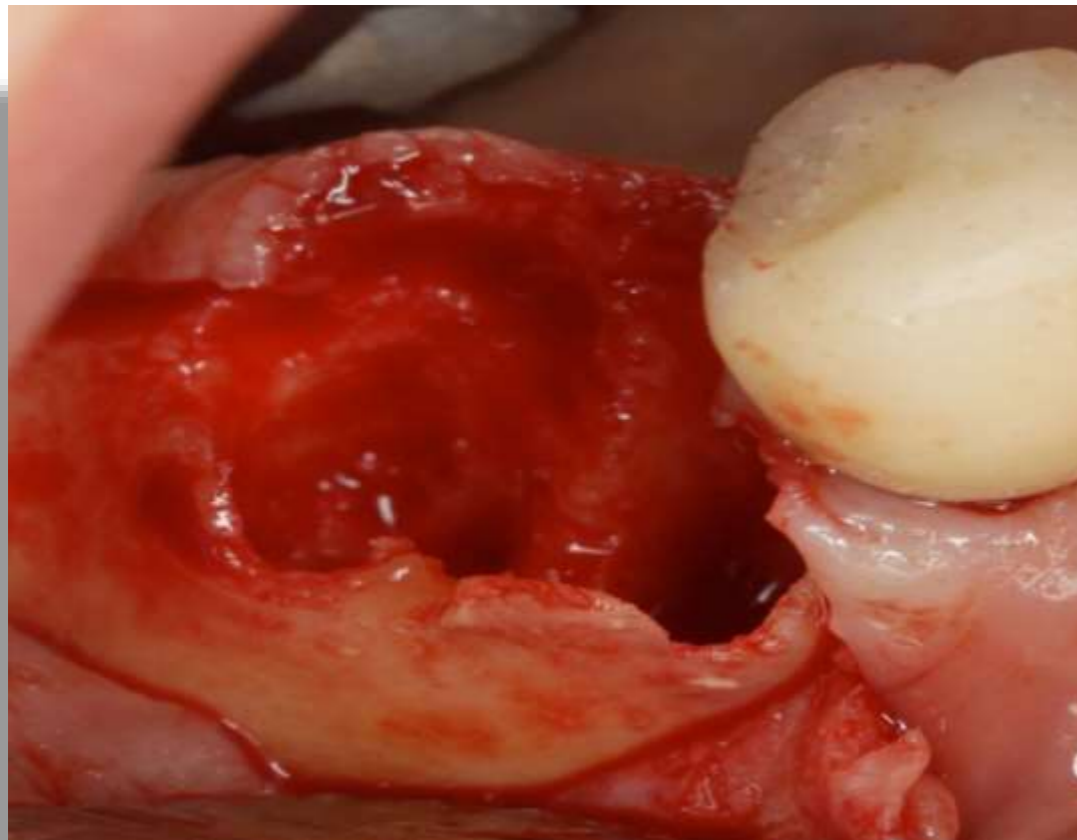



Press

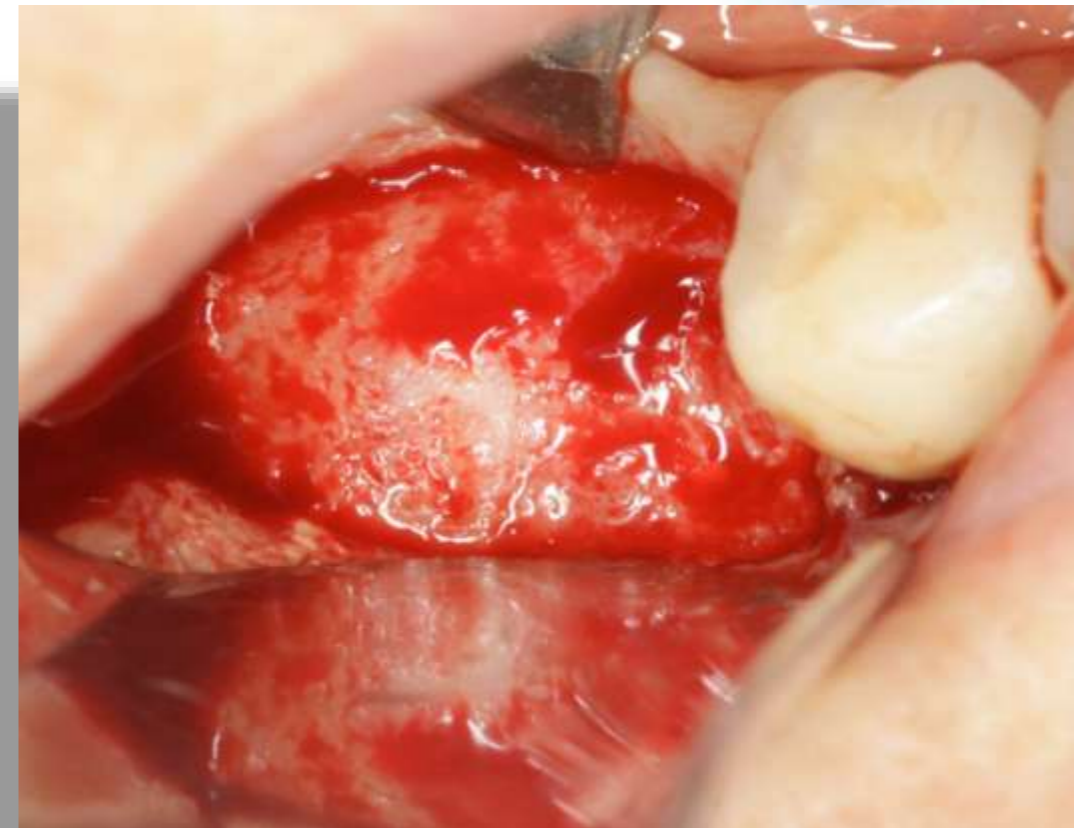

Close

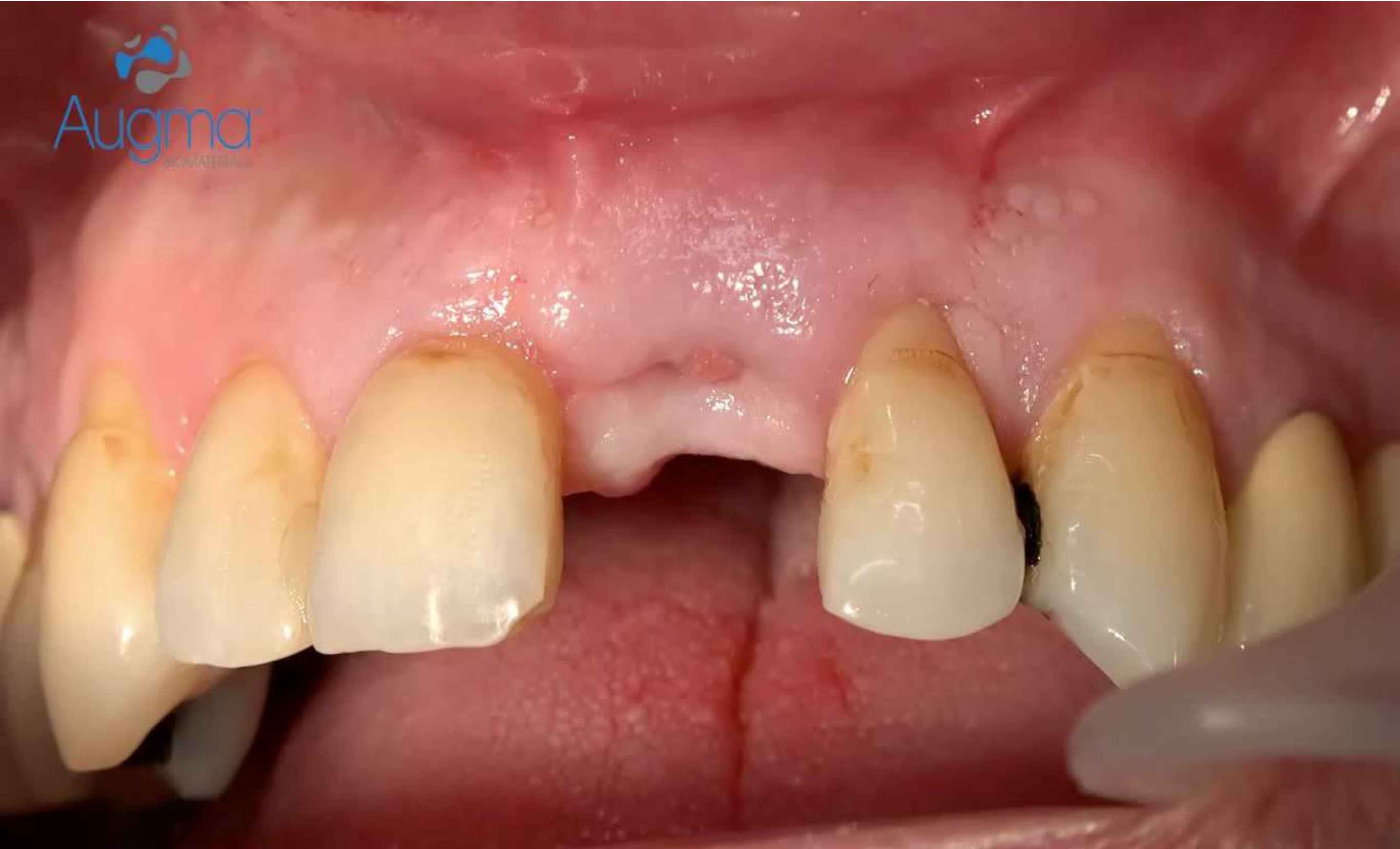



Before augmentation

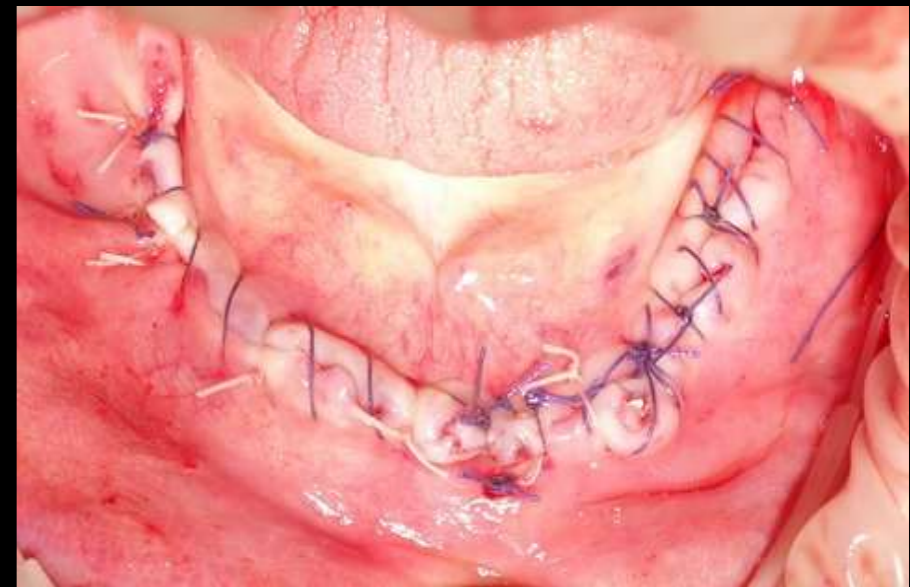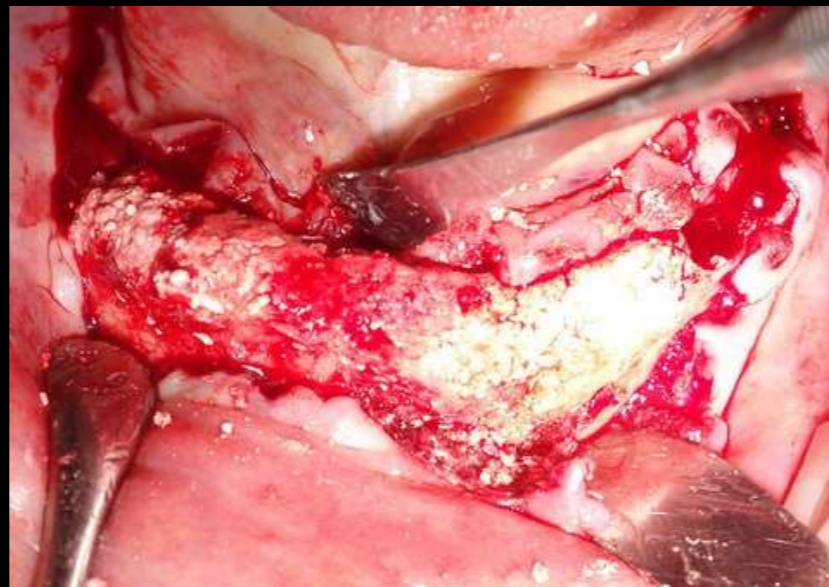

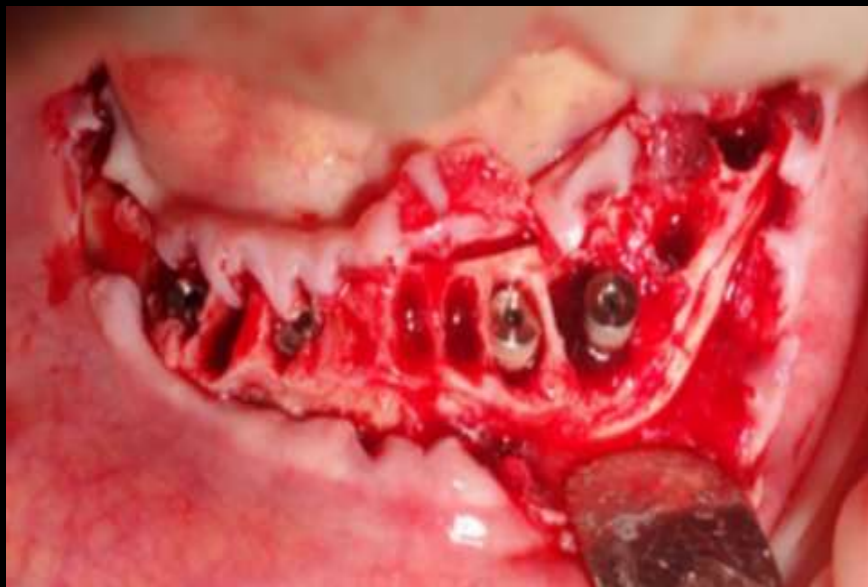
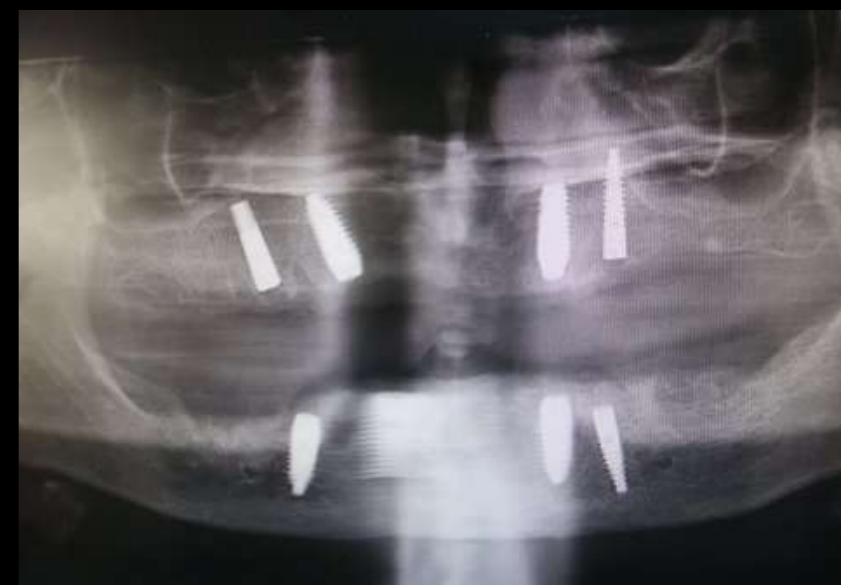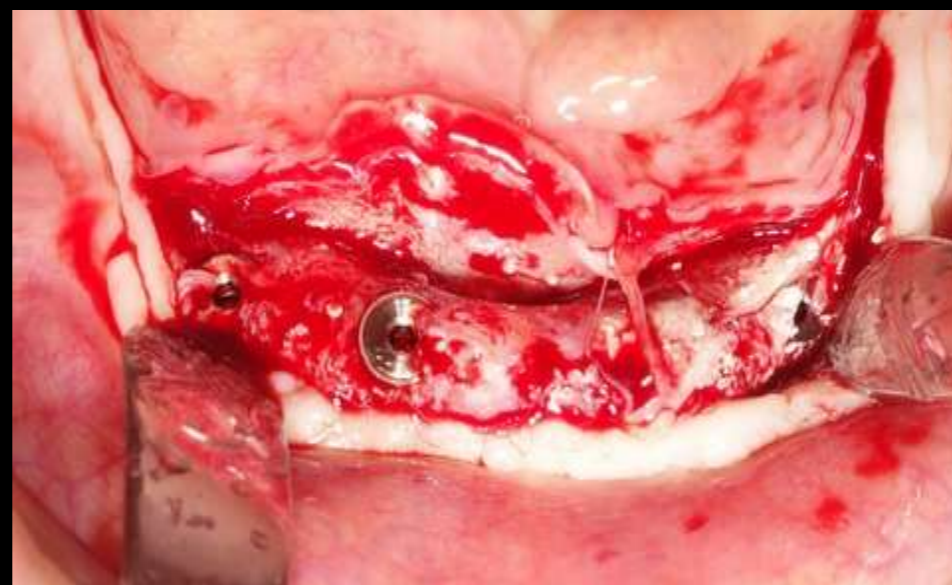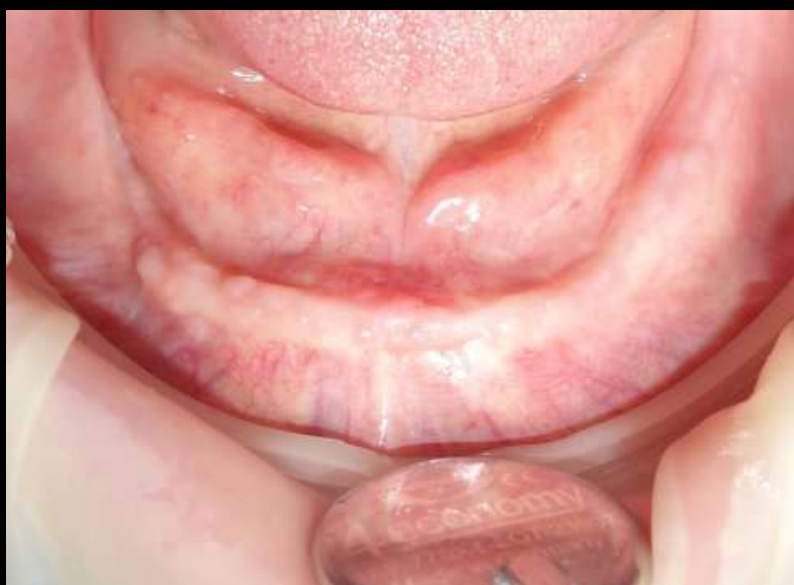12 weeks post op new bone formation can be seen





# Ridge Preservation

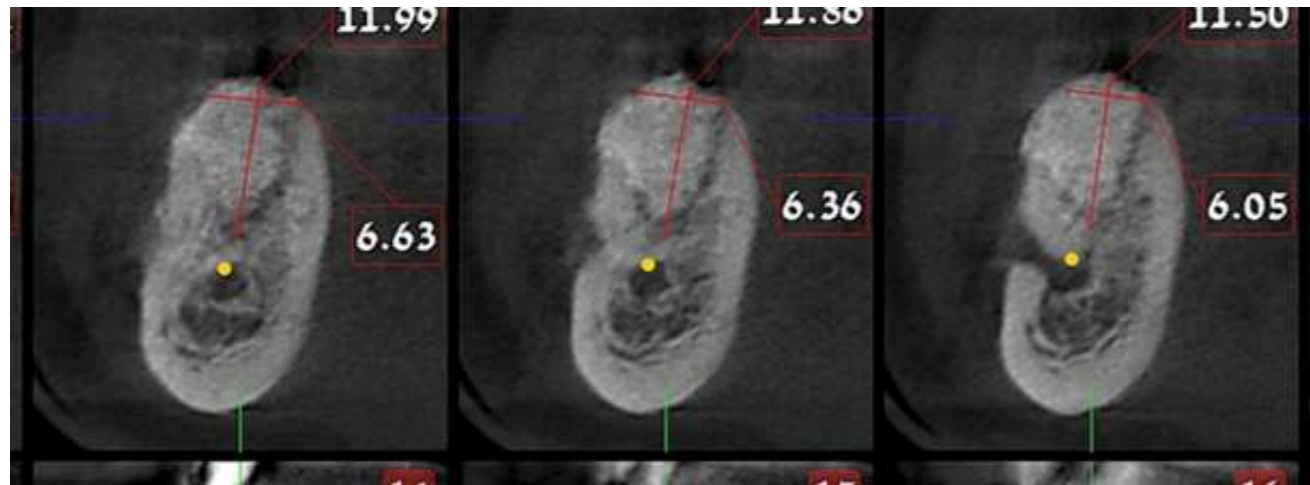




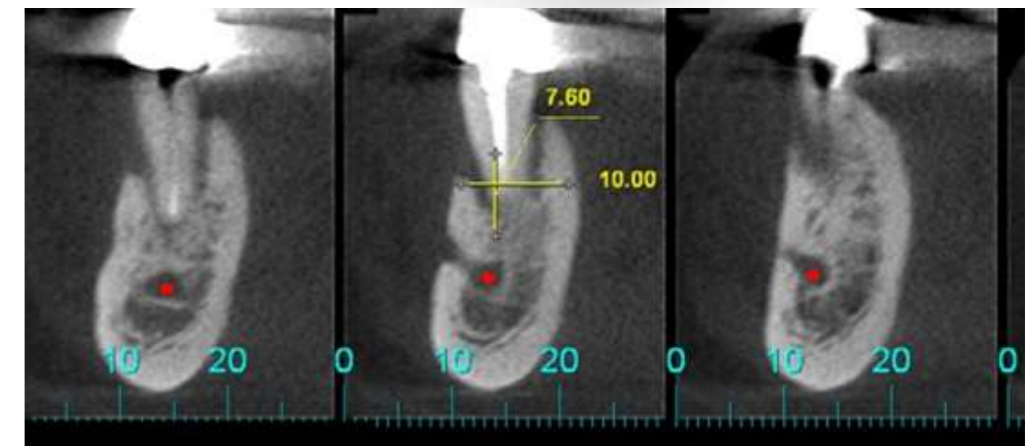
# Comparison of augmentation outcome when using HA from bovine origin alone (Bio-oss®) and Bond Apatite®



24 weeks post op. the quantity of vital bone formation is limited into the spaces in-between the HA granules (augmentation with Bio Oss®)

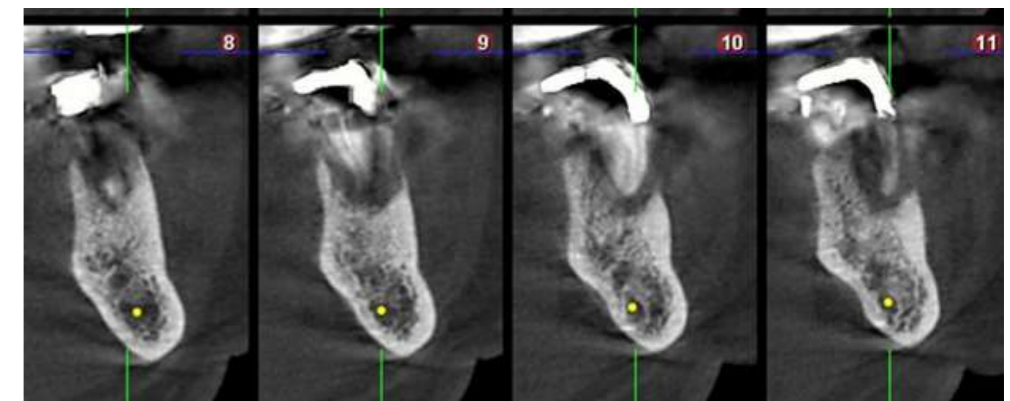
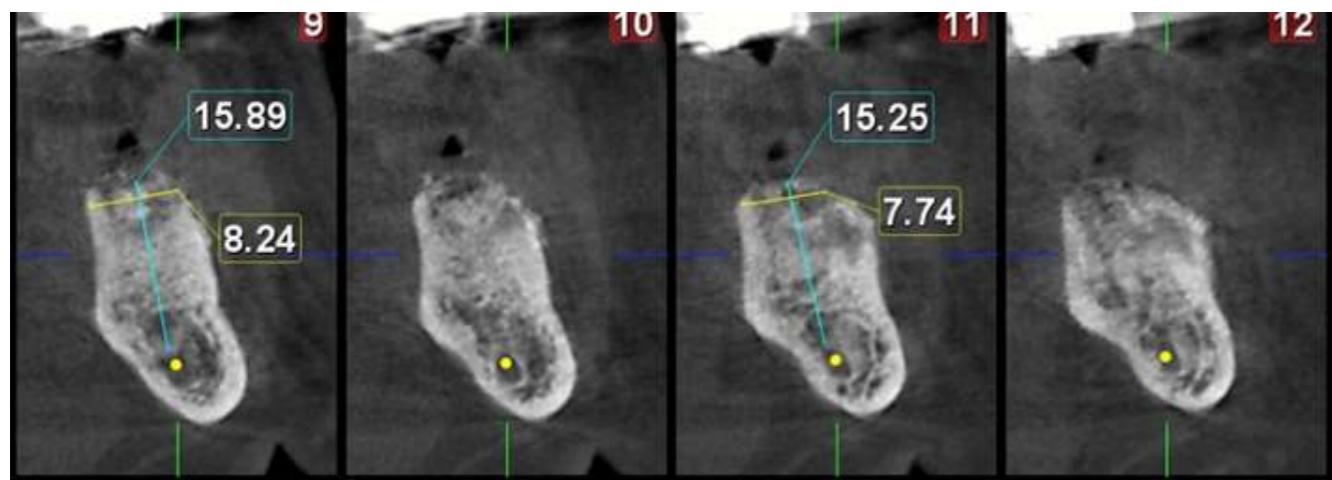



Before augmentation



Before augmentation

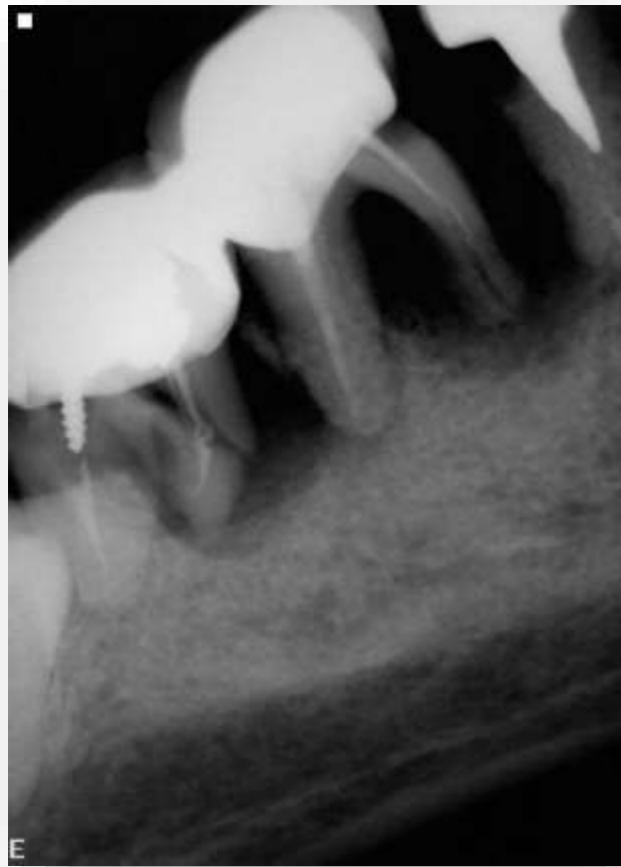12 weeks post op, new bone formation completely replace the Biphasic calcium sulfate matrix, while the HA granules are incorporated Within the new bone matrix .(Augmentation with Bond Apatite®)



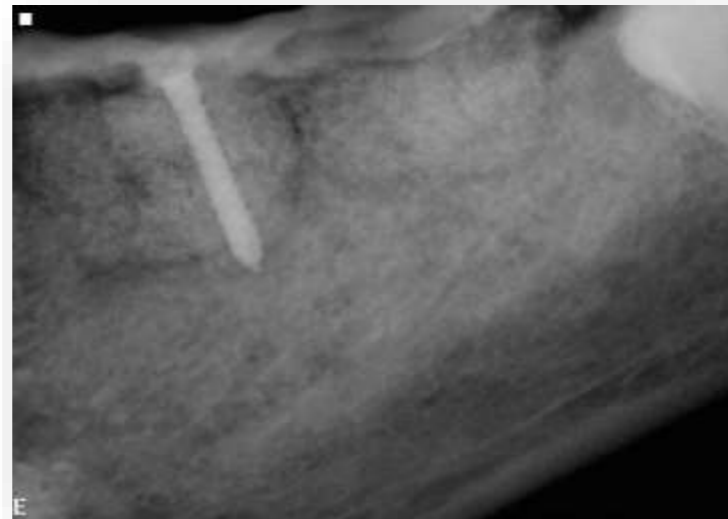


4 weeks post op

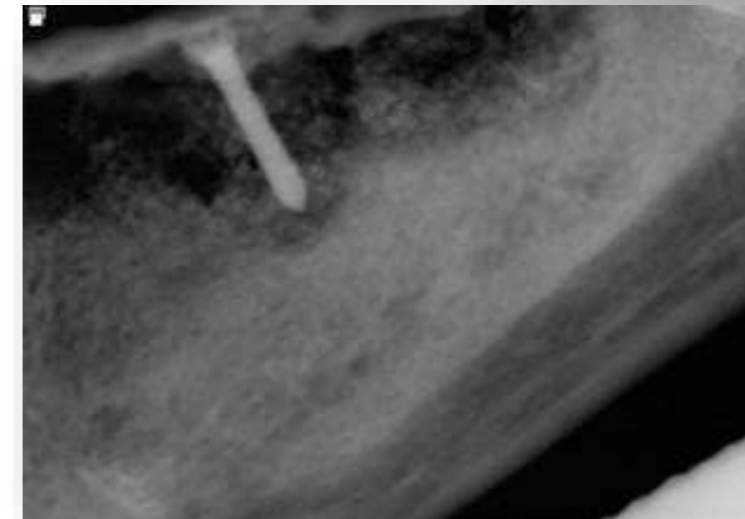
Bond apatite® in place on day 1.  
A protective external composite shield  
Is used supported by tenting screws



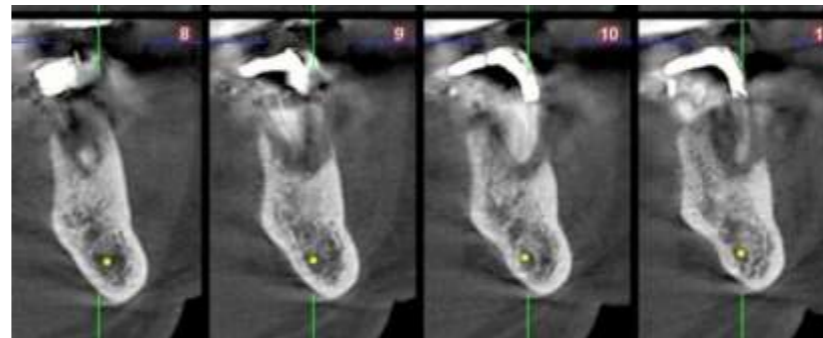
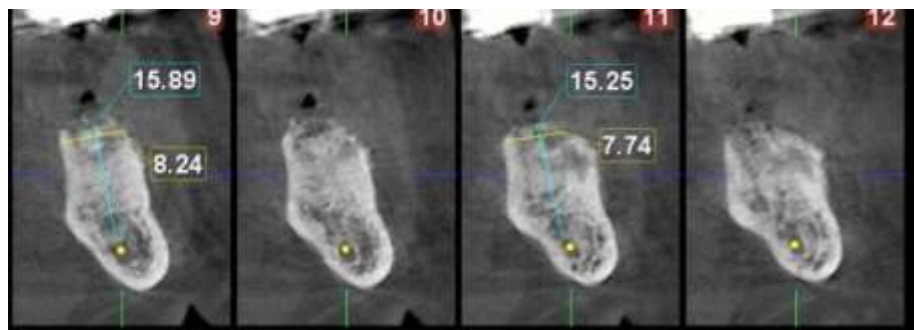

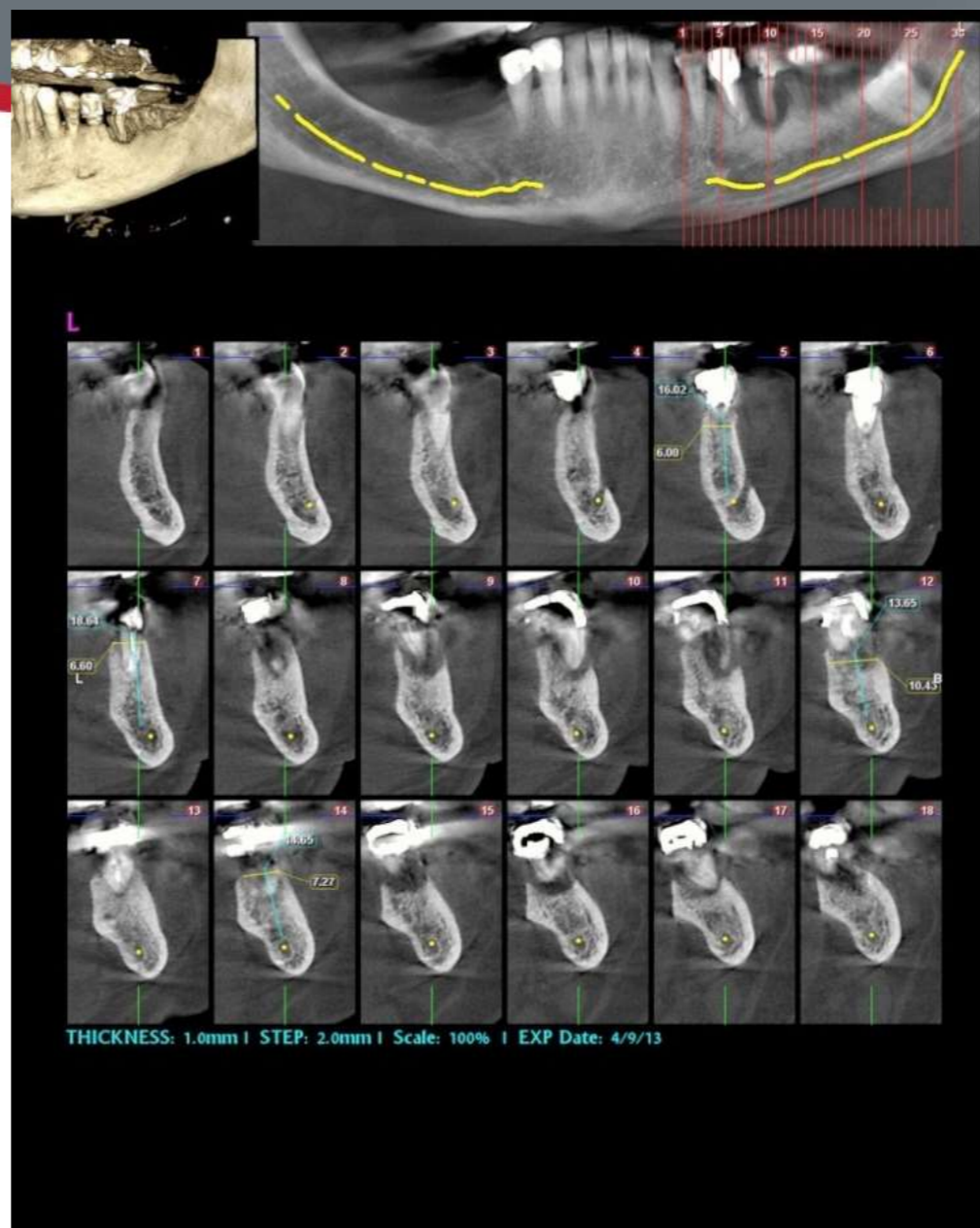
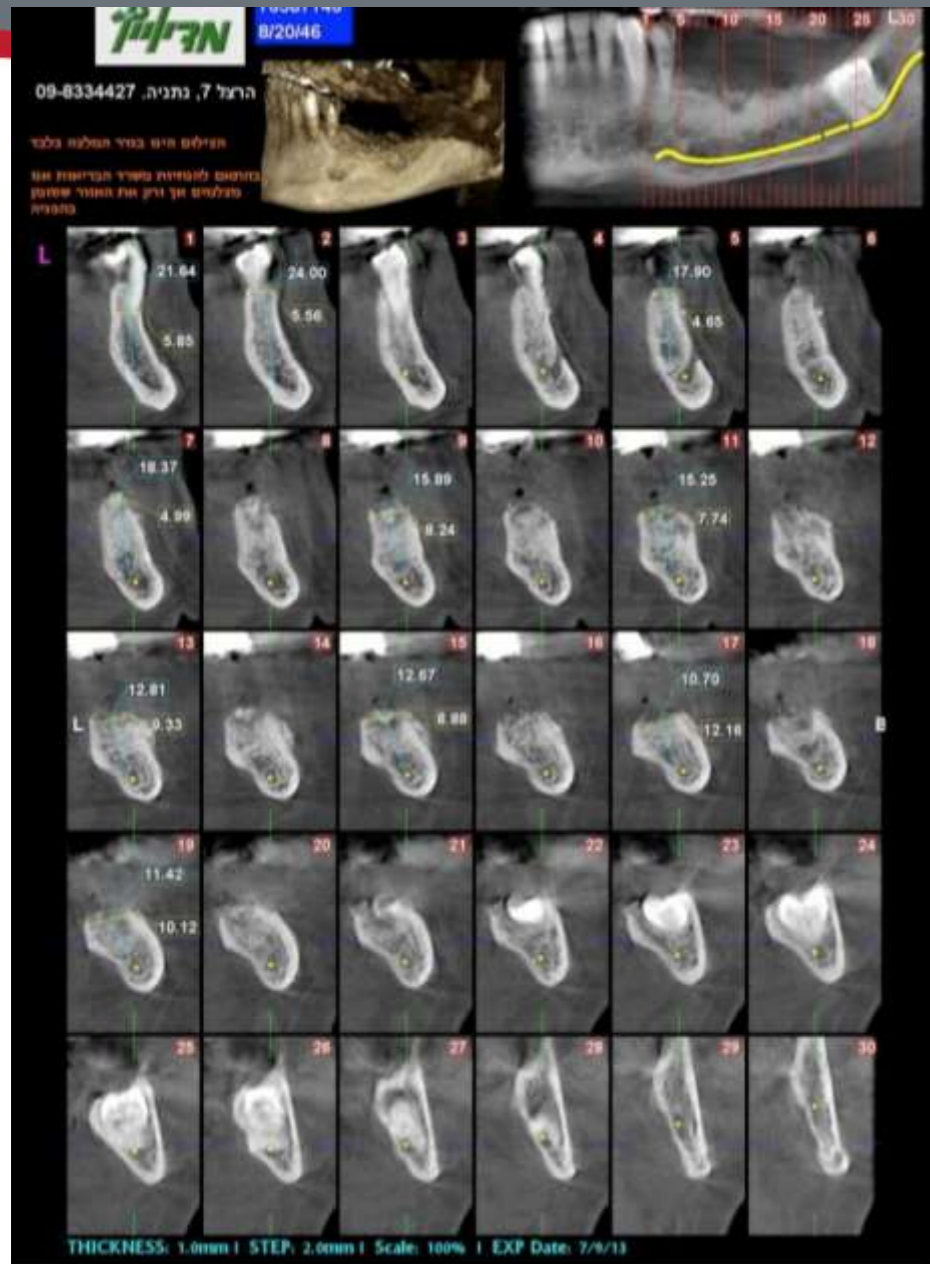
Pre op radiography



6 weeks post op , the external protective  
Shield has been removed



14 weeks post op re calcification and gradual  
maturation of the new formed bone

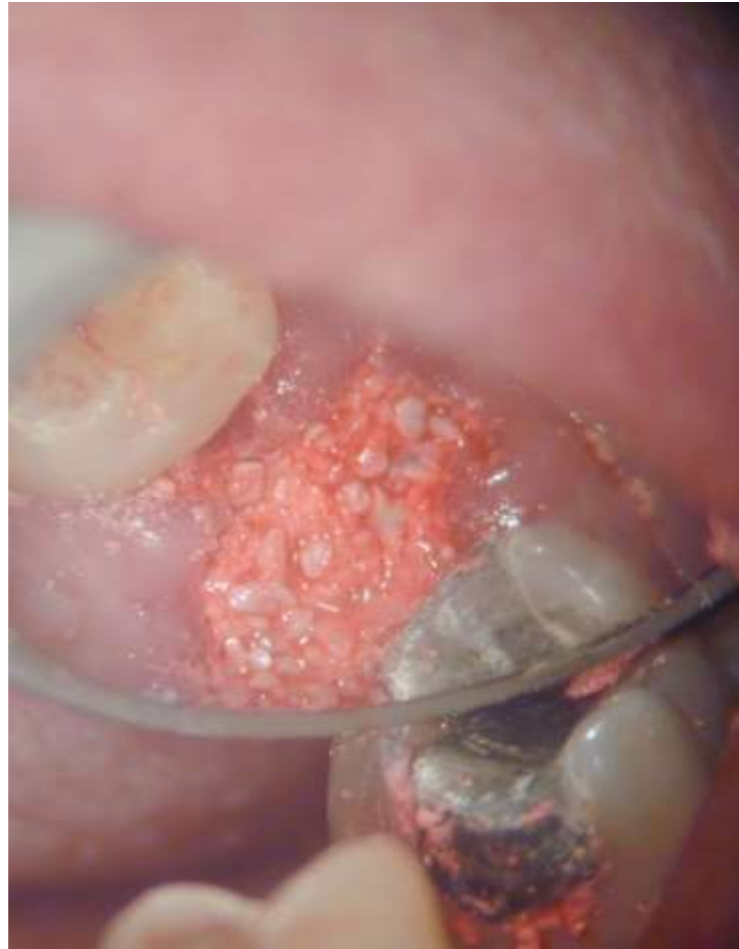
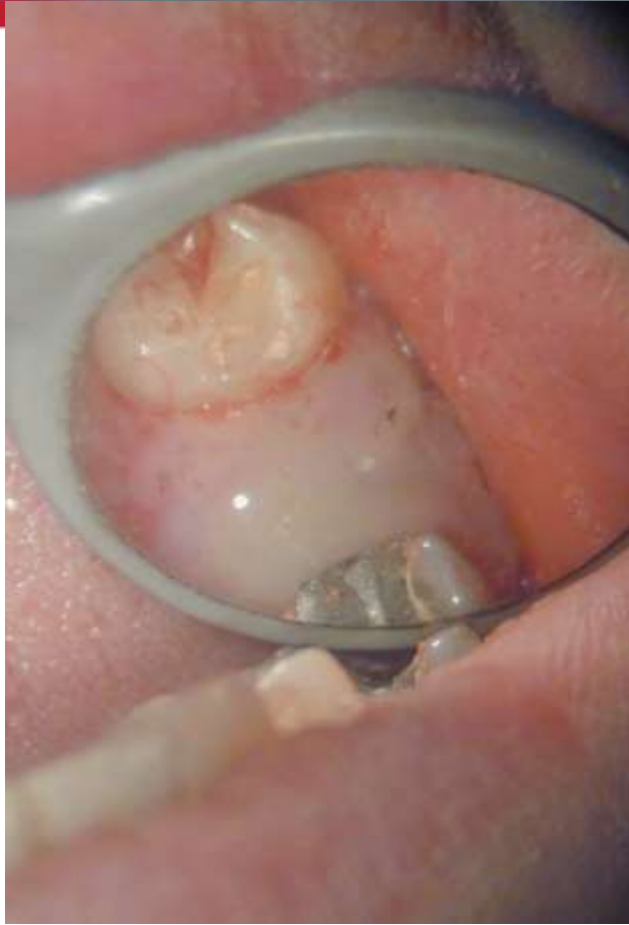
**Bond Apatite®**  
 Bone Graft Cement

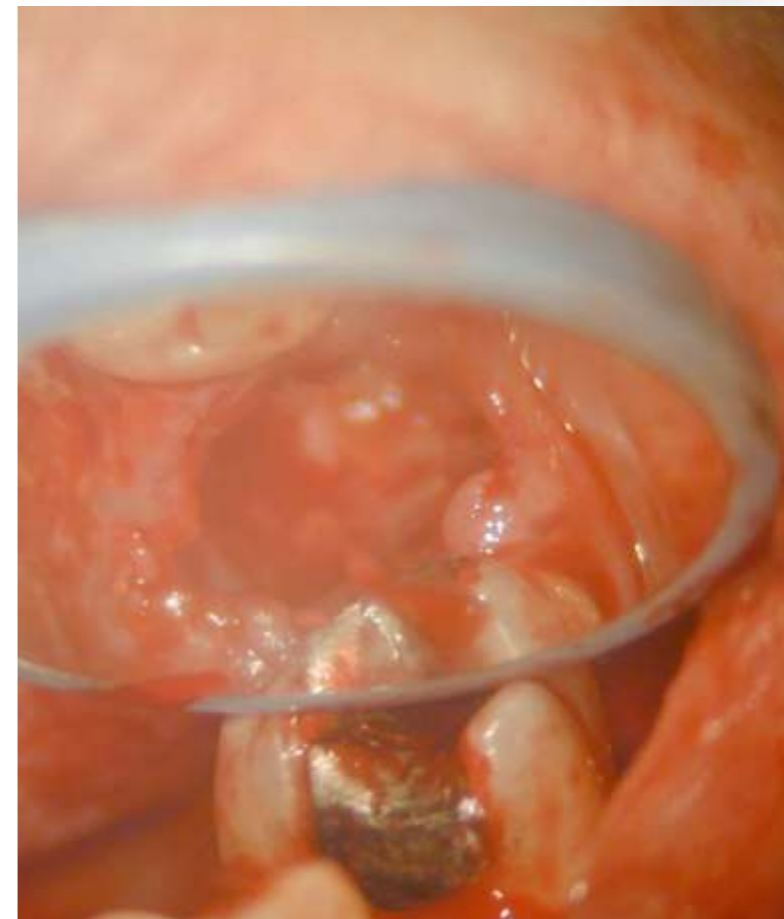Surgery Dr. Albert Saidov Hacoen, Netania, Israel

**Augma**  
 BIOMATERIALS

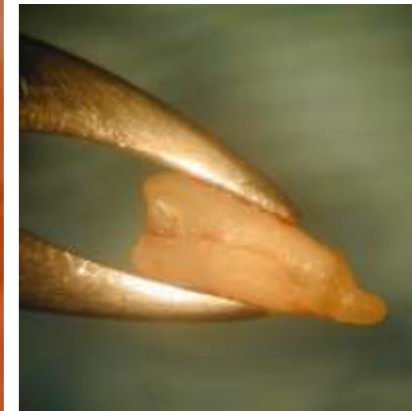# Augmentation using Bond Apatite



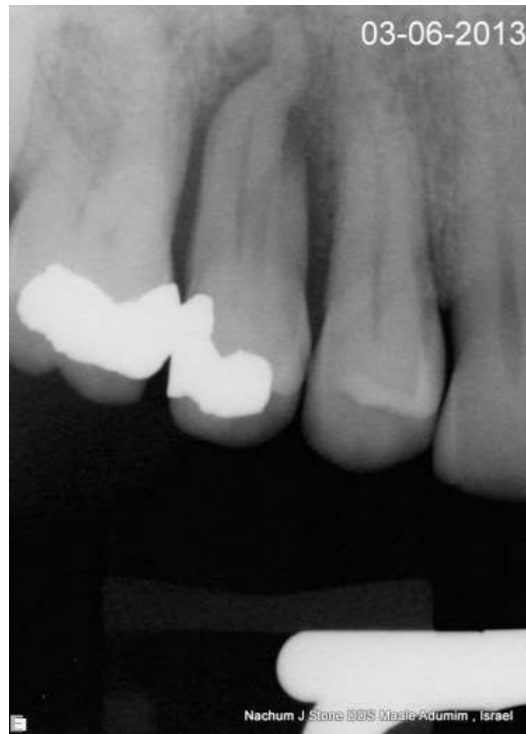Augmentation using  
Bond Apatite®



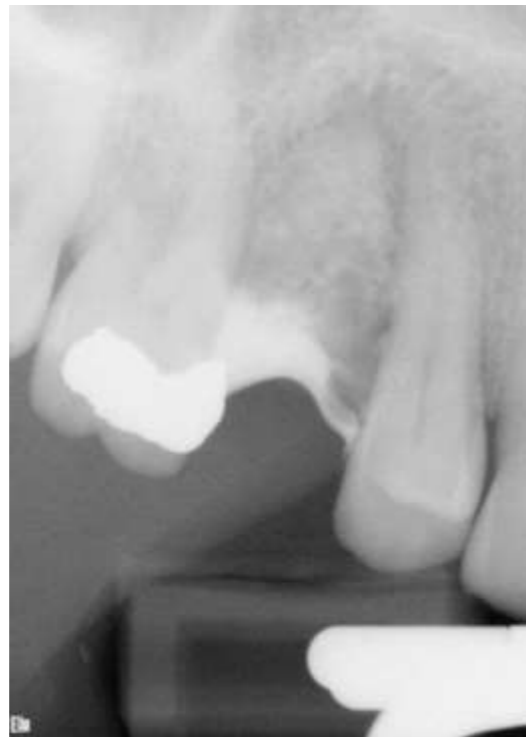On day 1 after extraction



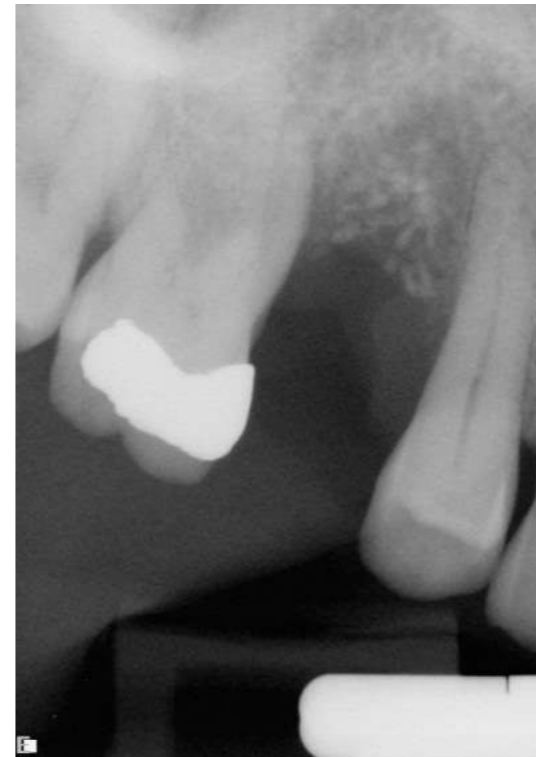# Bond Apatite® radiografing behavior during healing



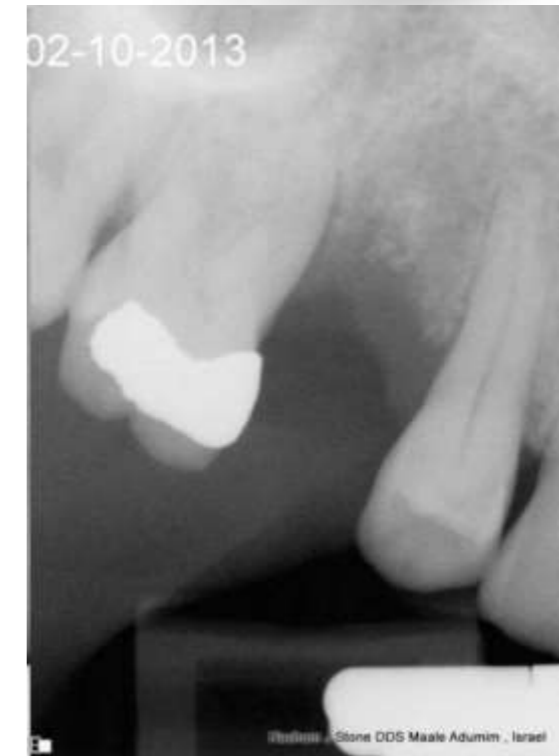Before extraction



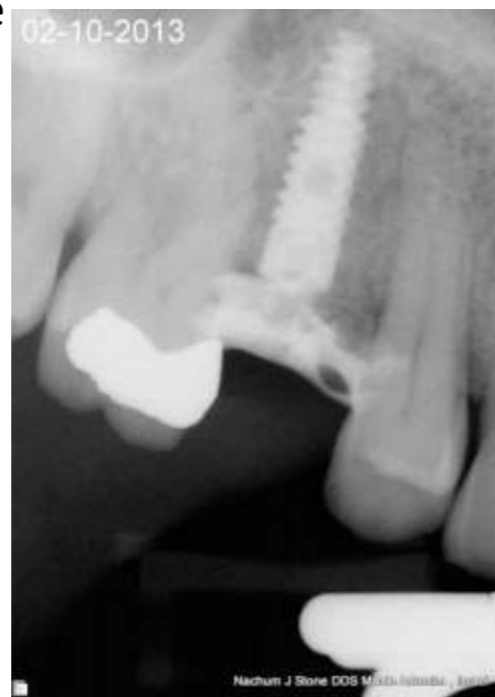Radio opacity appearance on day one of the Bond Apatite® In place



3 weeks post op degradation of the Calcium sulfate matrix

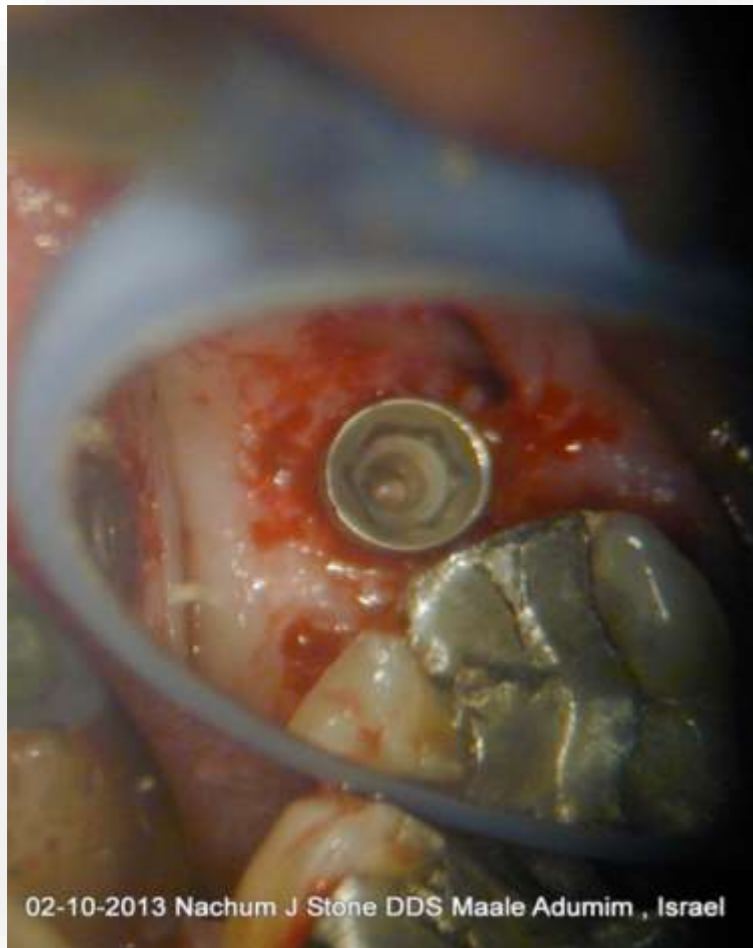



16 weeks post op, calcification of the grafted area can be seen

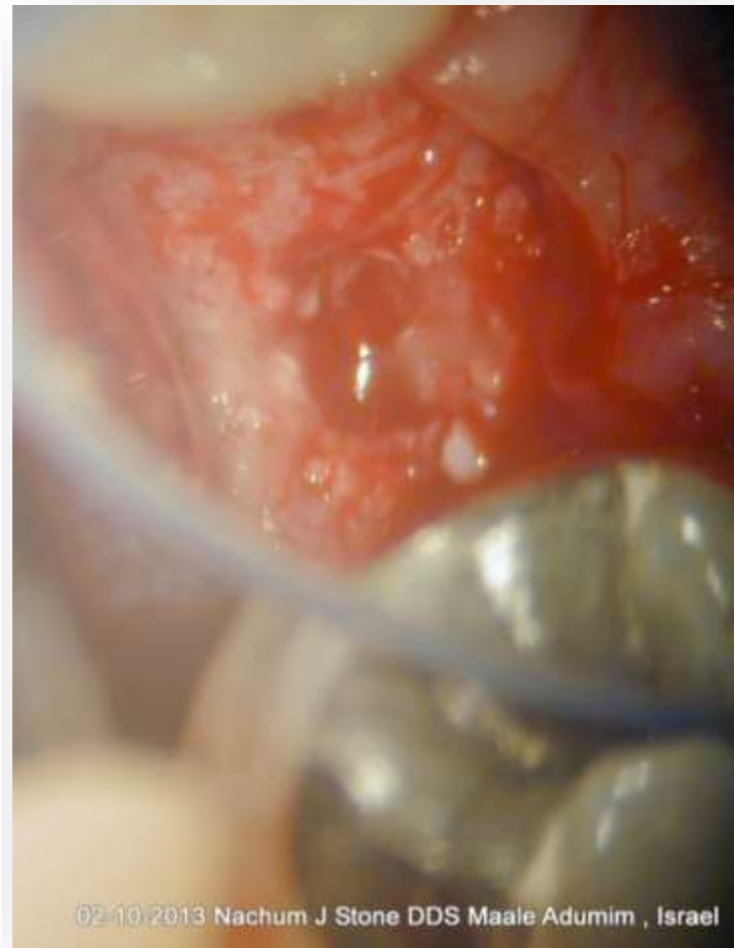


16 weeks post op, implant was placed with good primary stability

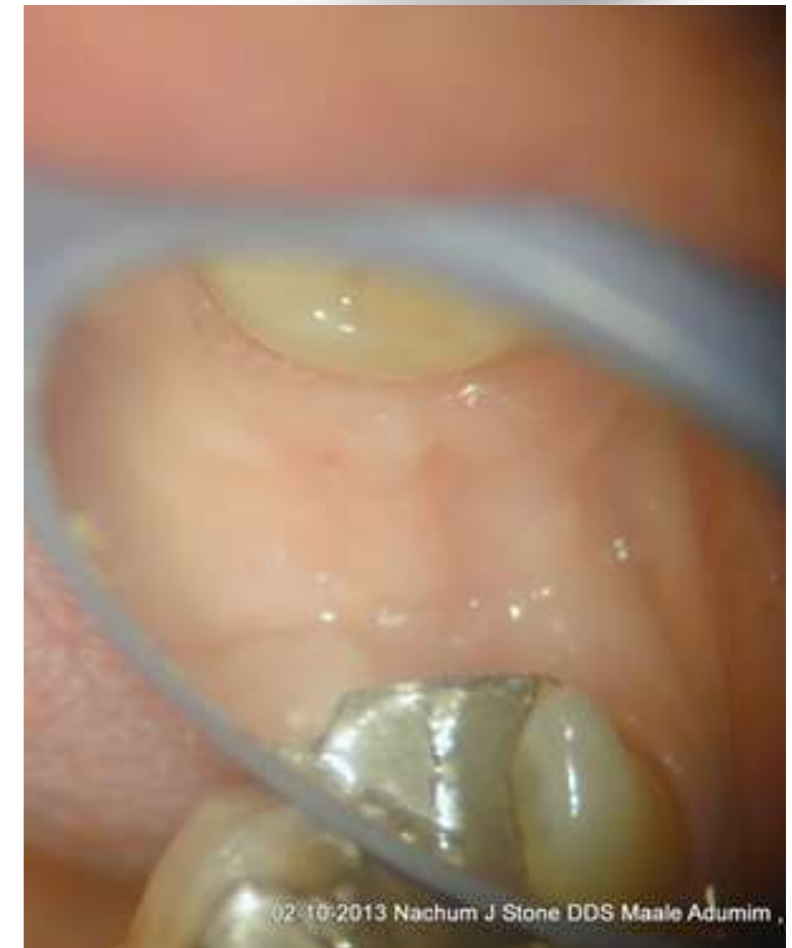# Augmentation using Bond Apatite®



16 weeks post op  
Implant in place

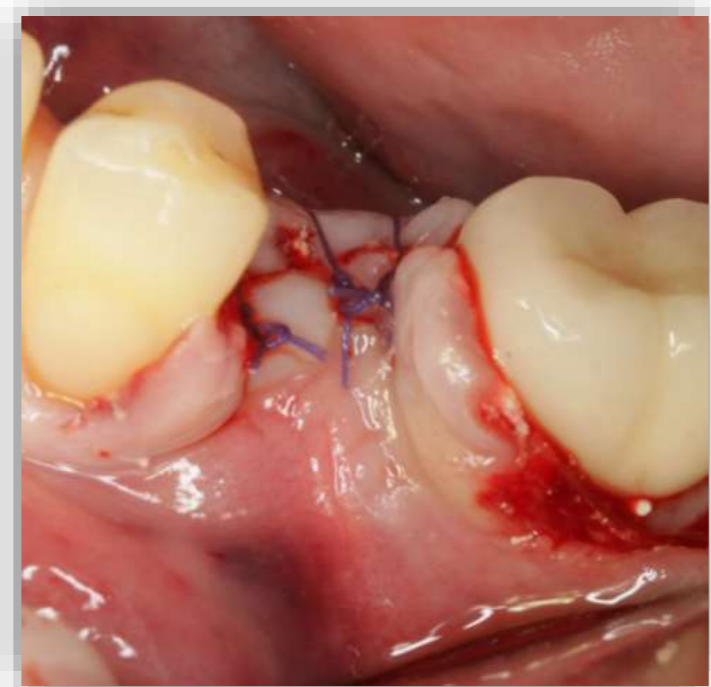
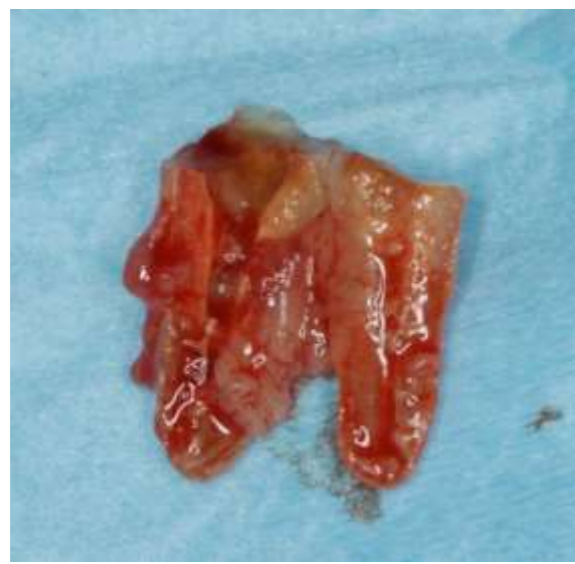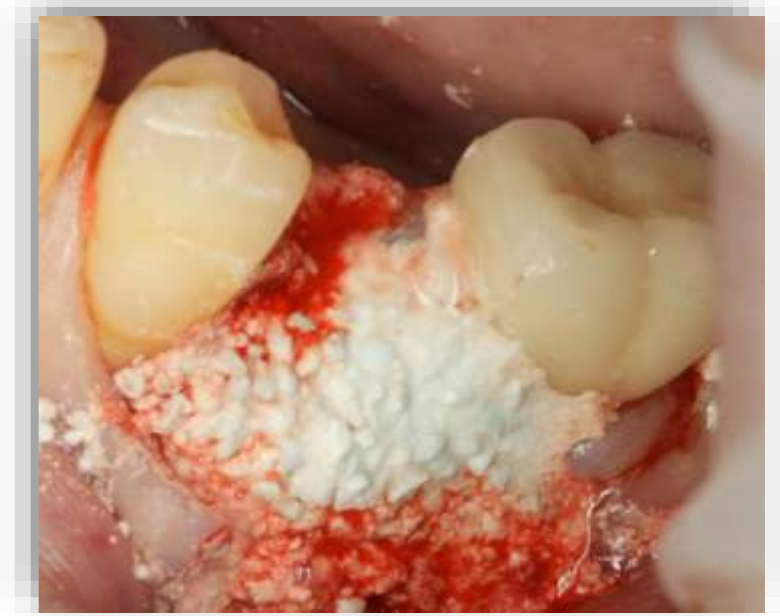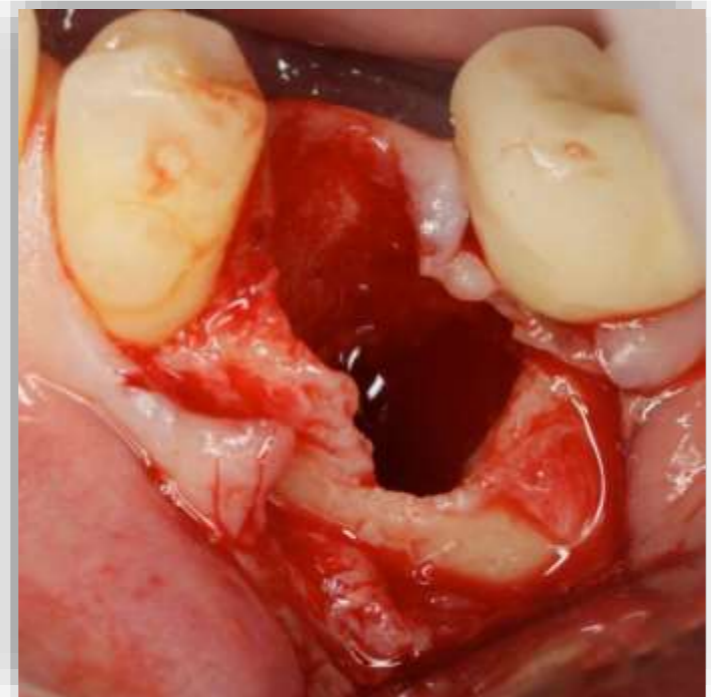
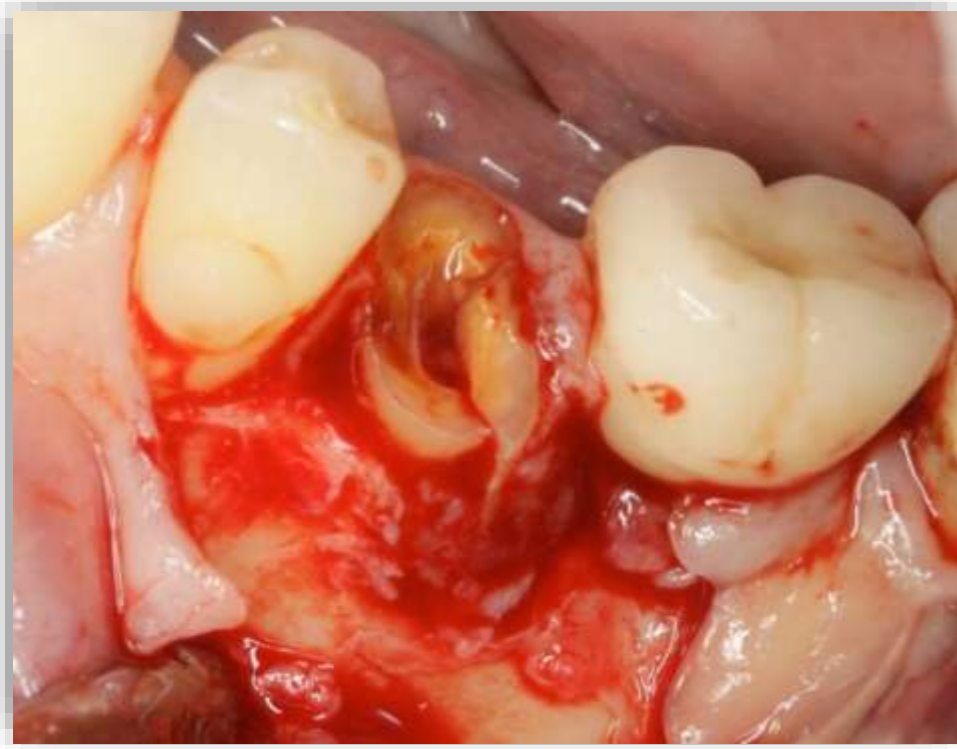



16 weeks post op  
Hard tissue appearance



16 weeks post op  
Soft tissue appearance)

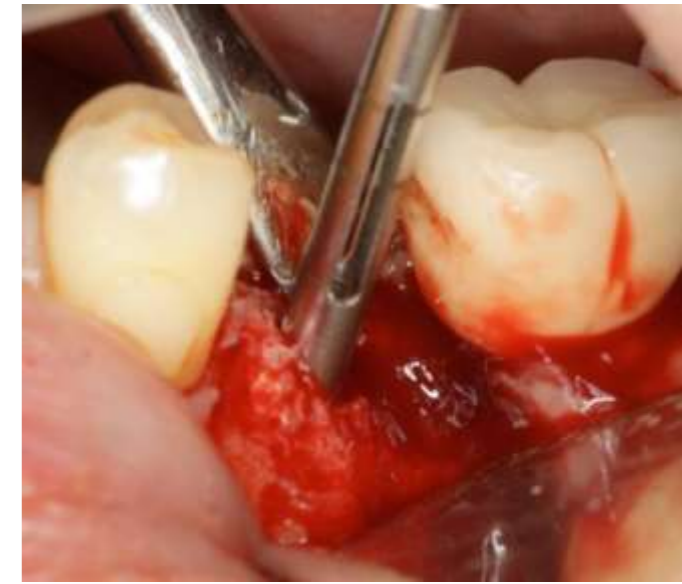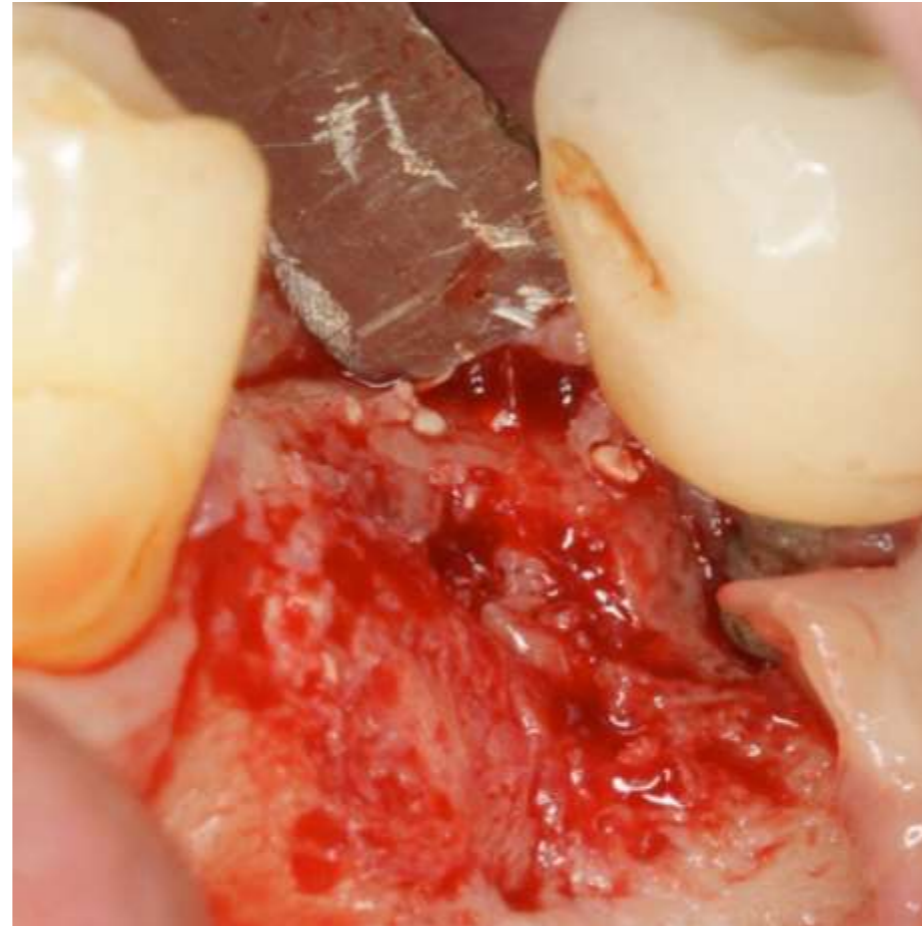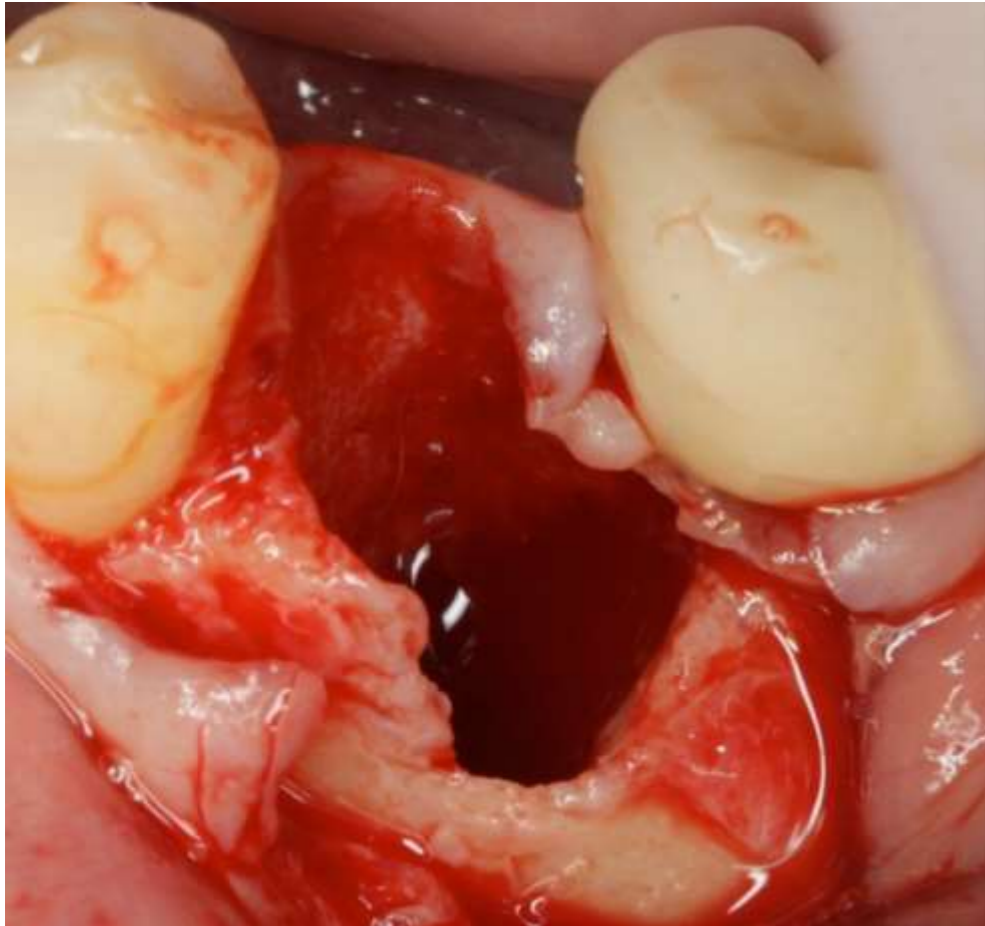
# Augmentation after removal of fractured root using Bond Apatite®

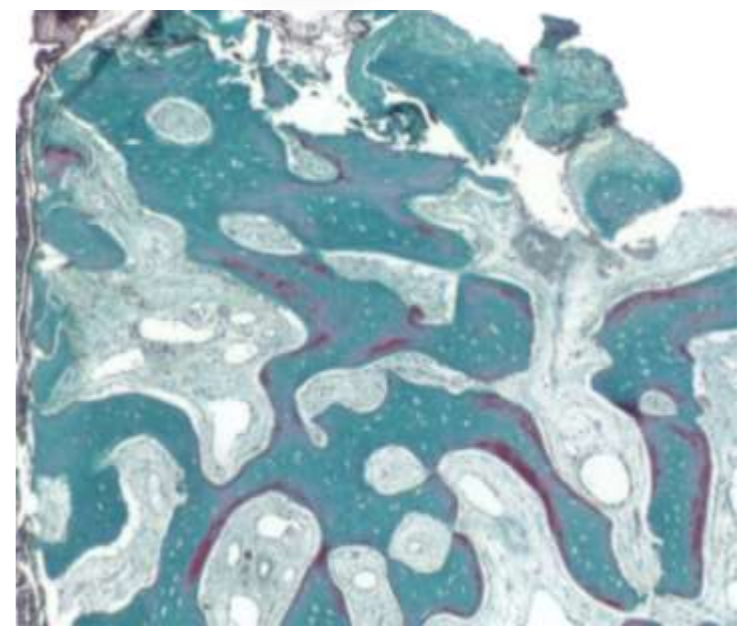
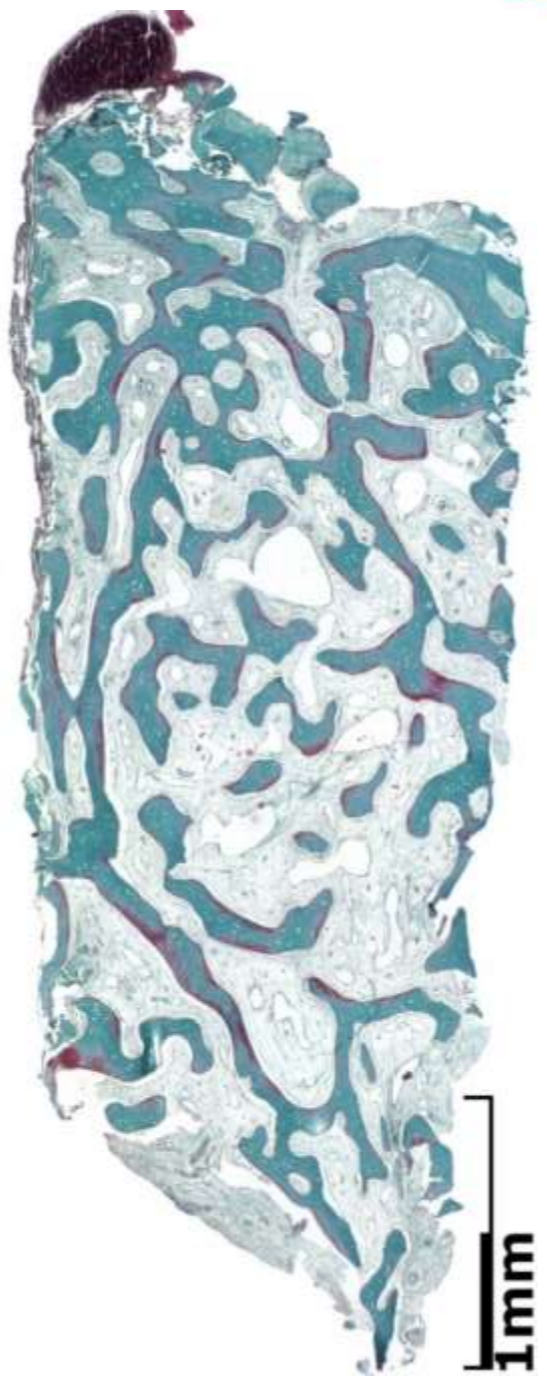
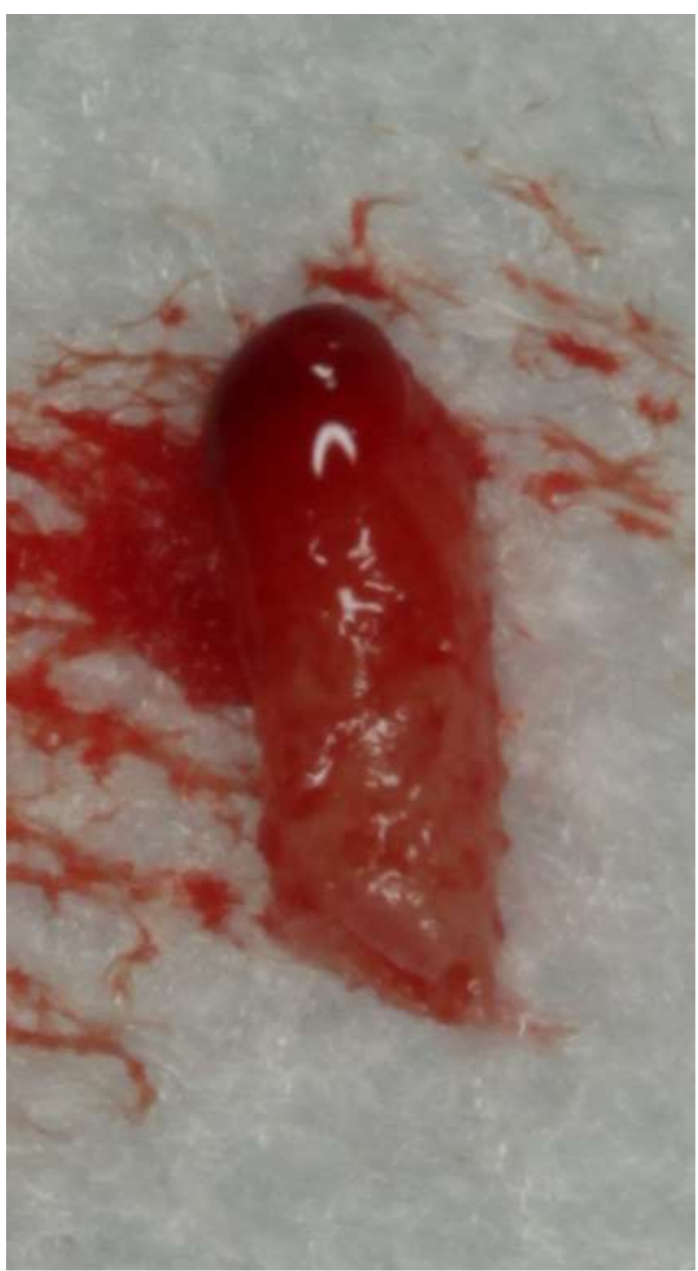


**Bond Apatite®**  
Bone Graft Cement

  
**Augma**  
BIOMATERIALS

# 3 month post op

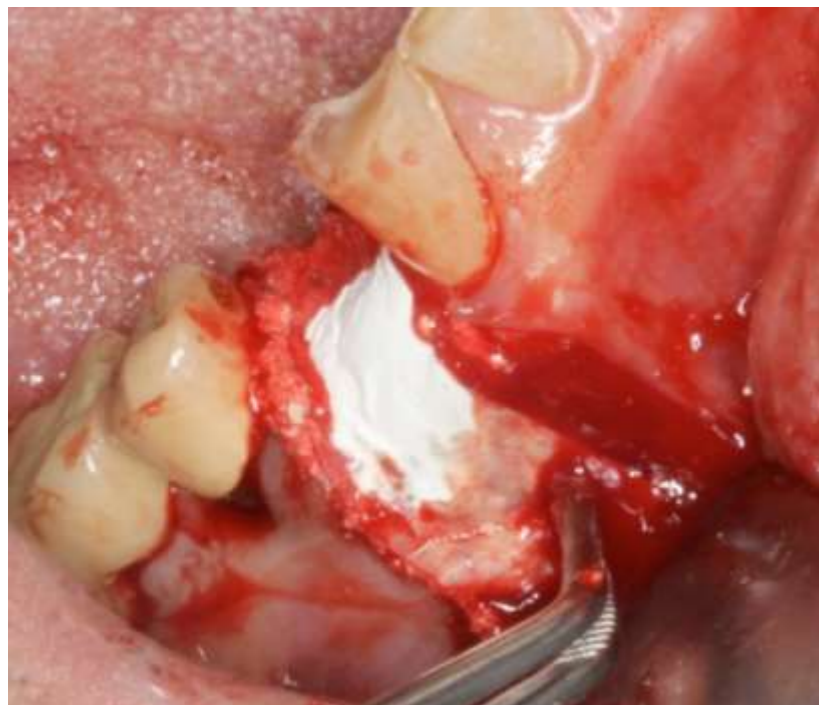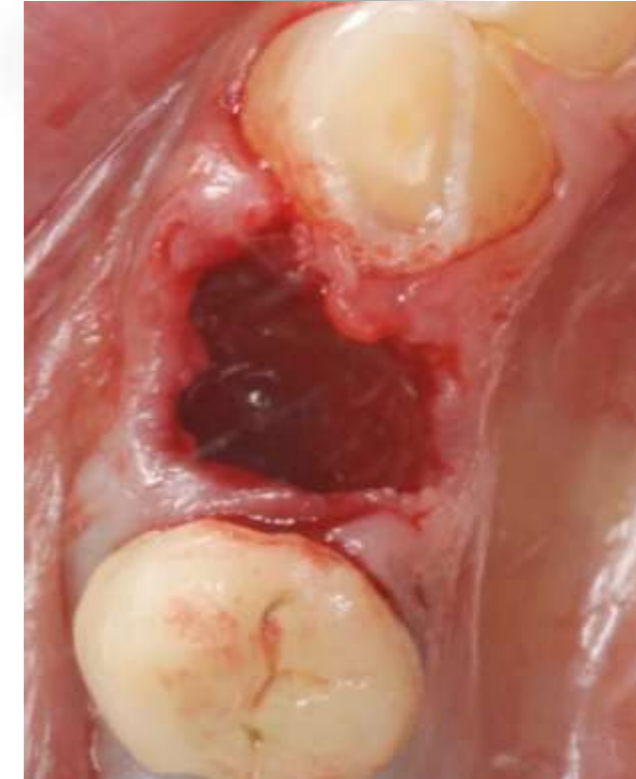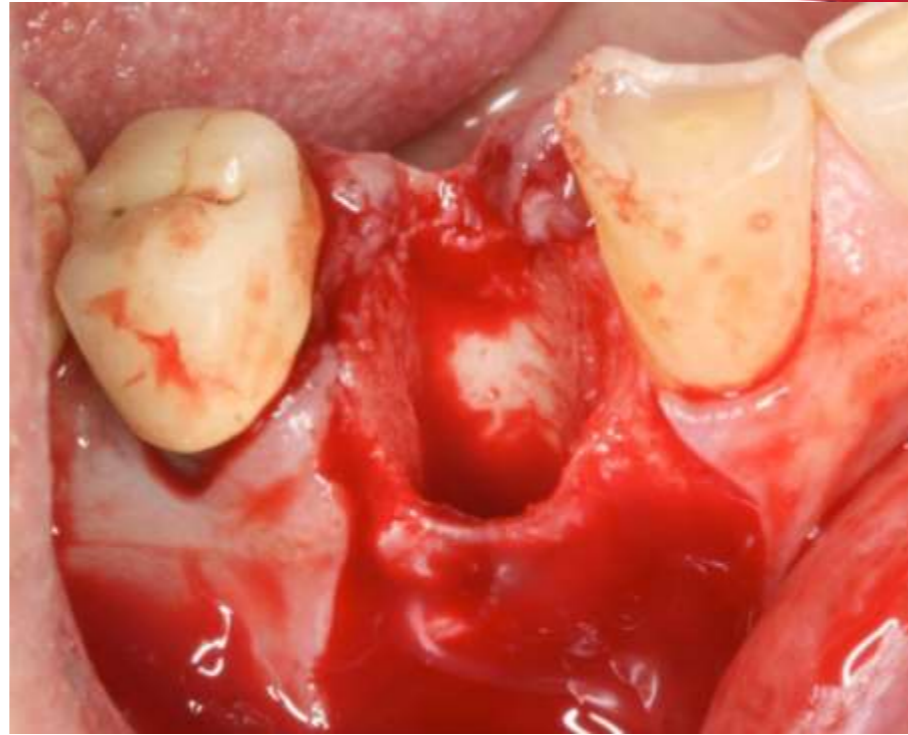


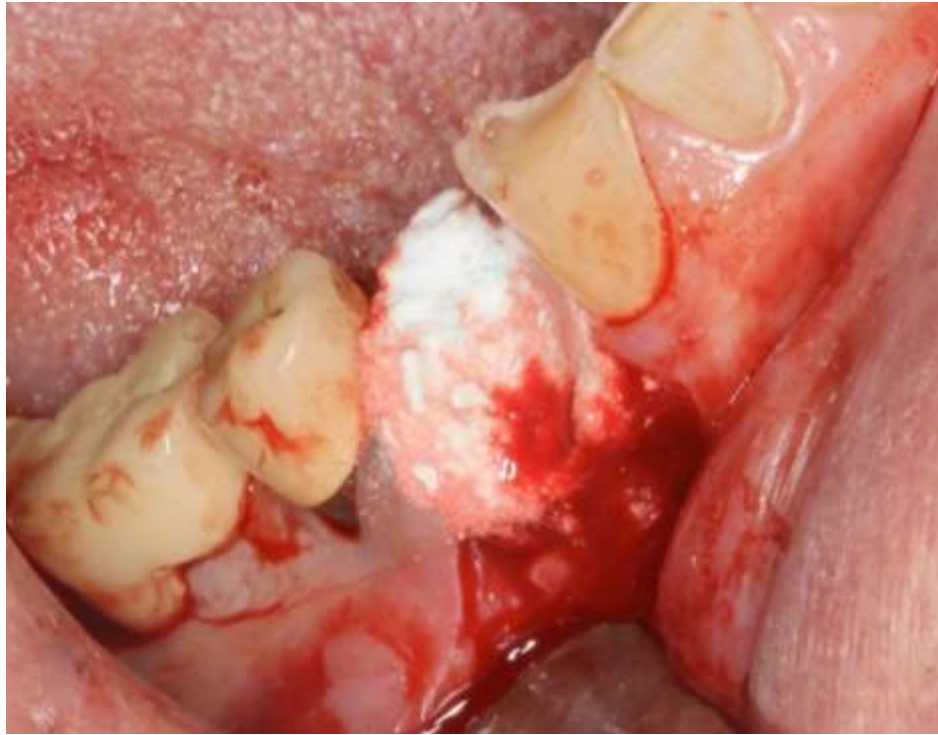

**Bond Apatite<sup>®</sup>**  
Bone Graft Cement

  
**Augma**  
BIOMATERIALS

# Socket preservation using Bond Apatite®

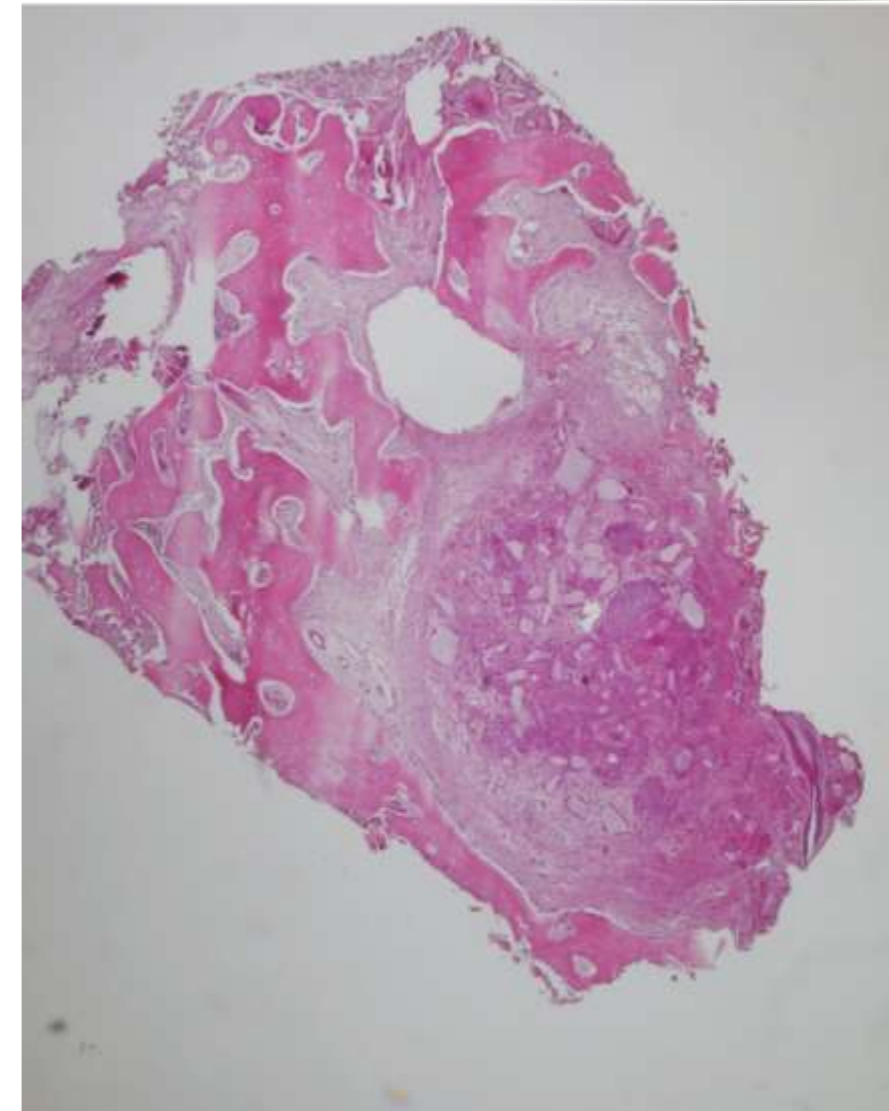
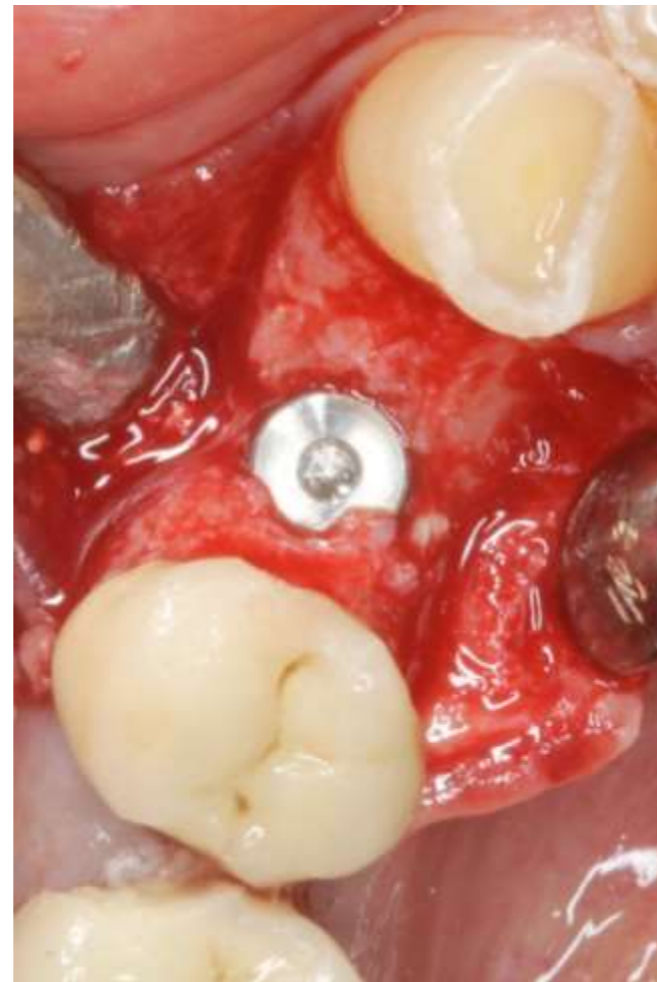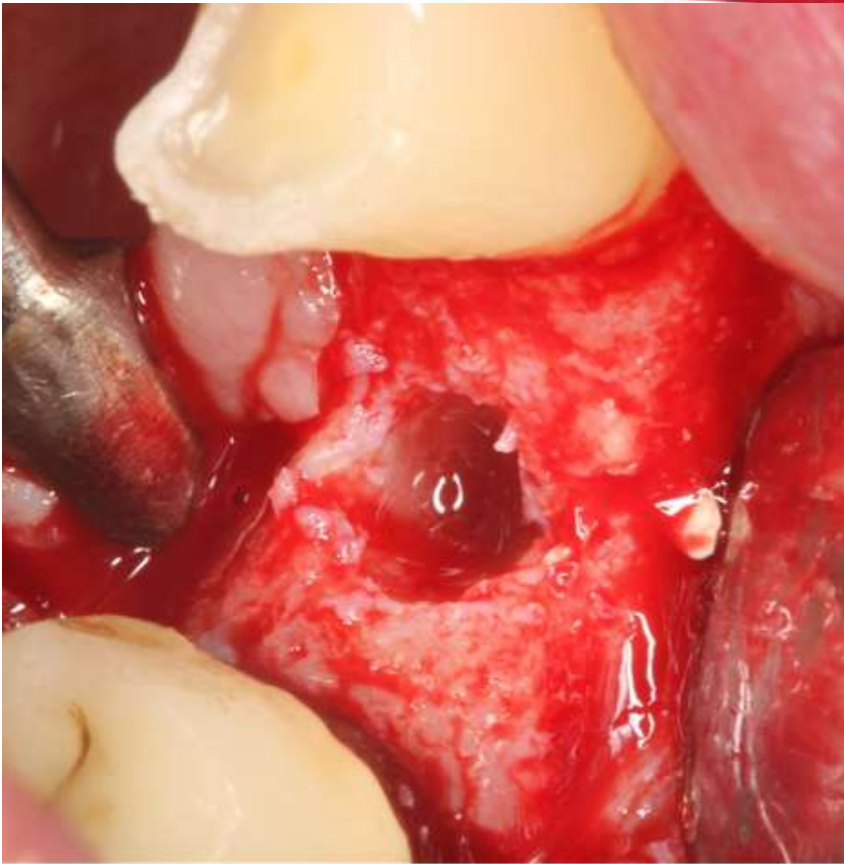



Bone Graft Cement

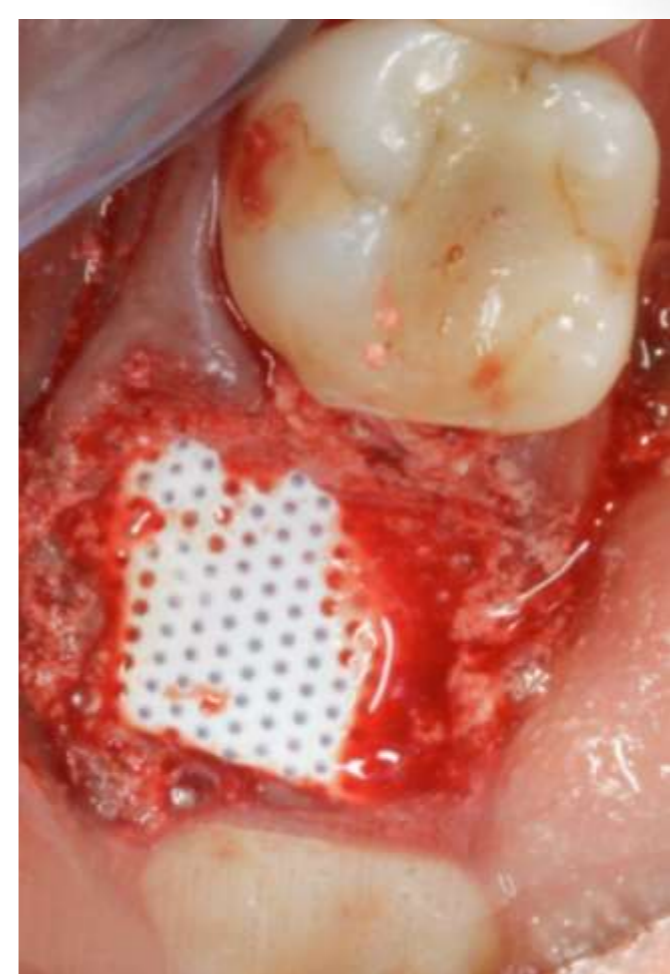
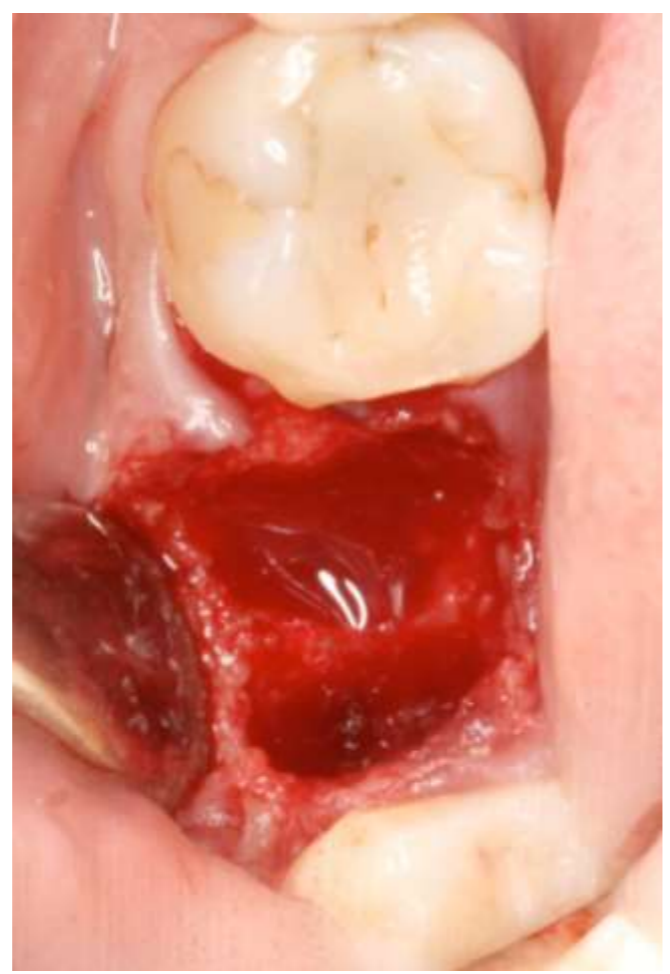
Surgery professor Ziv Mazor ,DMD Israel



3 months post op implant was placed and core was taken foe histologic evaluation



Preservation using Bond Apatite® temporarily covered by PTFE m

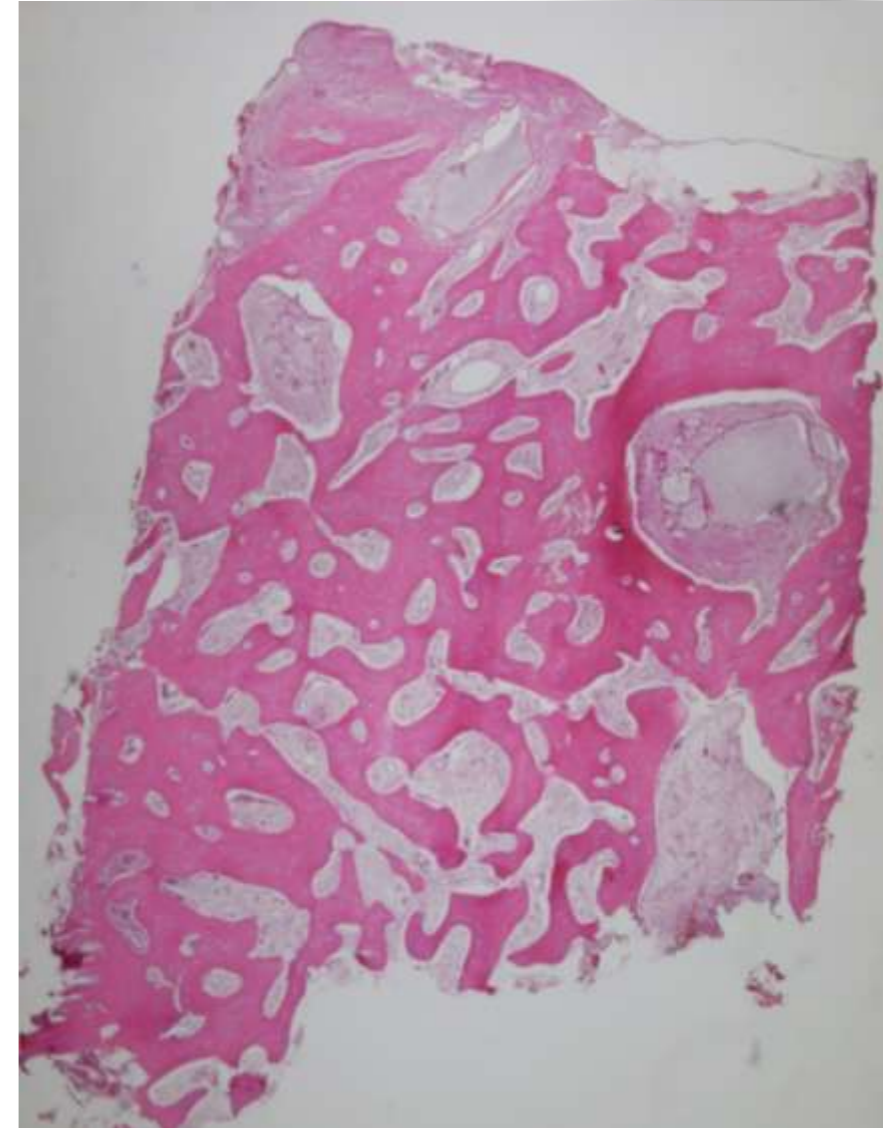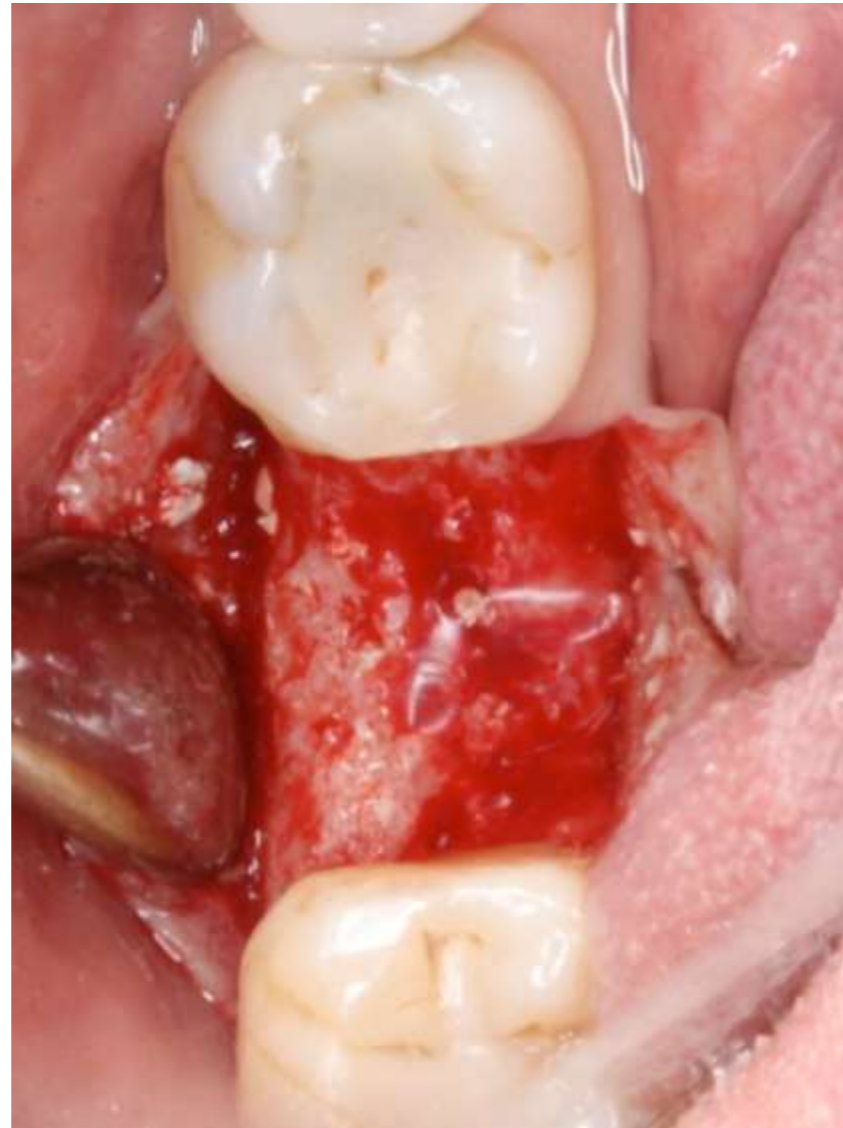

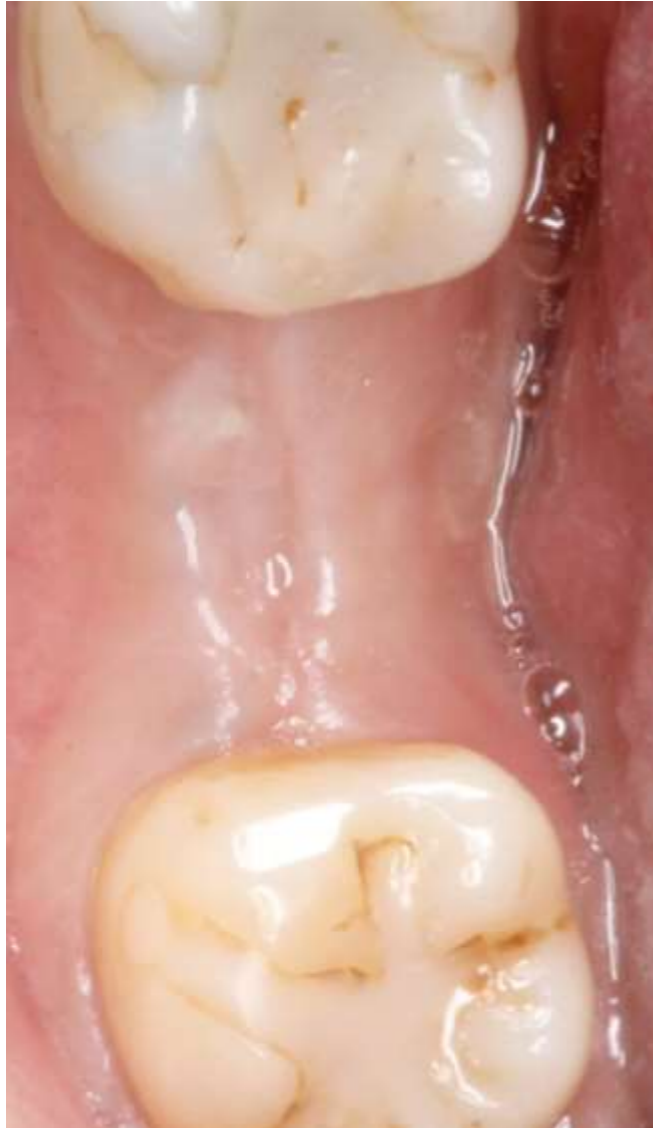

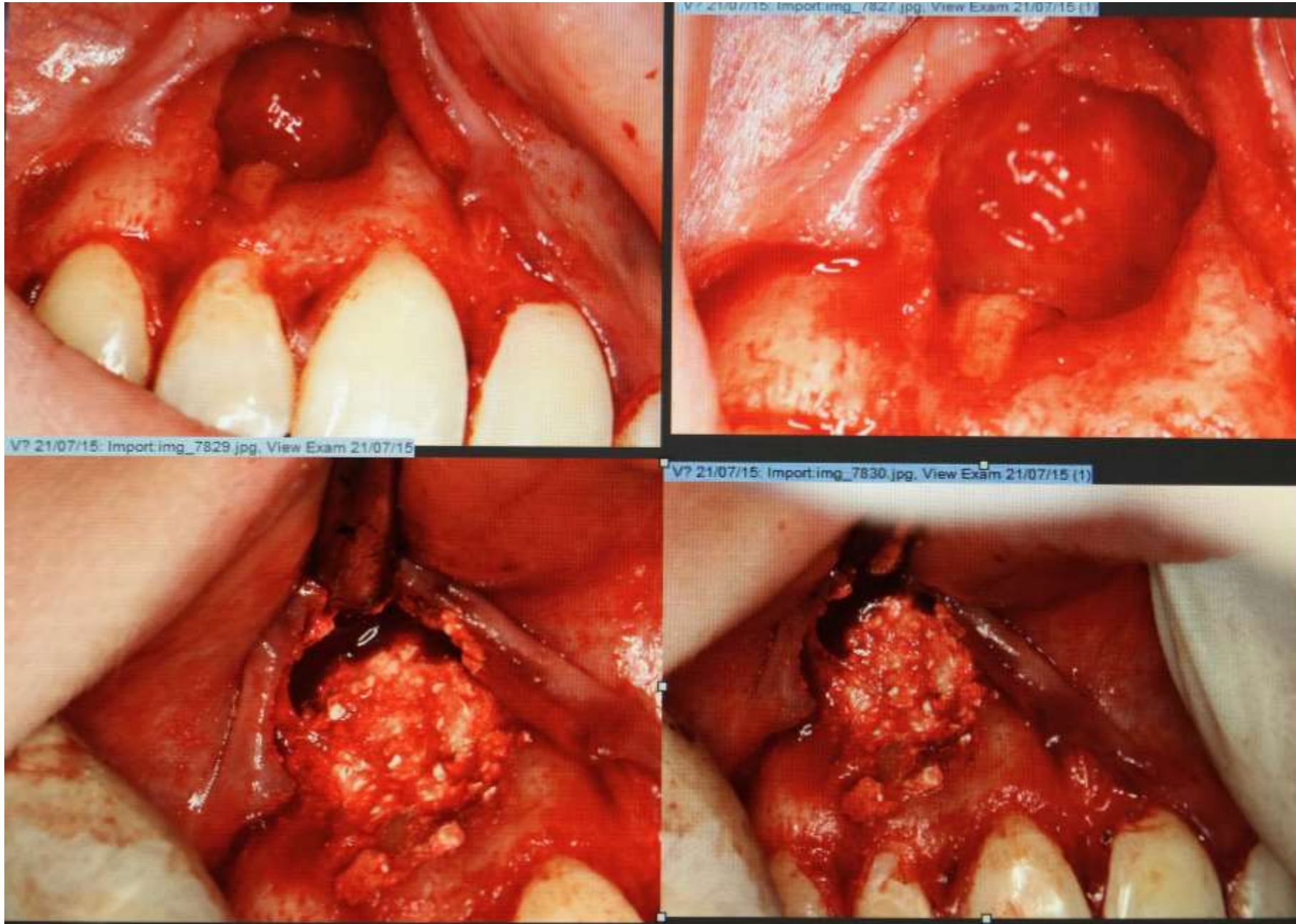**Bond Apatite®**  
Bone Graft Cement

Surgery professor Ziv Mazor, DMD Israel



# Clinical and histologic appearance 3 months post op



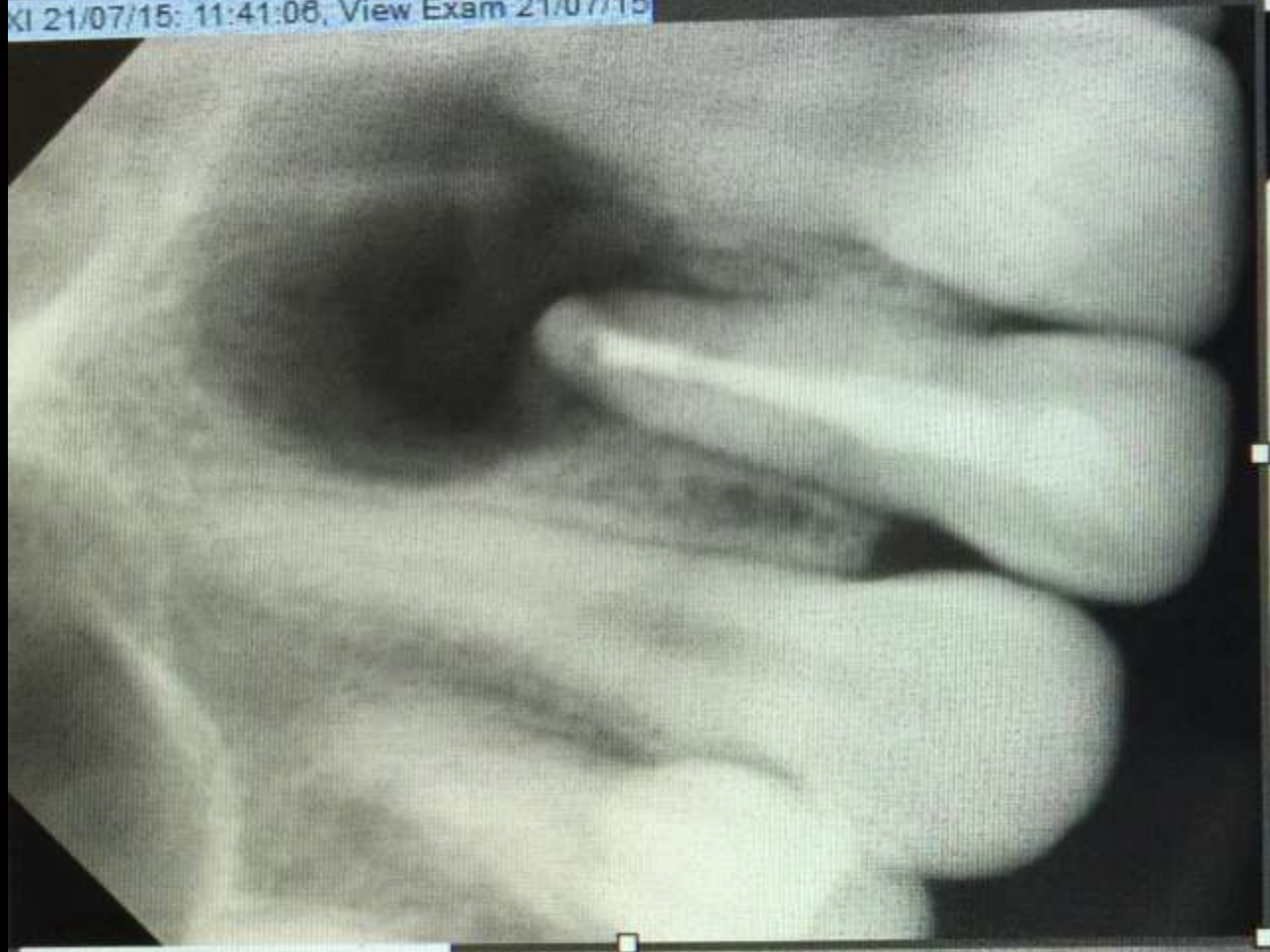

**Bond Apatite®**  
Bone Graft Cement

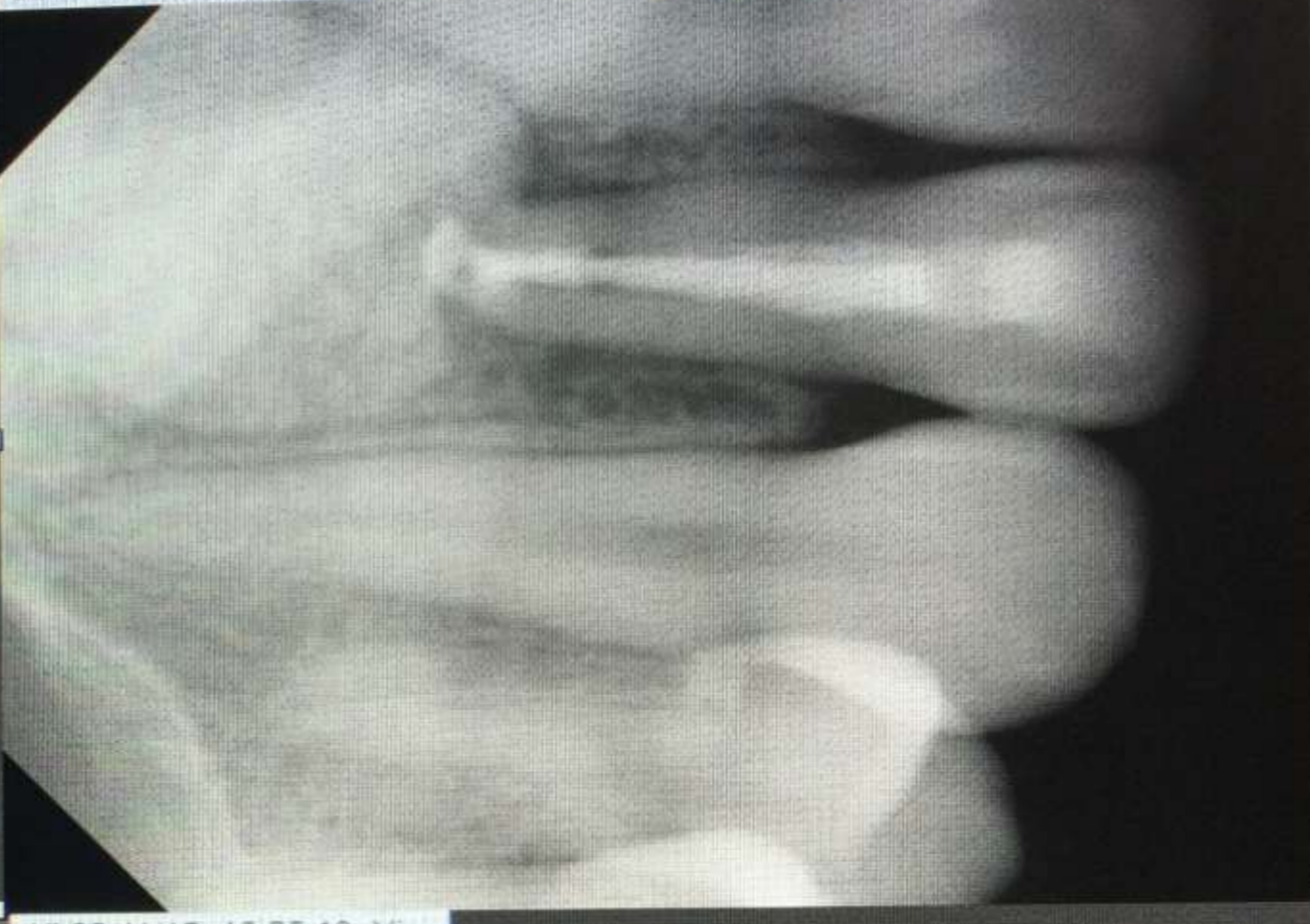surgery Dr. Mike Glassman South Africa

  
**Augma**  
BIOMATERIALS

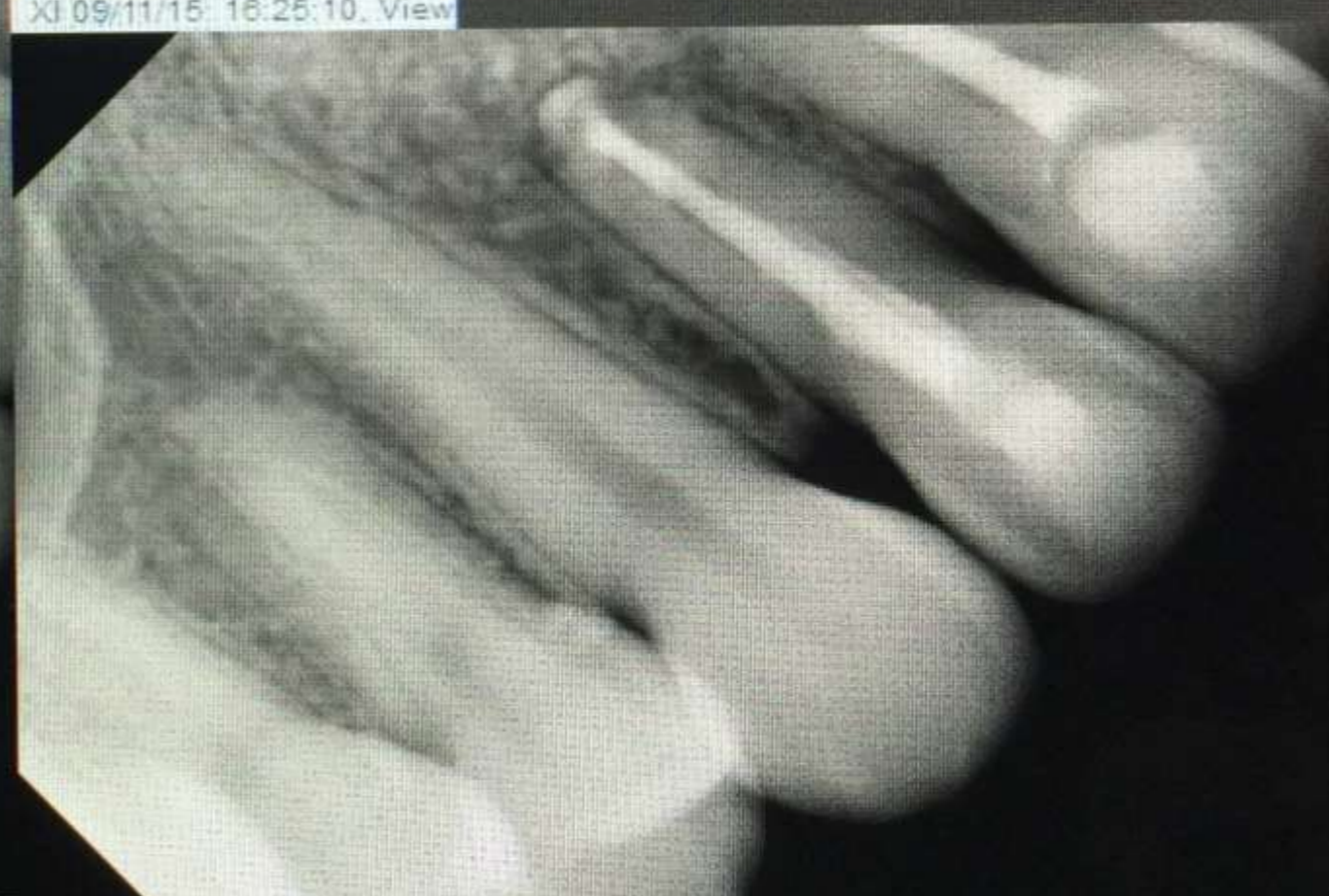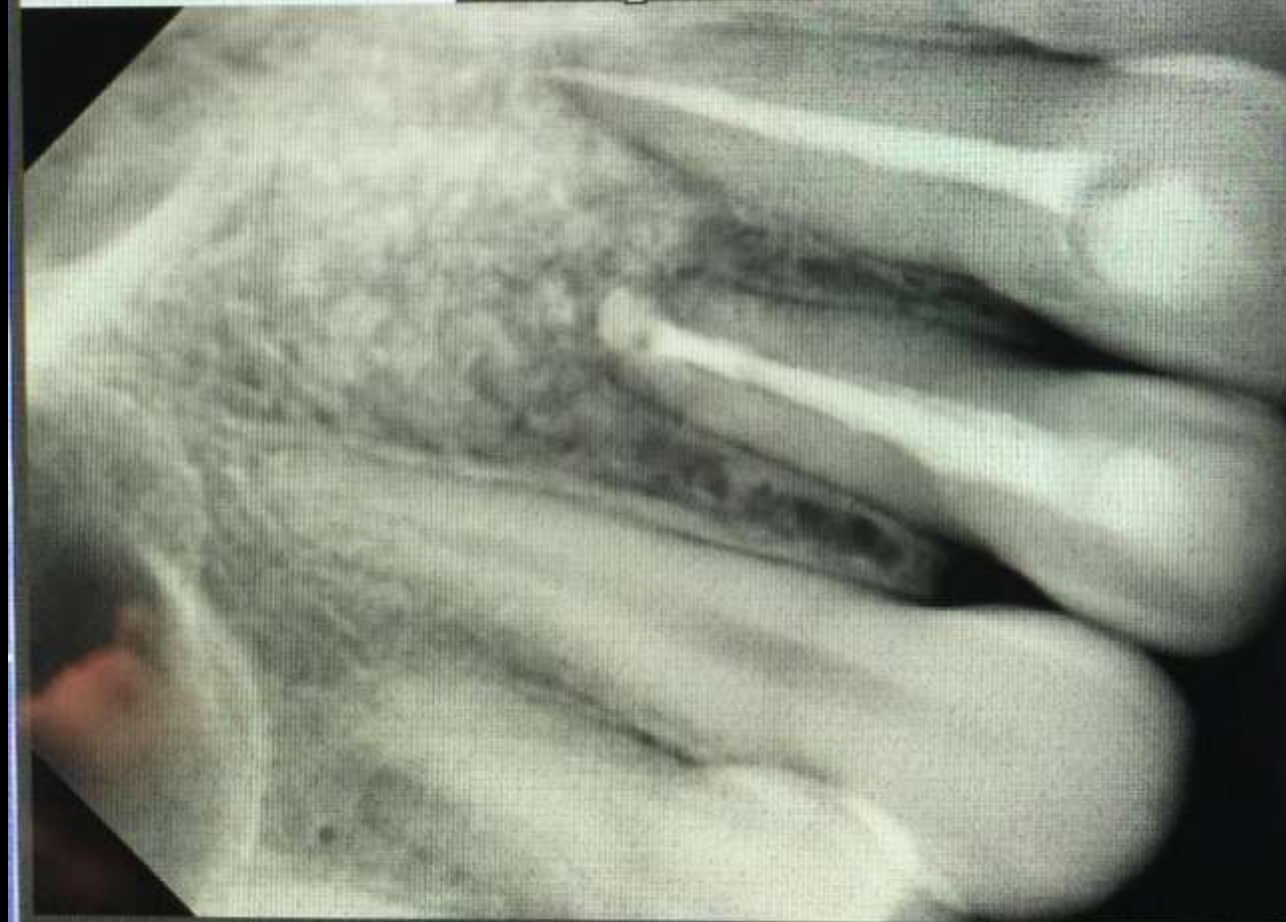XI 21/07/15: 11:41:06, View Exam 21/07/15



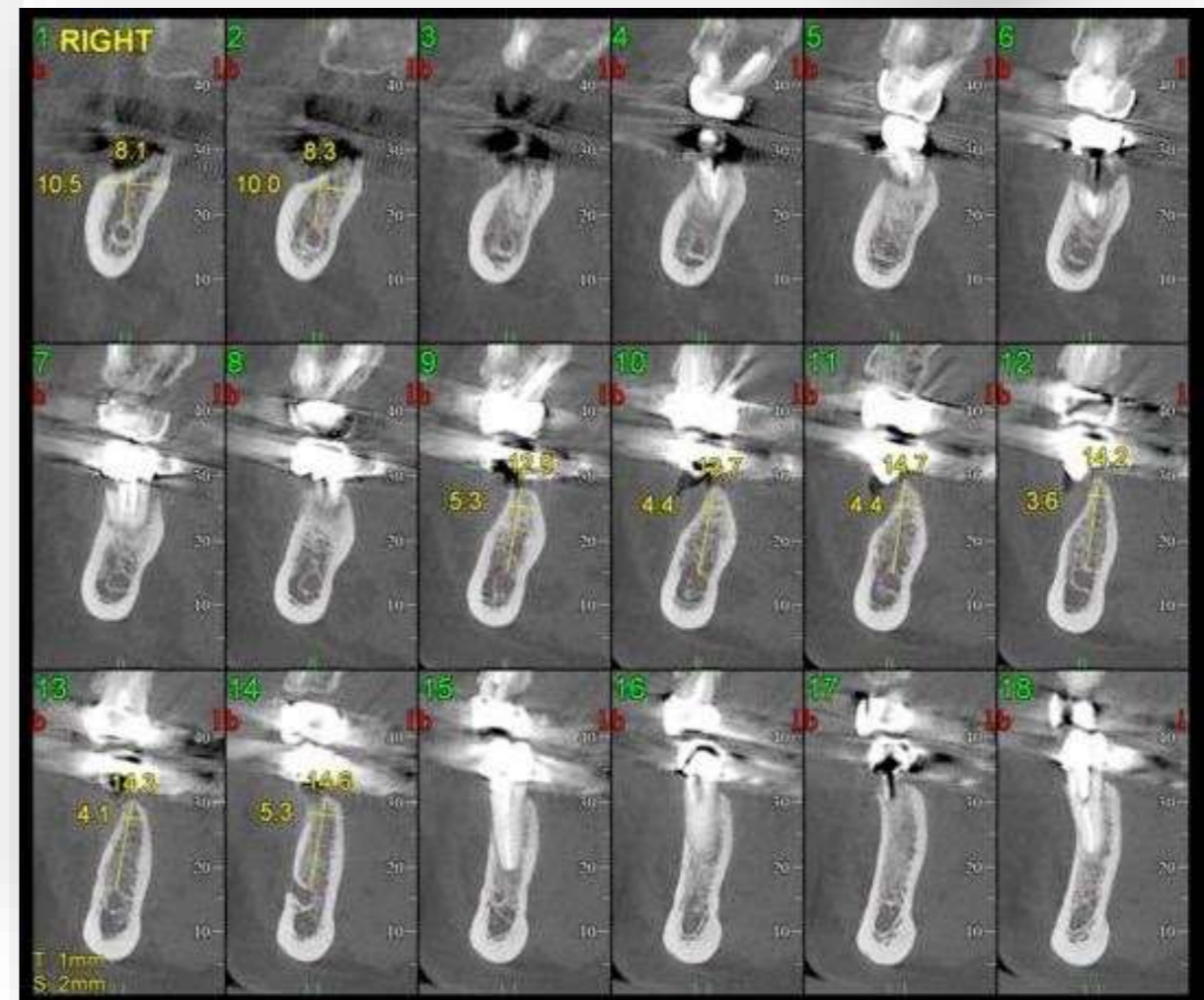
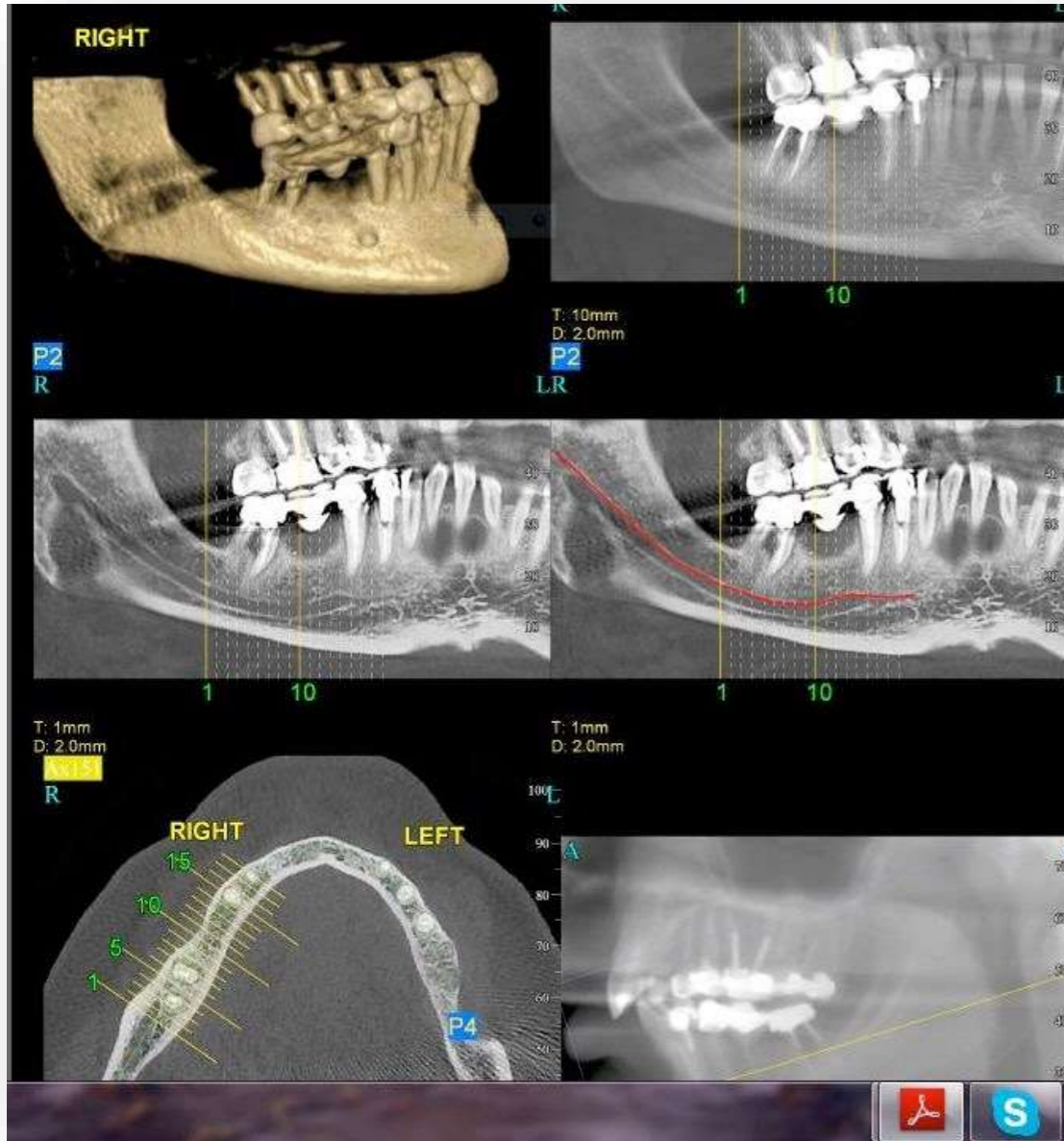
XI 21/07/15: 11:53:08, View Exam 21/07/15




XI 09/11/15: 16:25:10, View

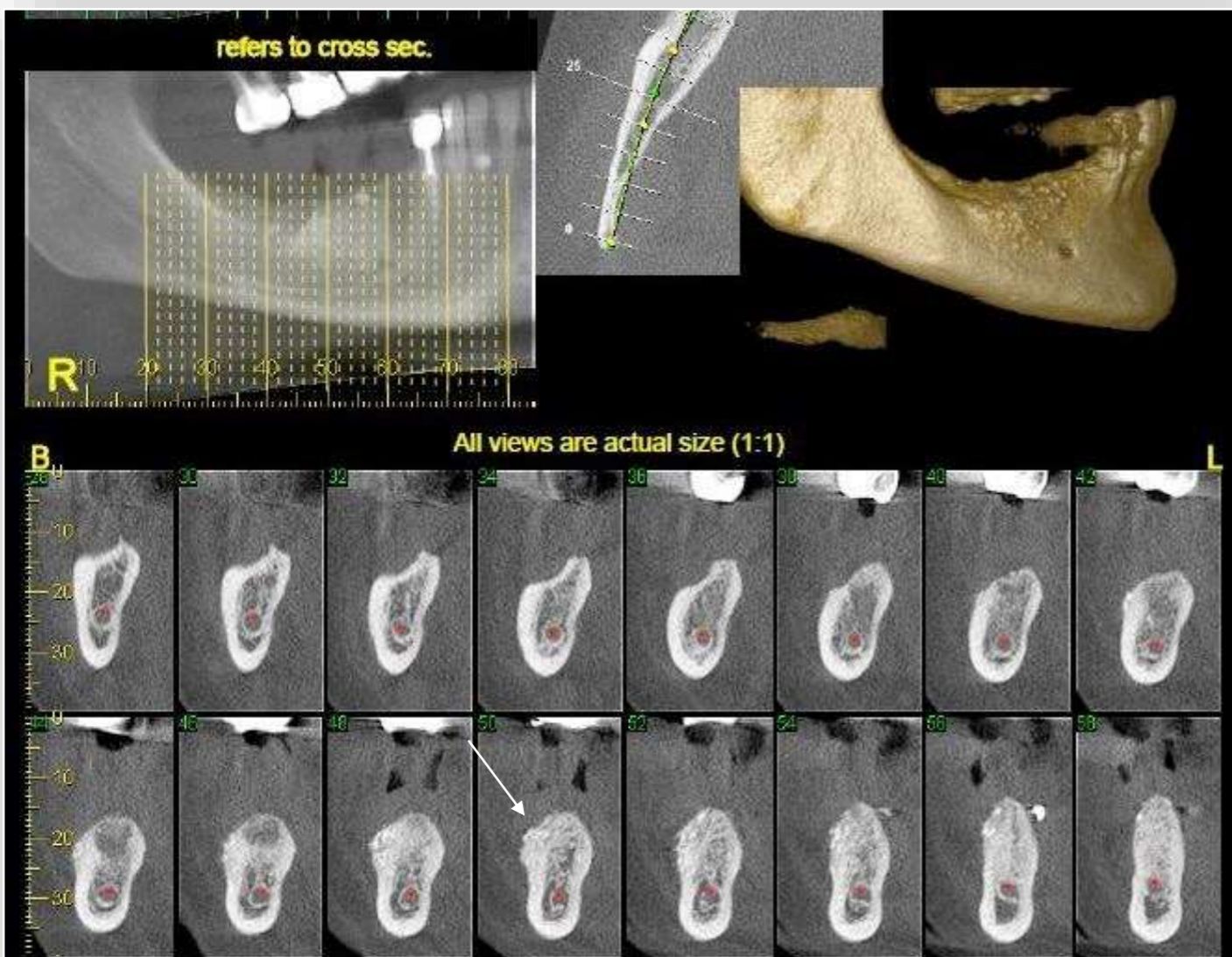



# Lateral augmentation using Bond Apatite®





Before

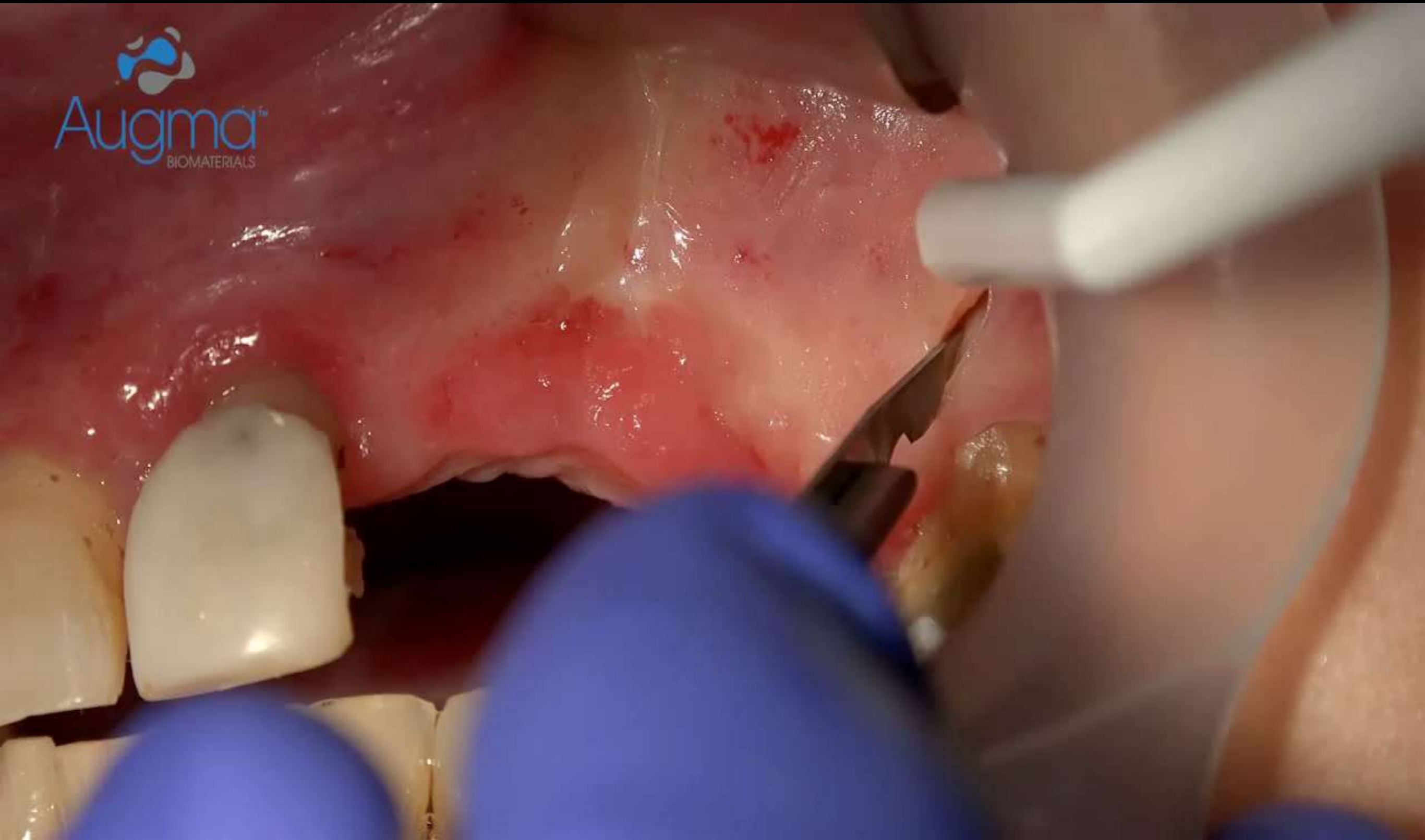


After

**Bond Apatite®**  
Bone Graft Cement

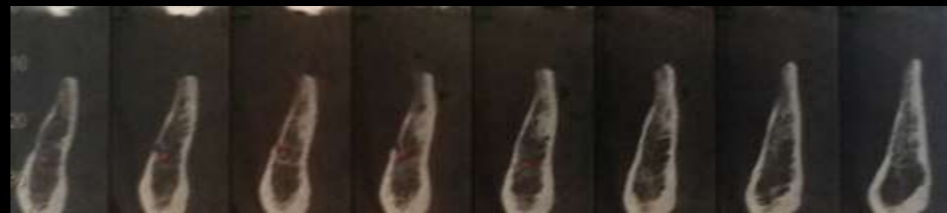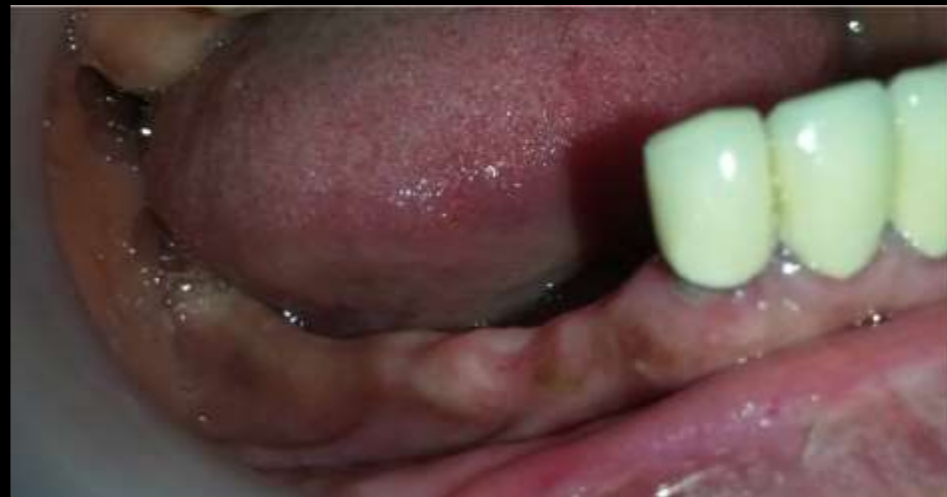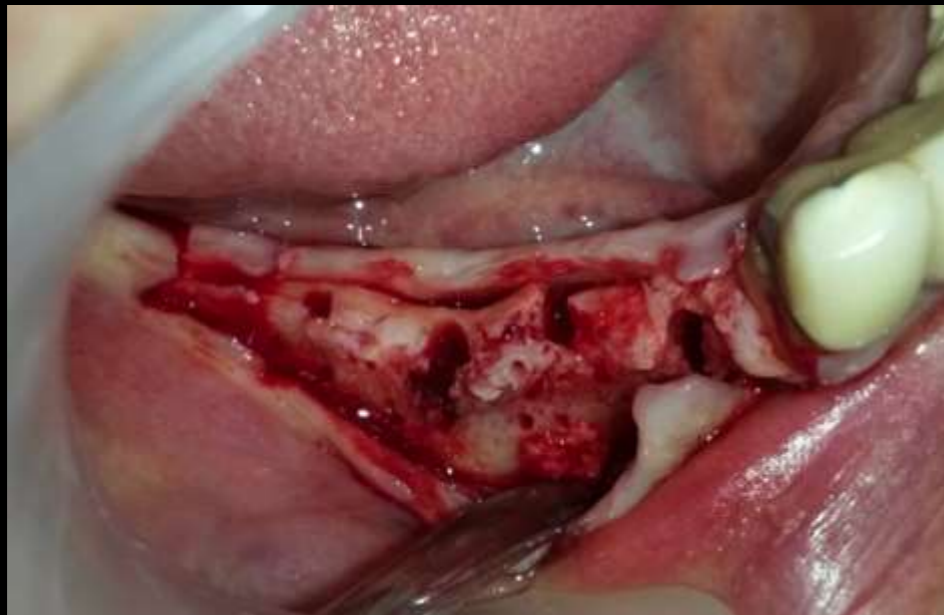Surgery by Dr. Falbert David D.M.D Jerusalem Israel

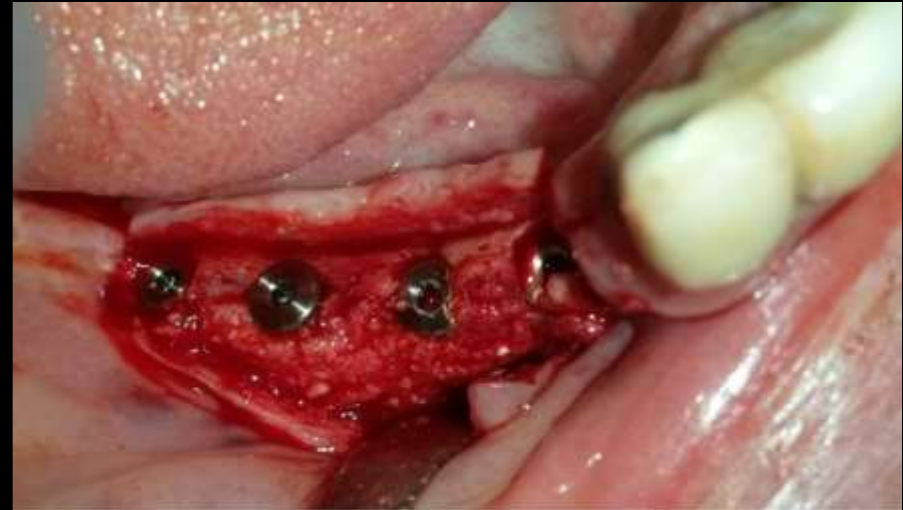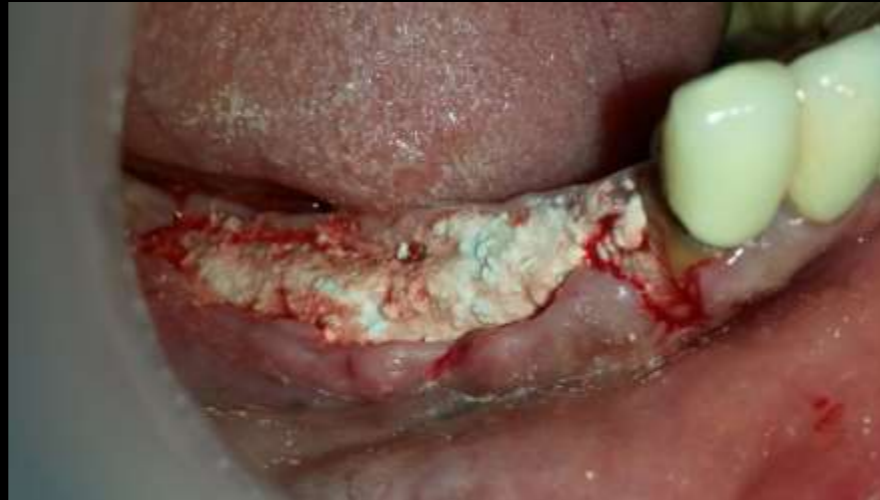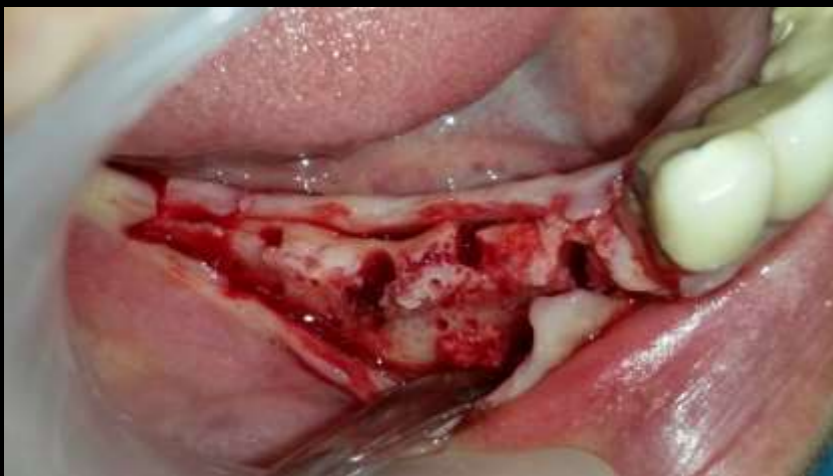**Augma**  
BIOMATERIALS






# Lateral Augmentation And Crest Widening

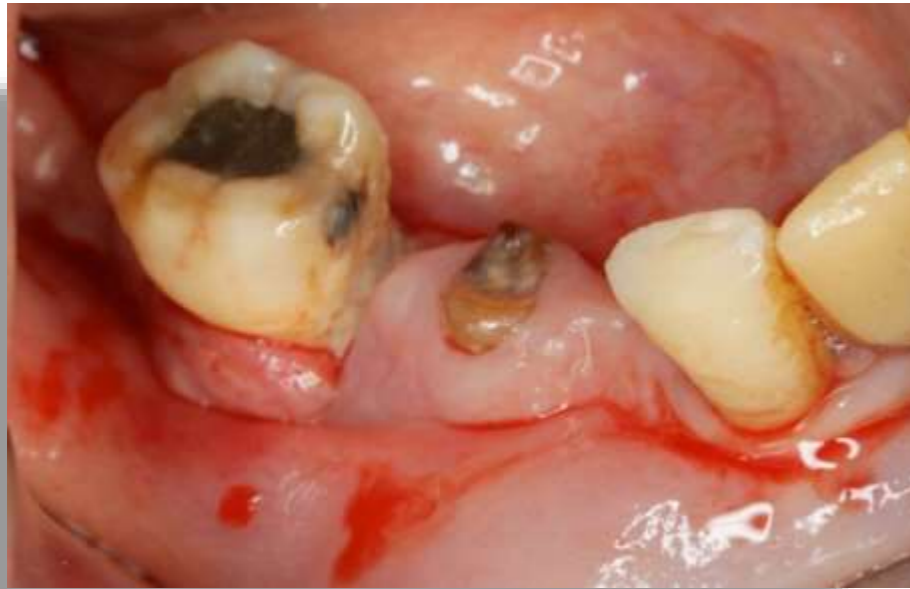



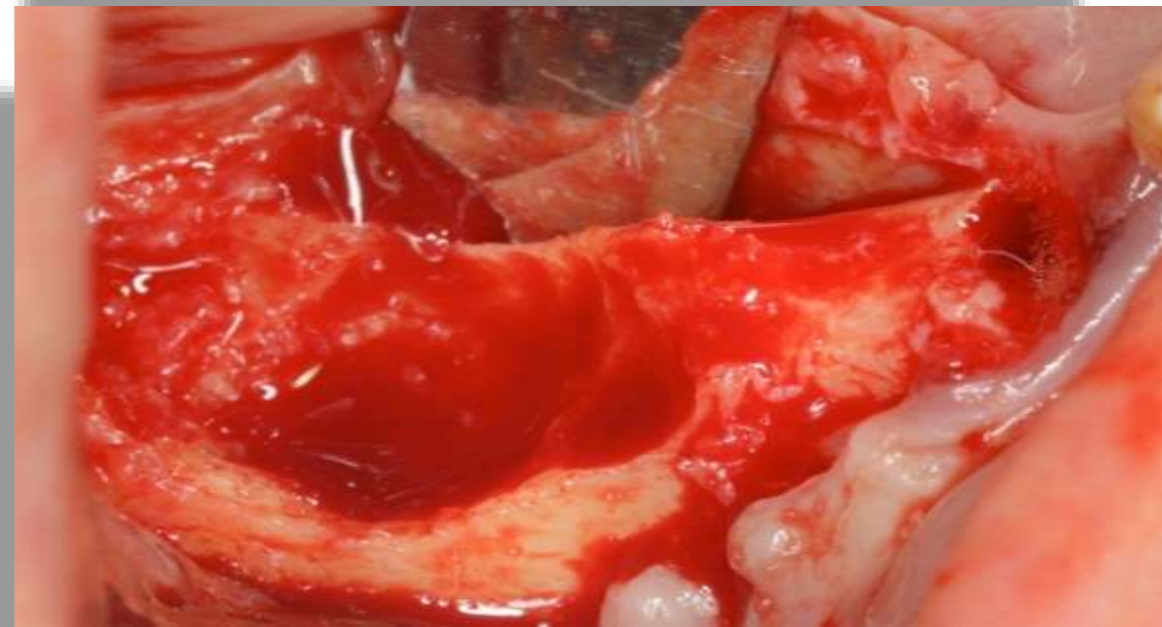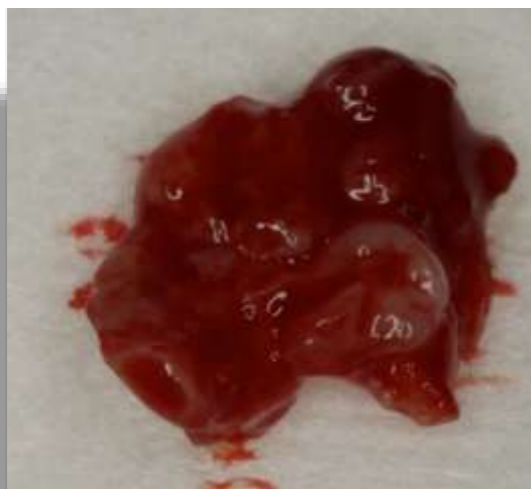
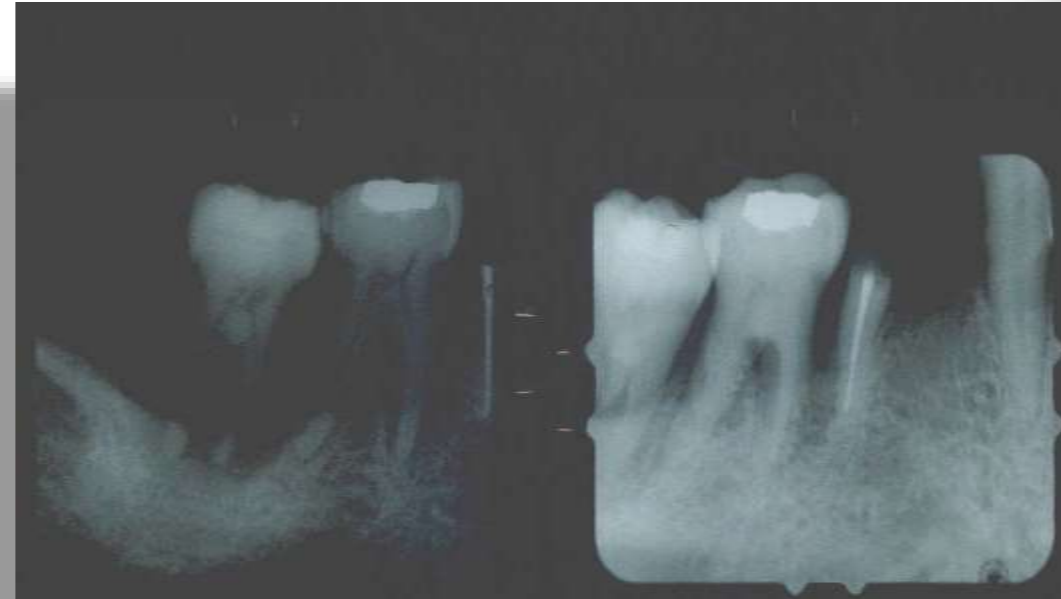
# Augmentation procedure using Bond Apatite<sup>®</sup> in a large 3D defect after hopeless tooth removal



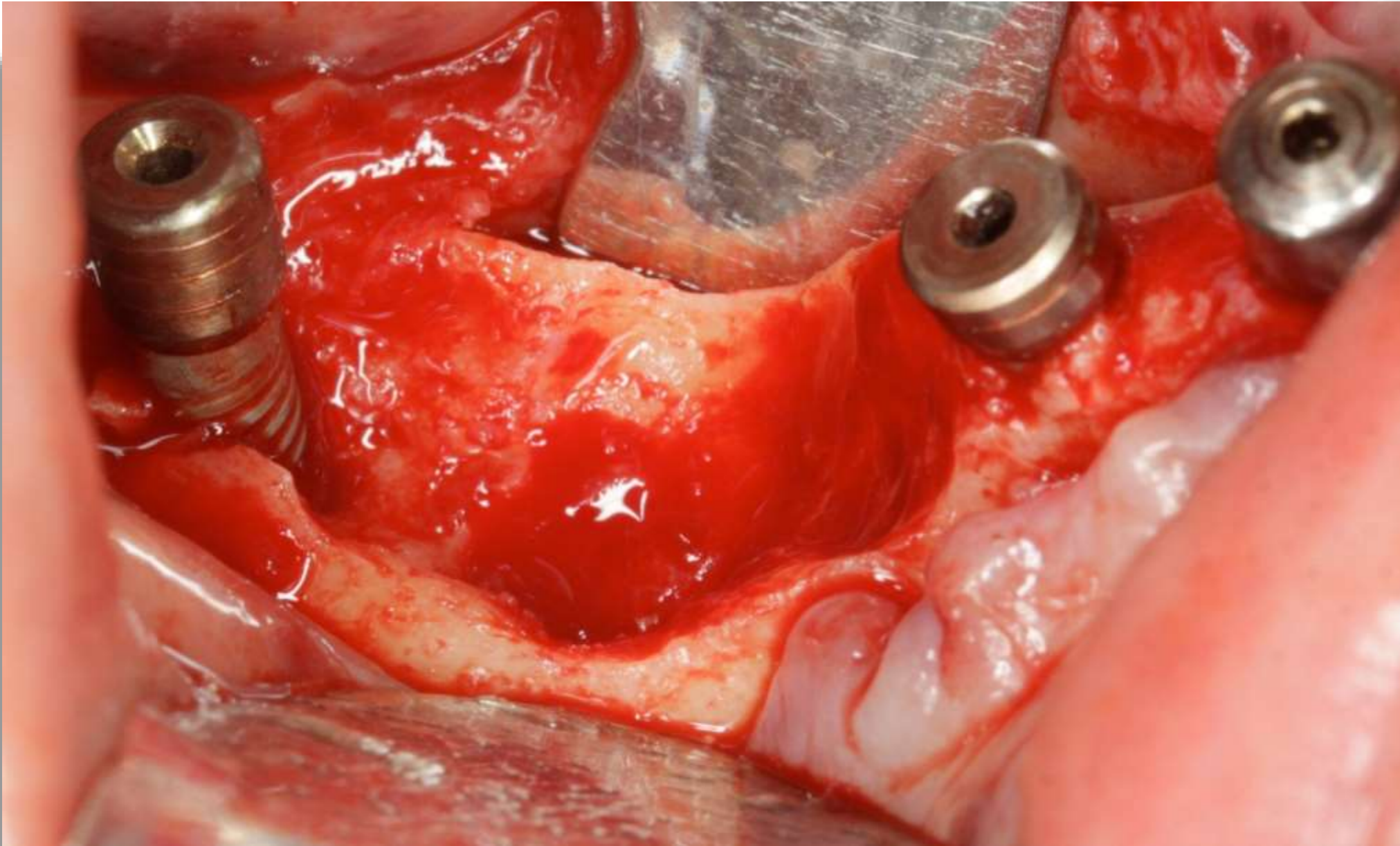
Before extraction



Radiographic appearance

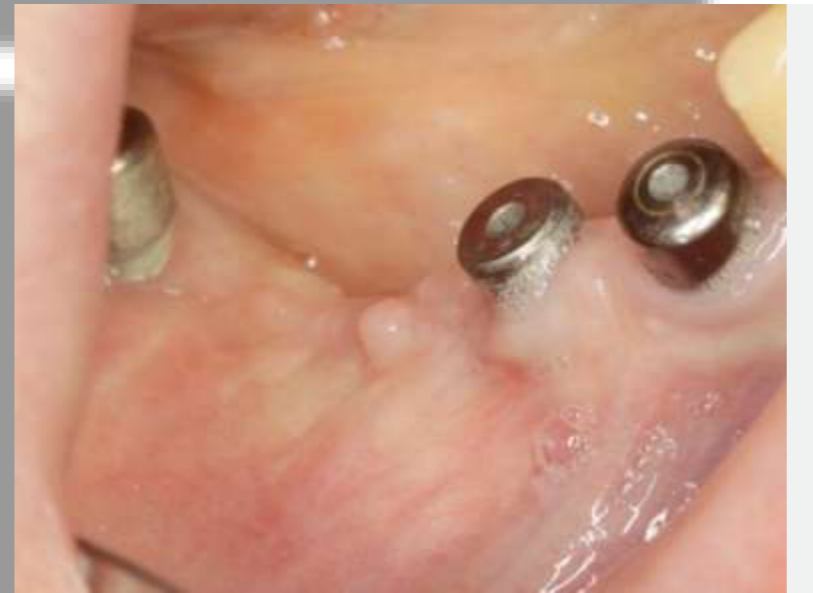
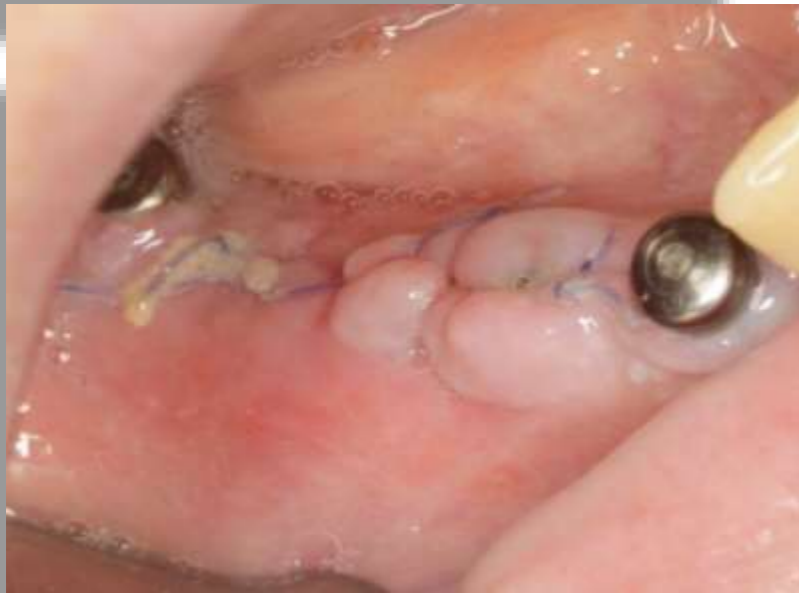
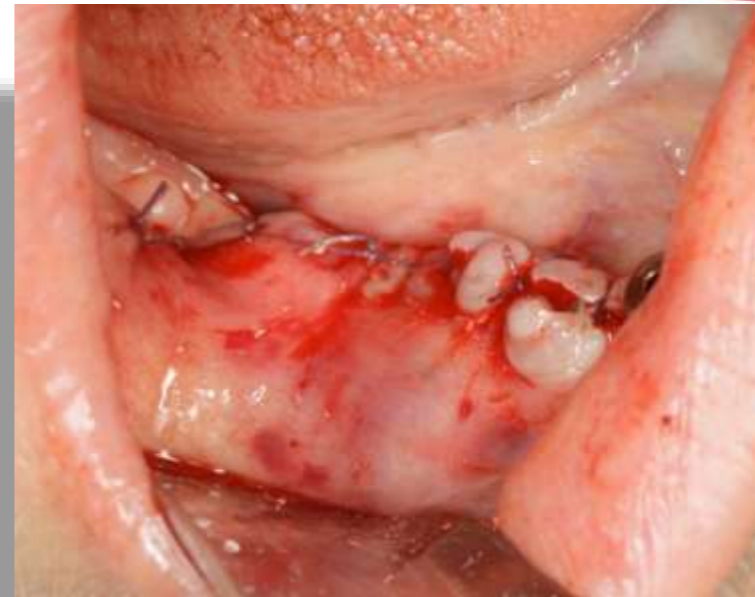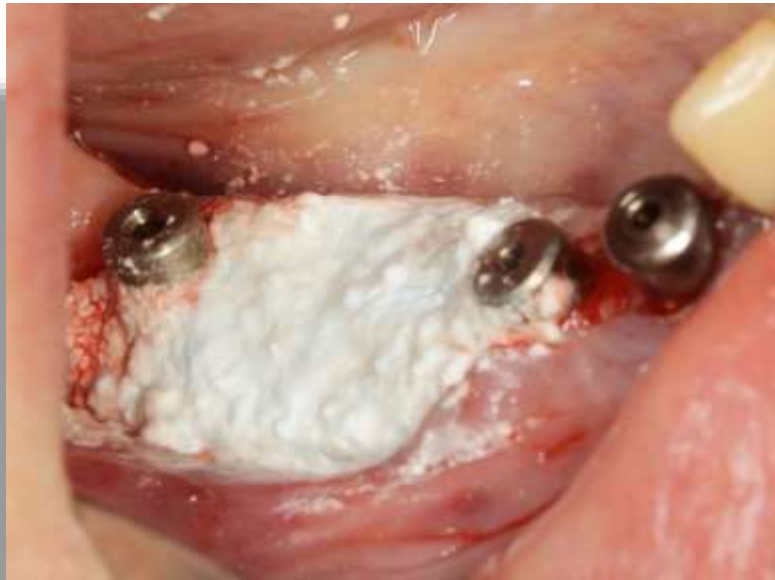Defect after debridement



Defect after debridement

# Bond apatite<sup>®</sup> application

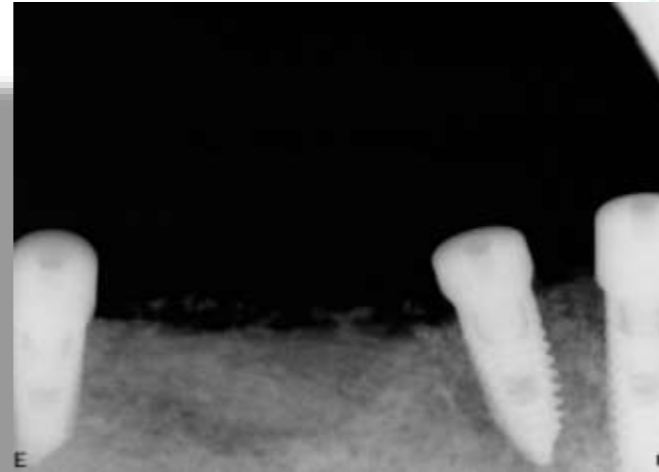
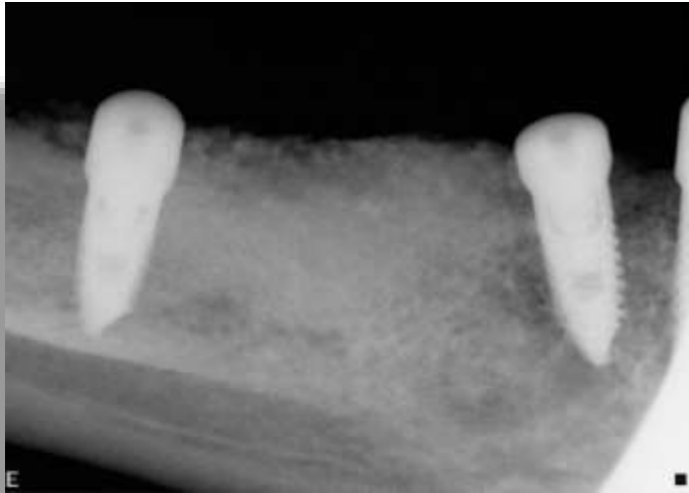


soft tissue appearance 7days post op

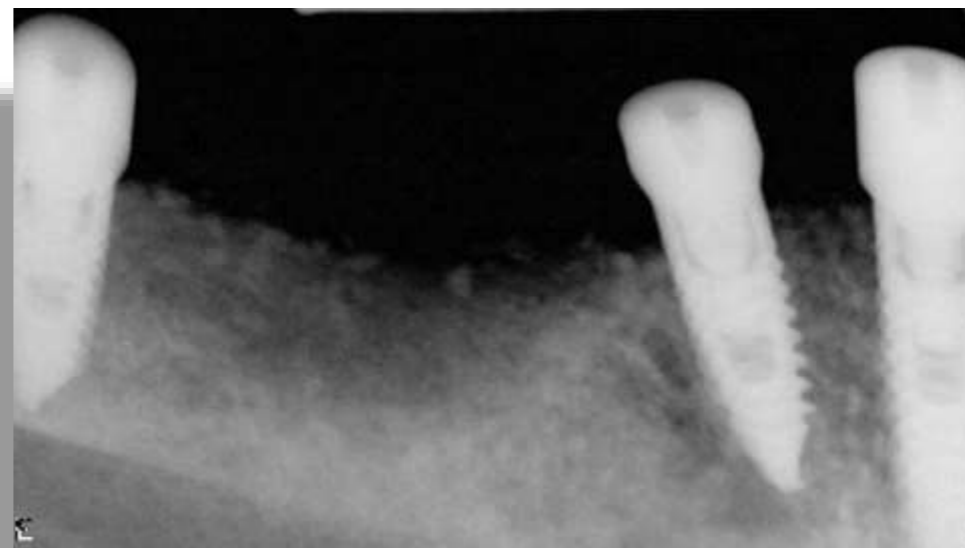
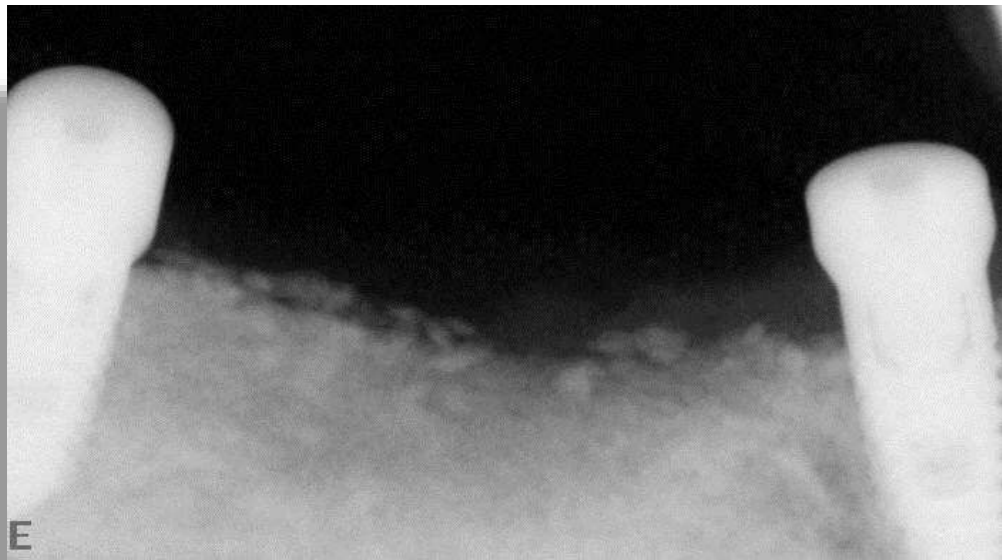
soft tissue appearance 12weeks post op




Day 1 after extractions, implants 43 44 48 were placed  
augmentation in 46 47 area with bond apatite®



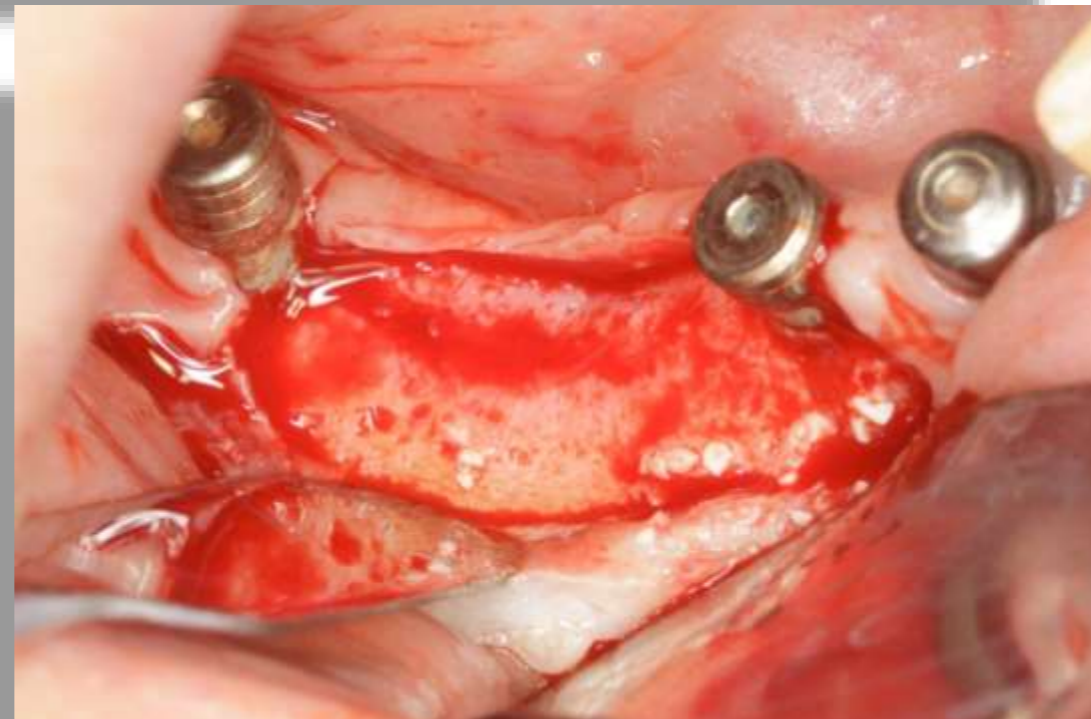
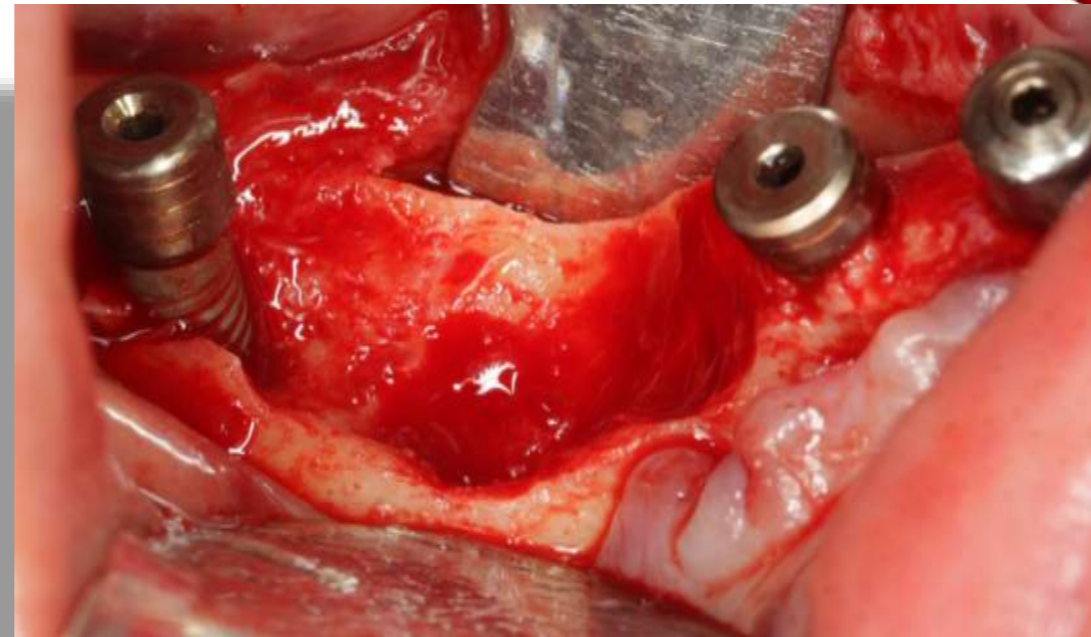
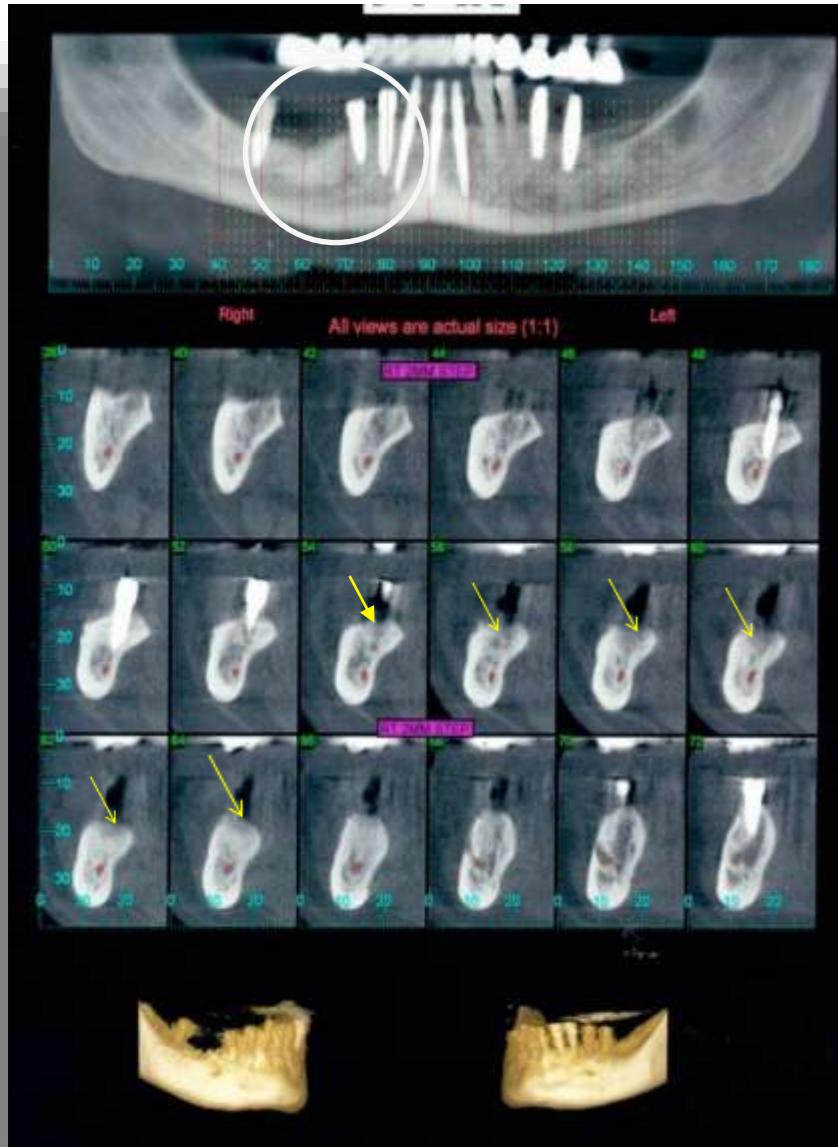11days post op degradation of the  
biphasic calcium sulfate matrix can be seen



11 weeks post op from 2 different angles radiographs. BCS matrix has been replaced  
while particles of HA are incorporated within the matrix replaced by new  
mineralized osteoid matrix



Day 1



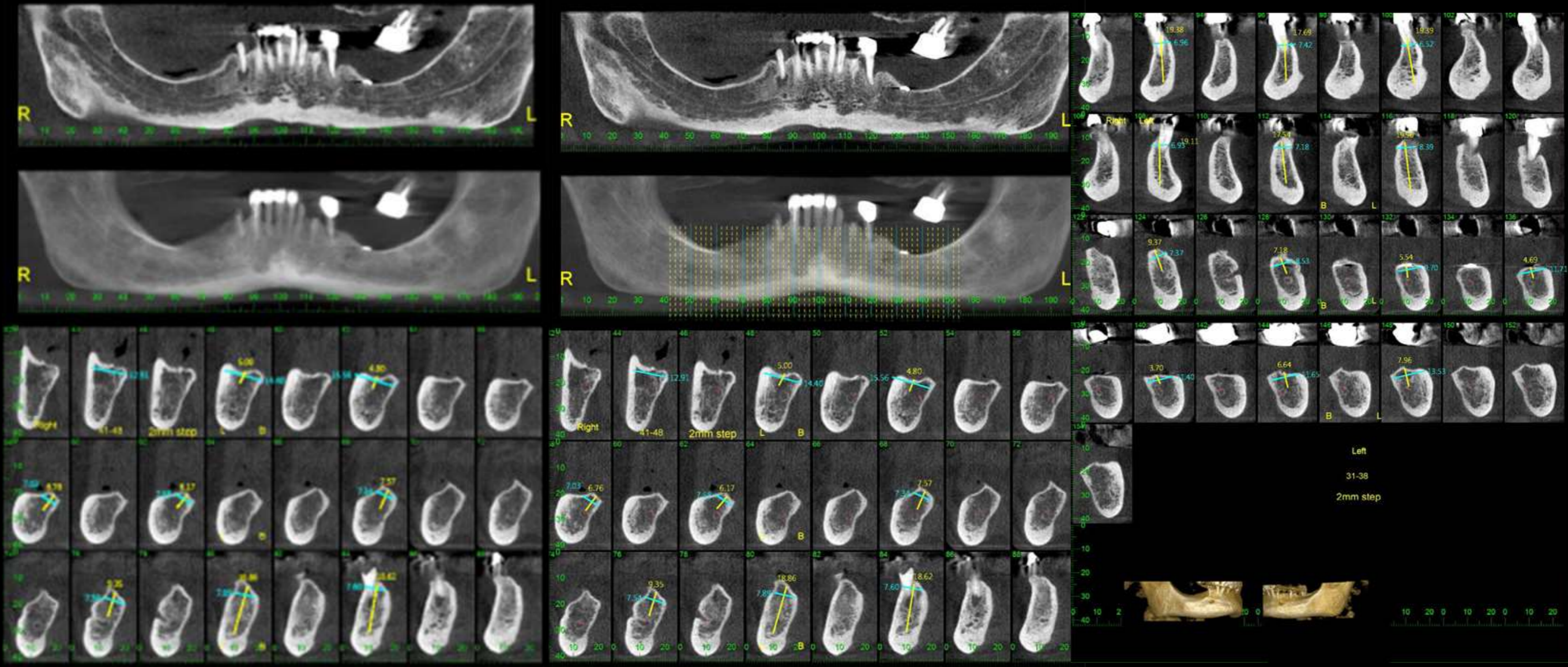
Reentry 22 weeks post op

22 weeks post op bone formation clinically and radiography

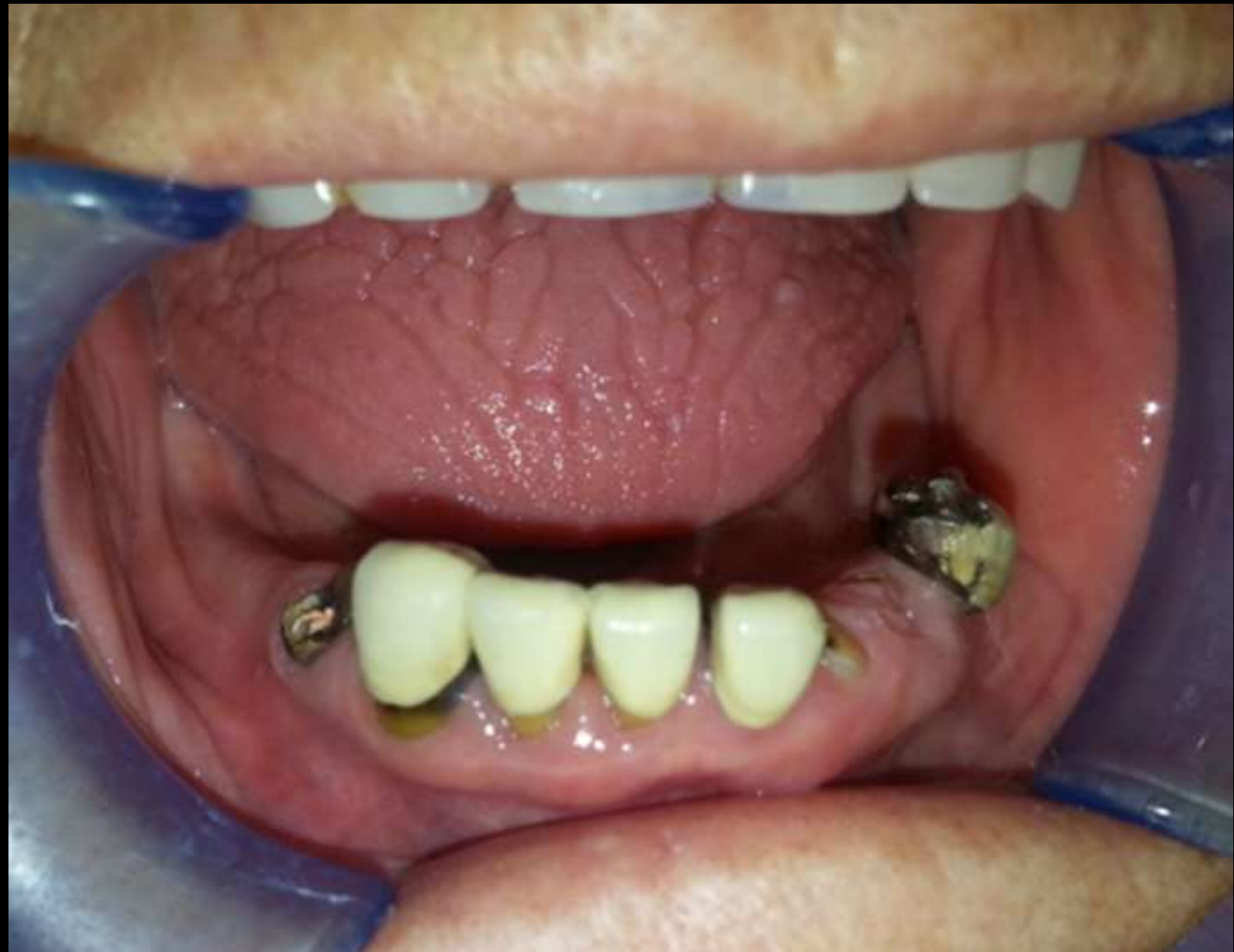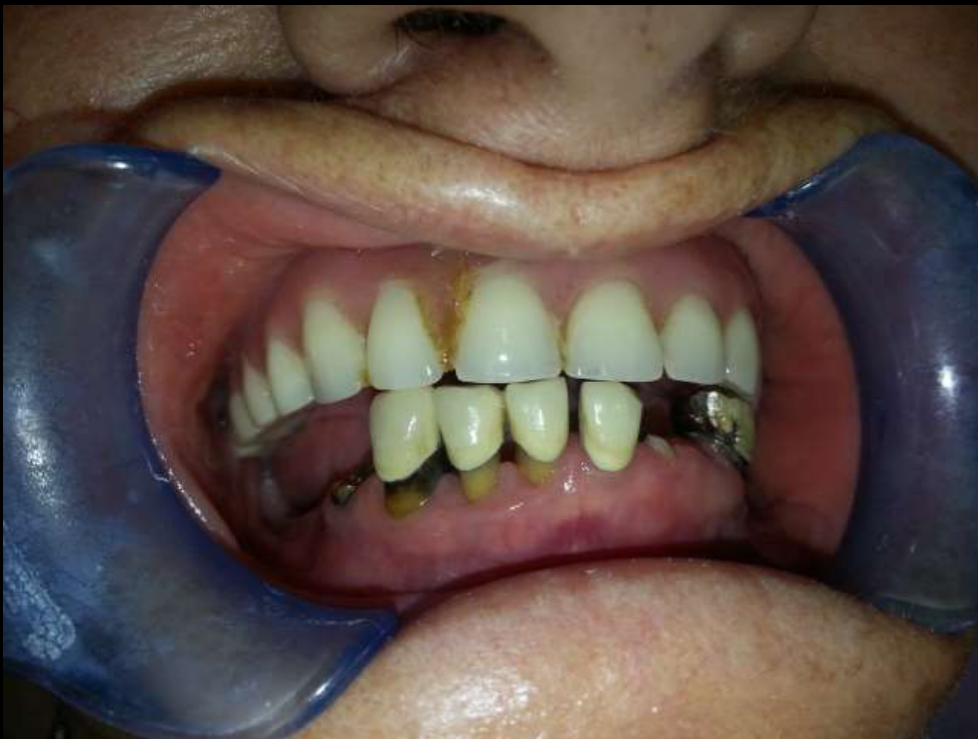**Bond Apatite<sup>®</sup>**  
Bone Graft Cement

**Augma**  
BIOMATERIALS

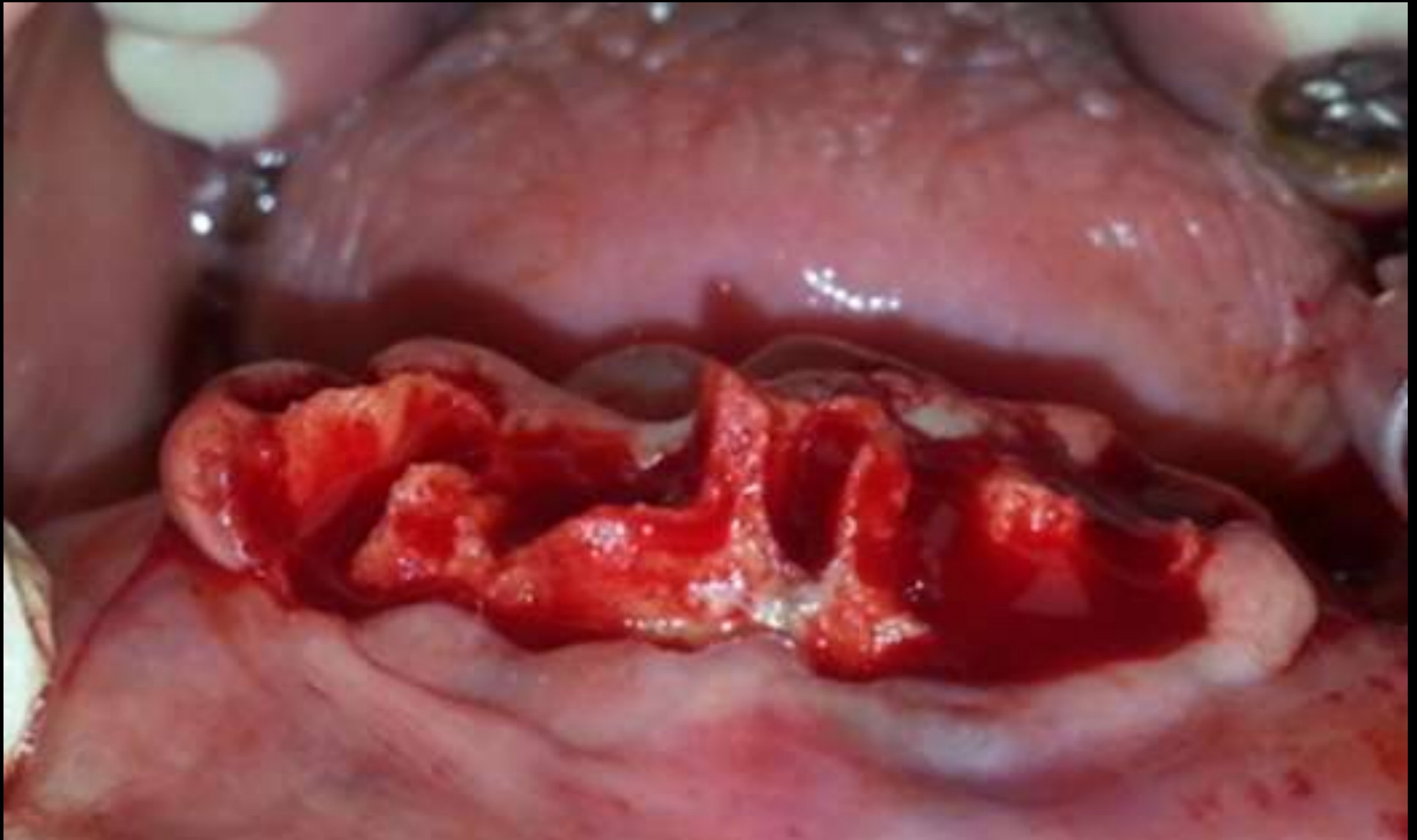
# Con-beam computed tomography taken at the initial consultation



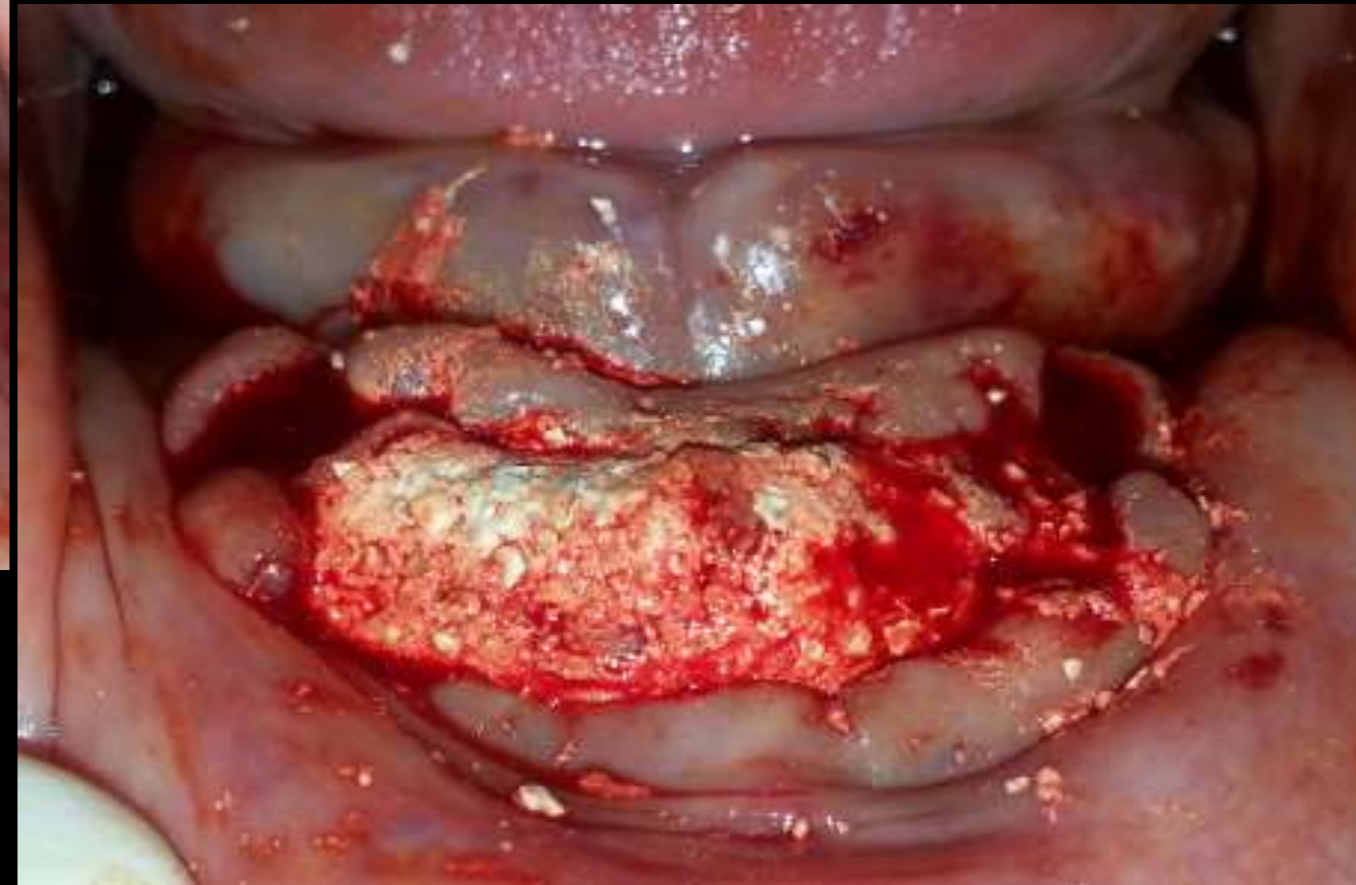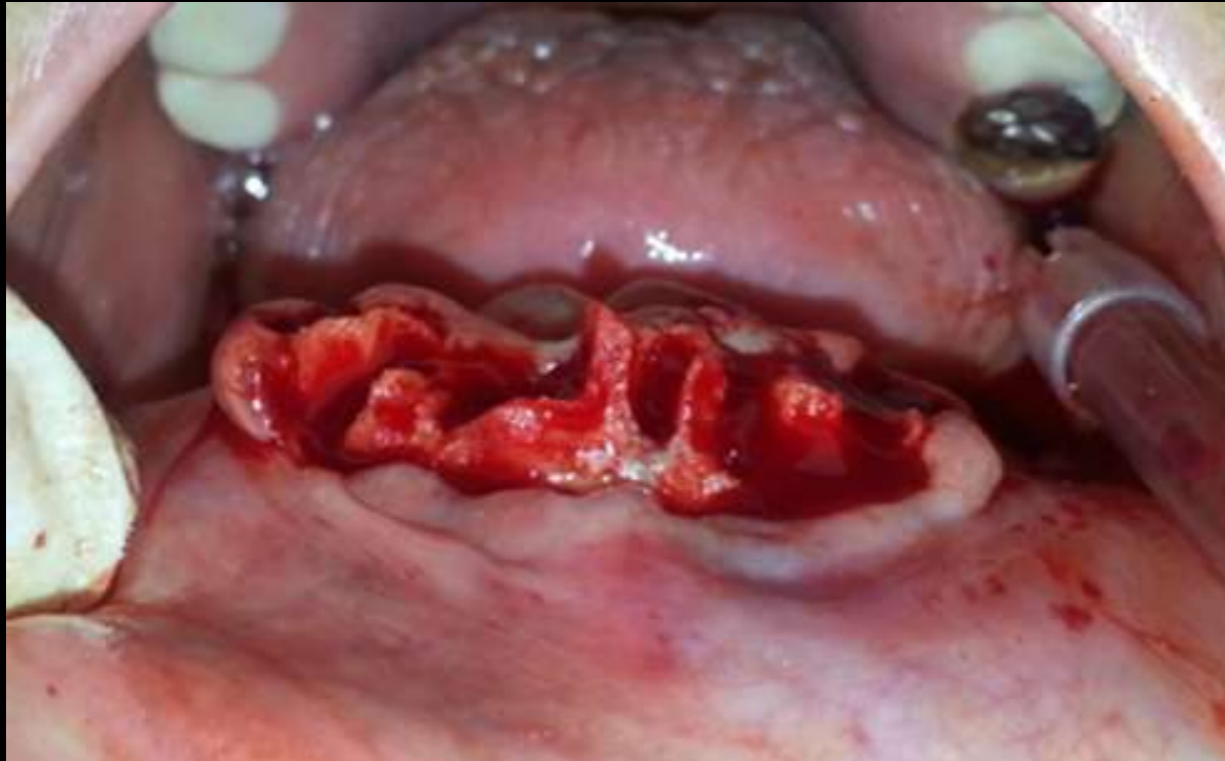# *Preoperative condition of existing teeth*



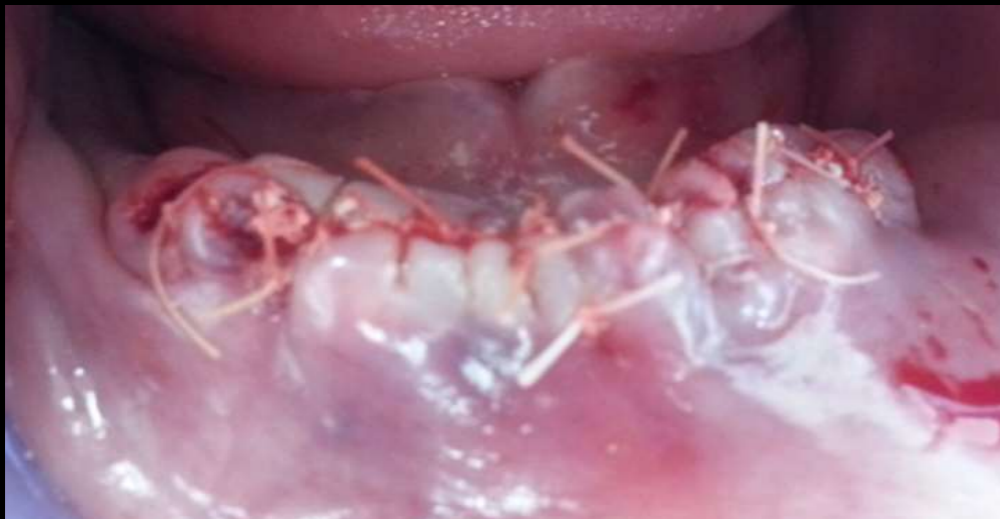*Extraction of all teeth  
a deformed and irregular crest can be seen*



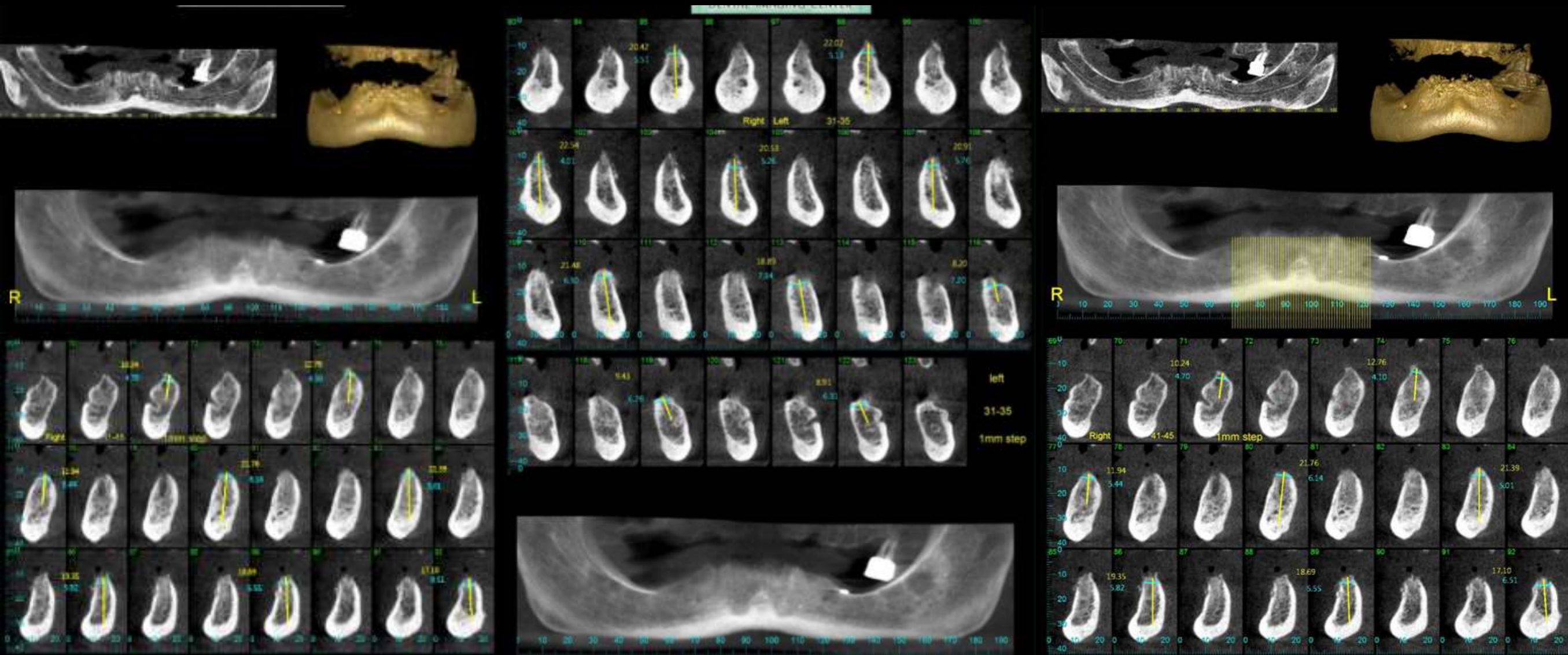
*Application of Bond apatite®  
Augma-biomaterials”  
bone substitute*



primary closure with vicryl sutures 4/00

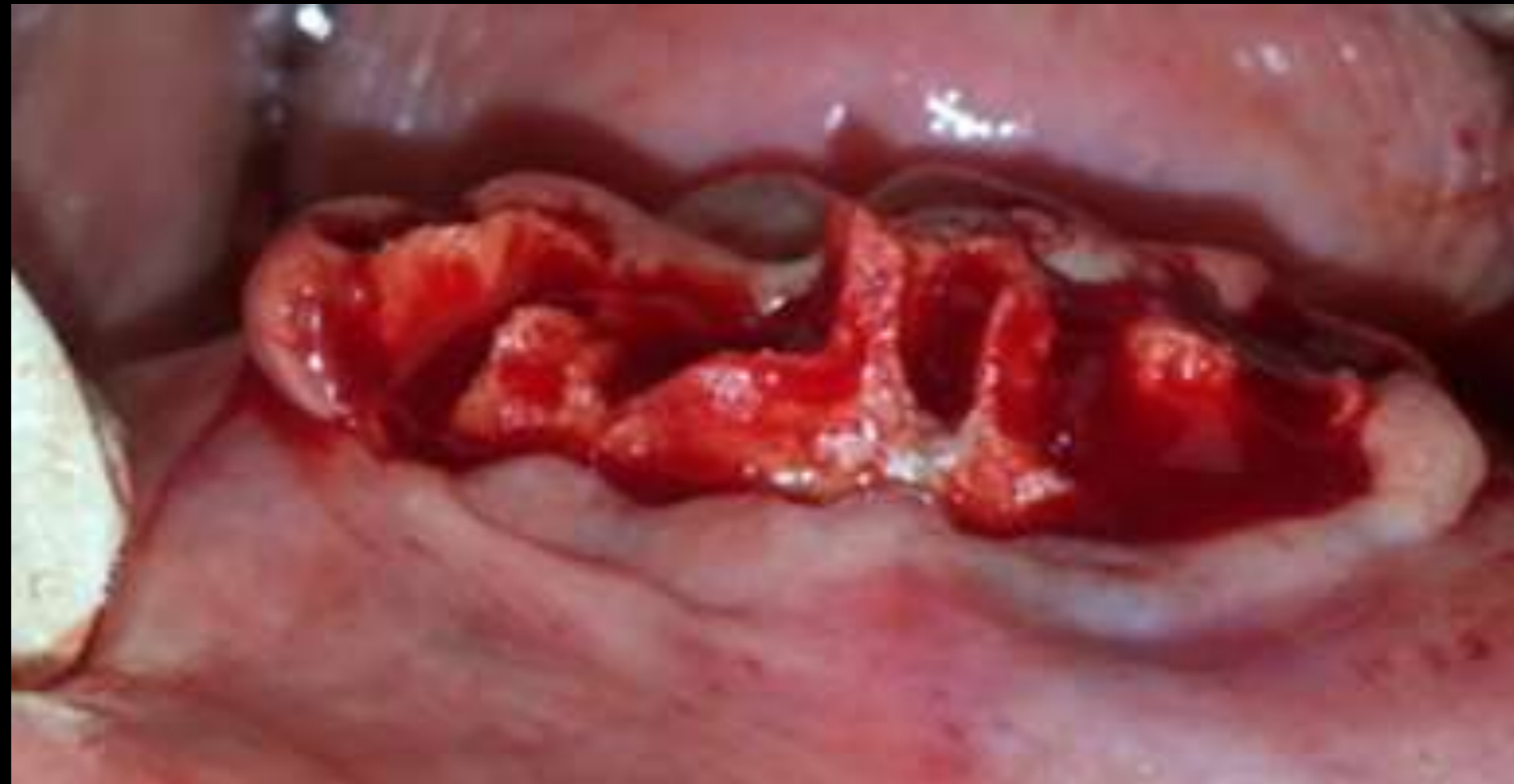

# CBCT 4.5m AFTER EXTRACTION AND "Bond Apatite ®" APPLICATION

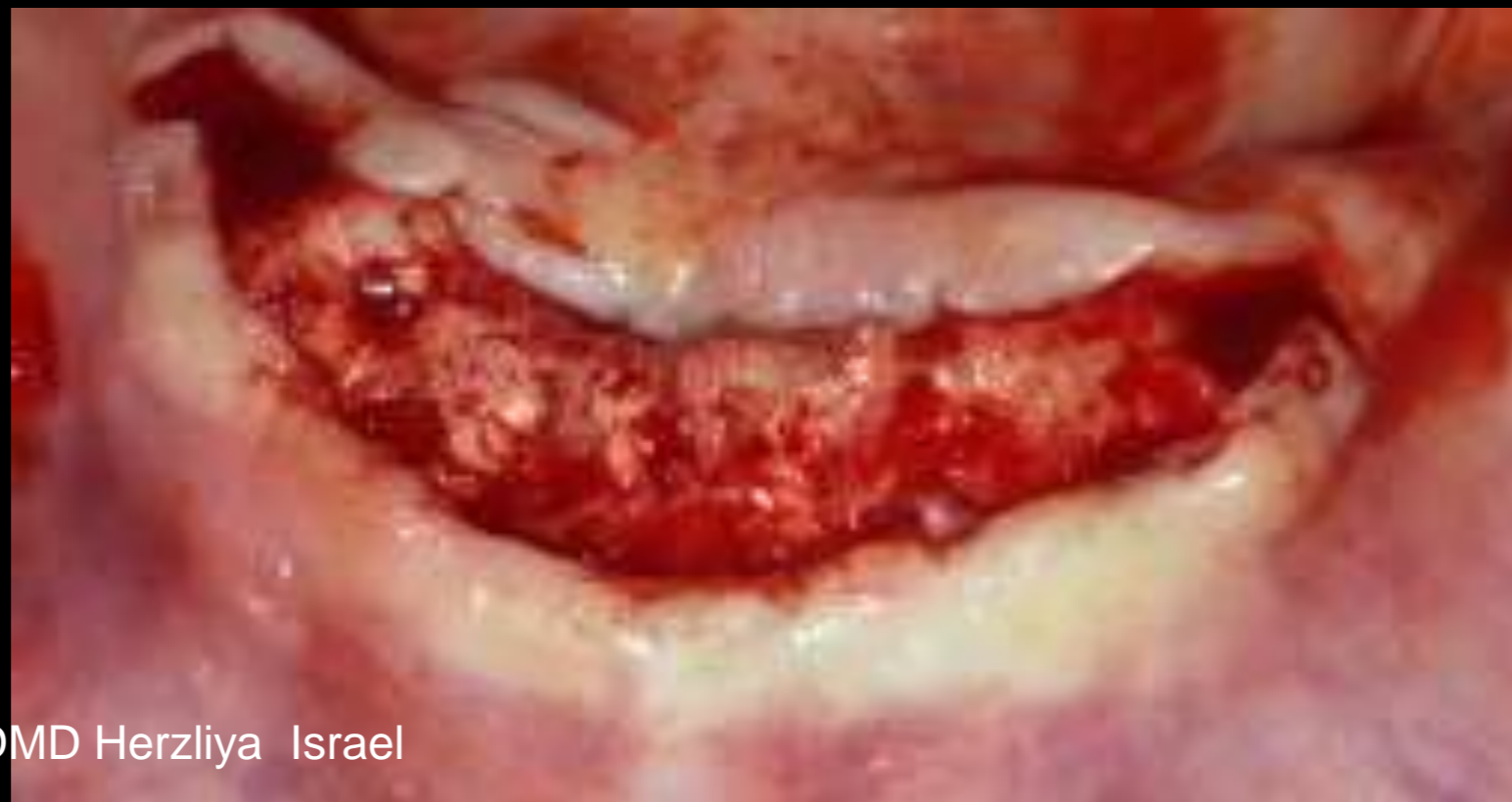

# *Homogenous crest formation*

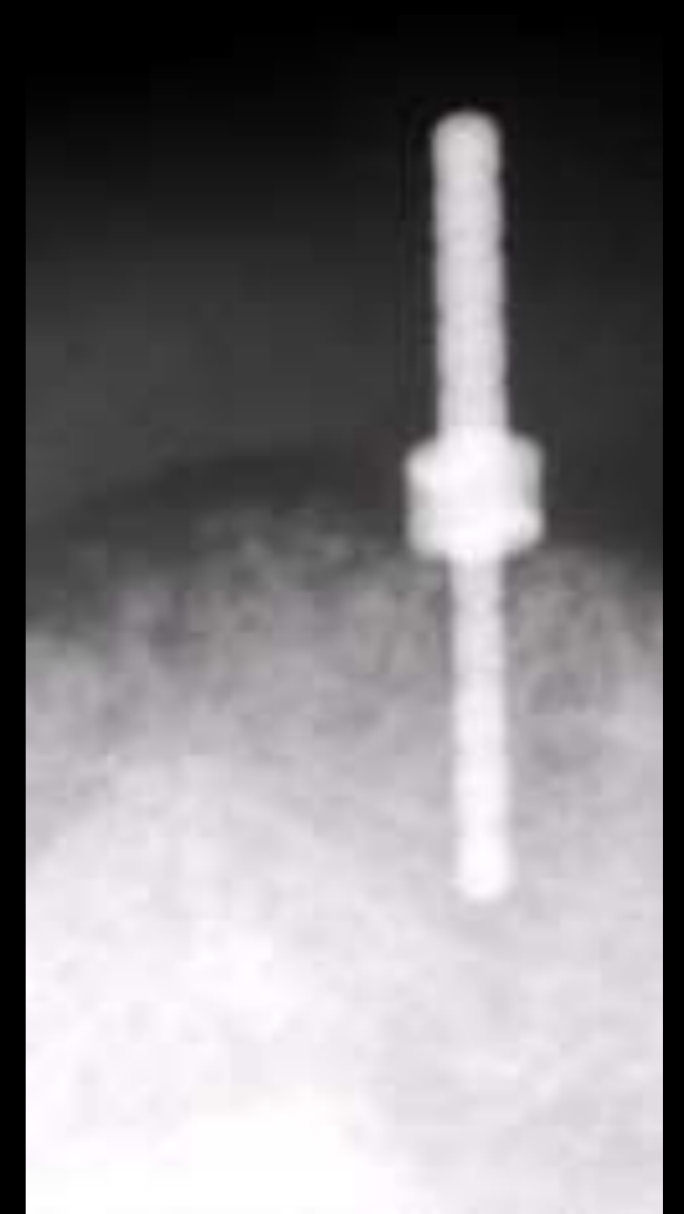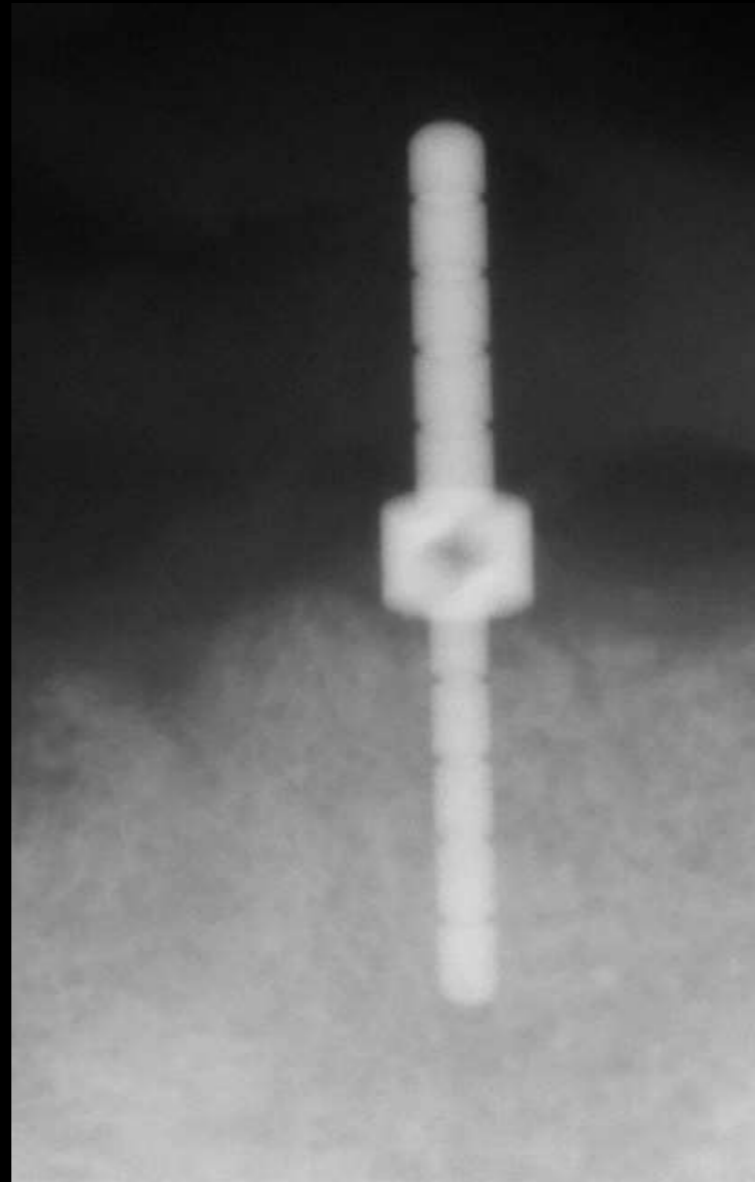
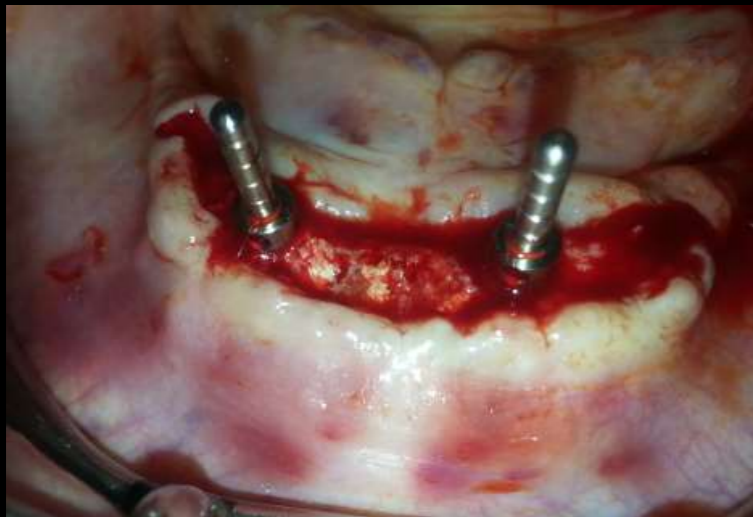Before



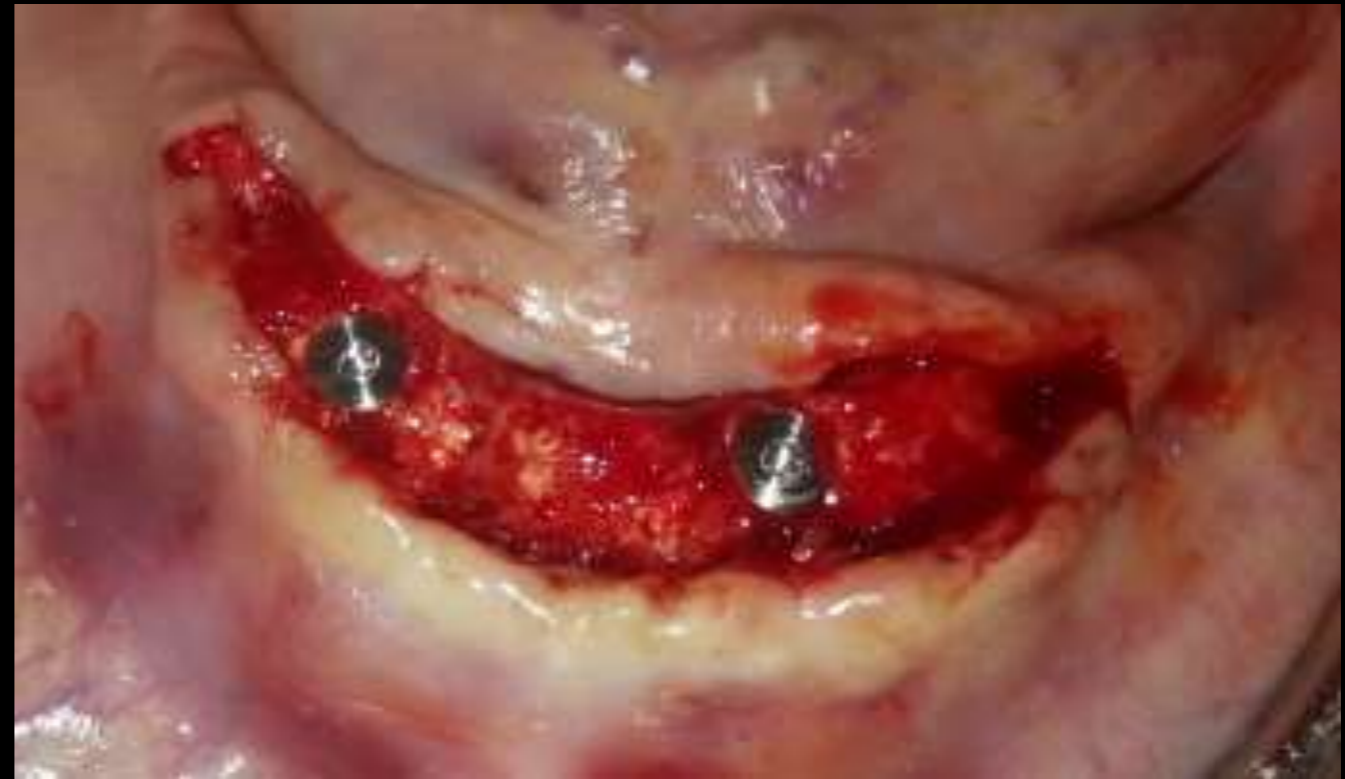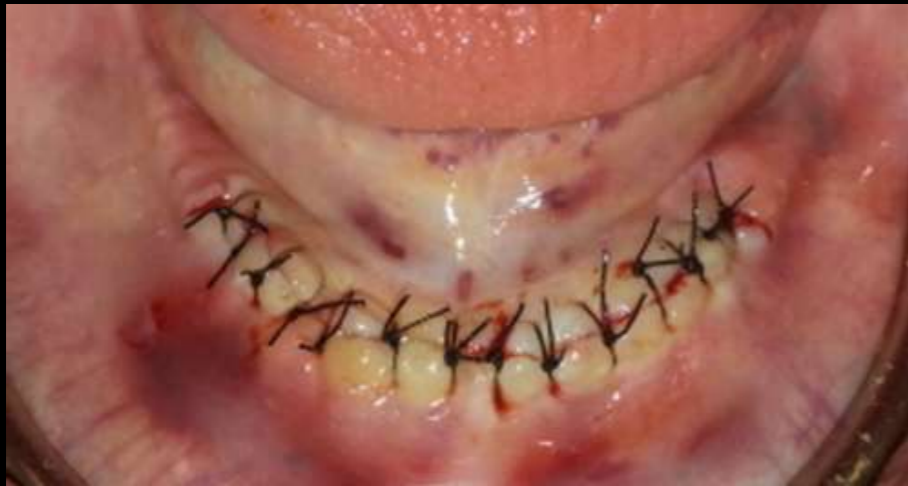After



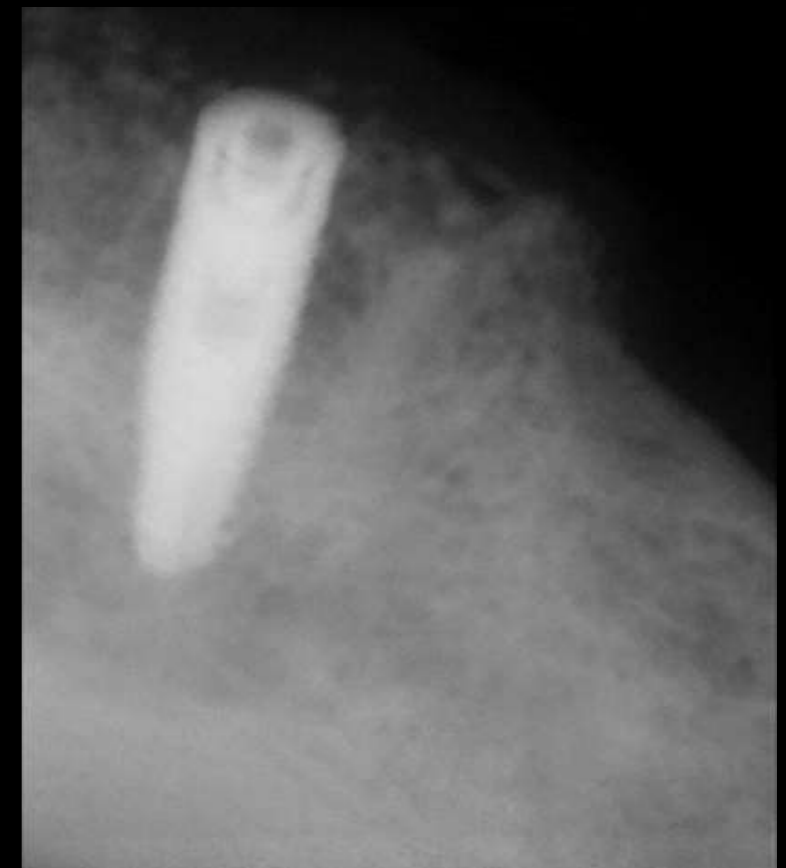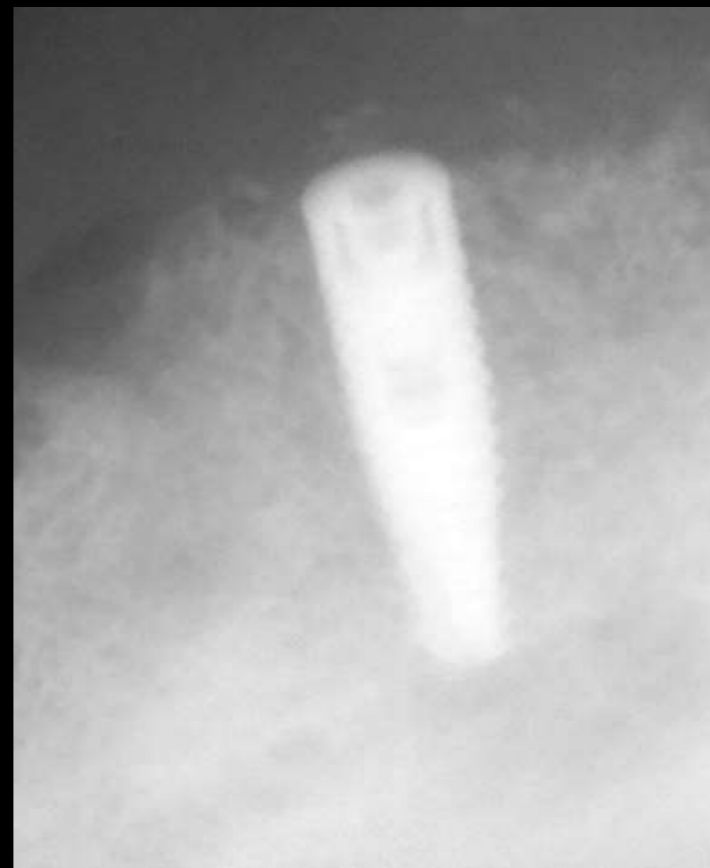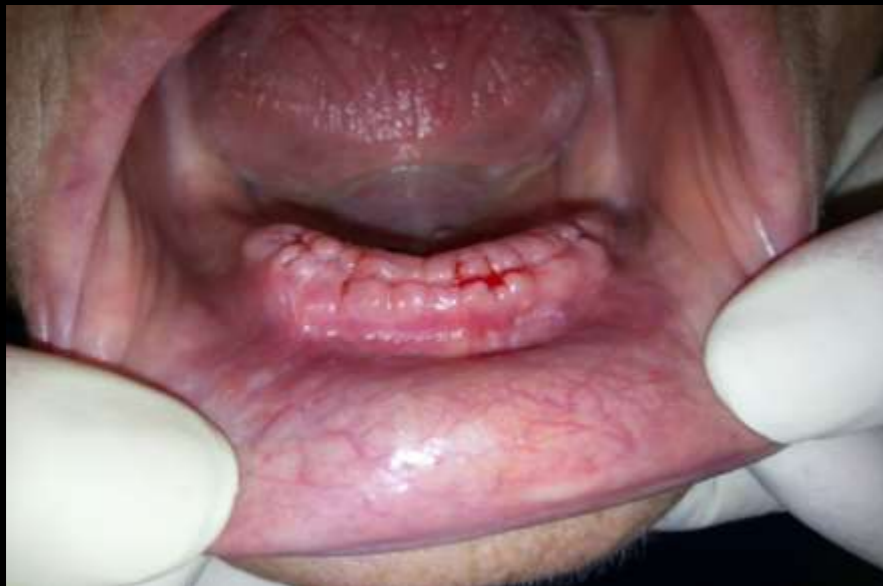*Initial parallel pins established the location for the osteotomies*



*Implants insertion ( Paltop advanced 3.75 / 13 )*

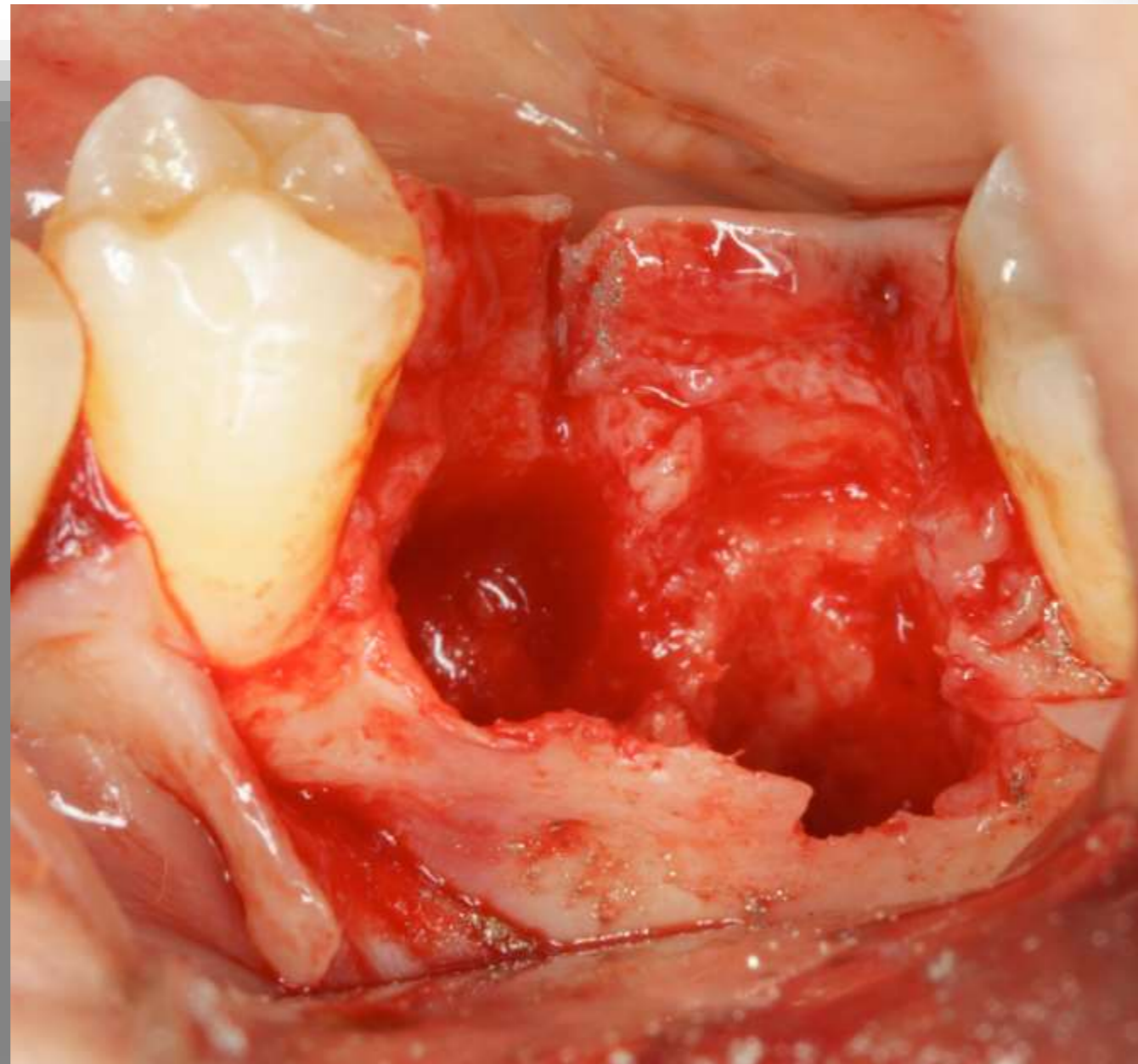
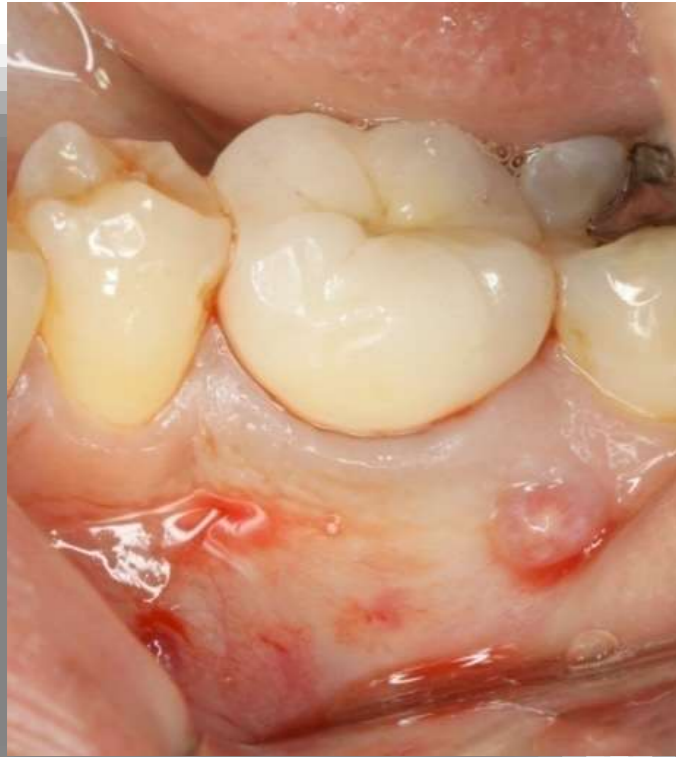

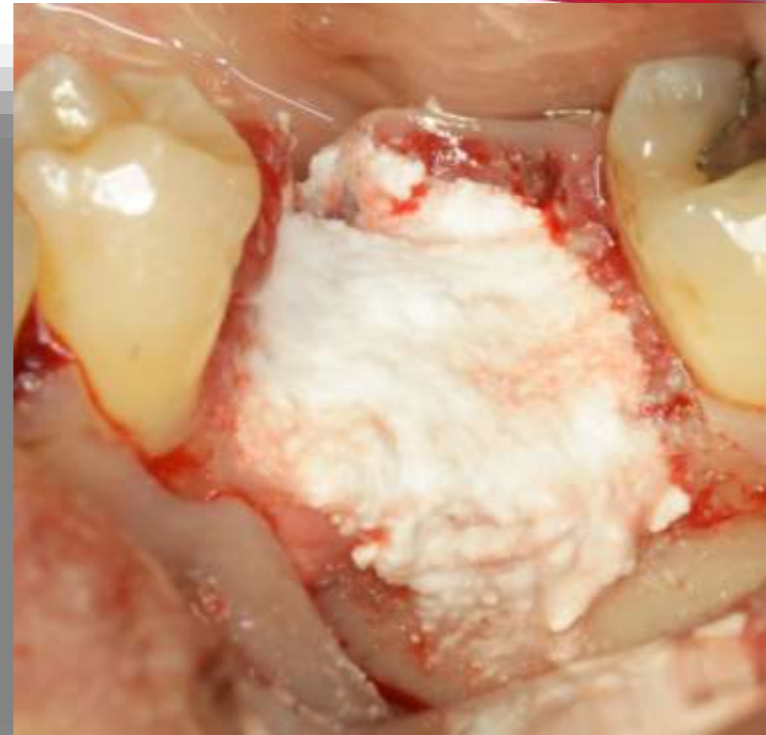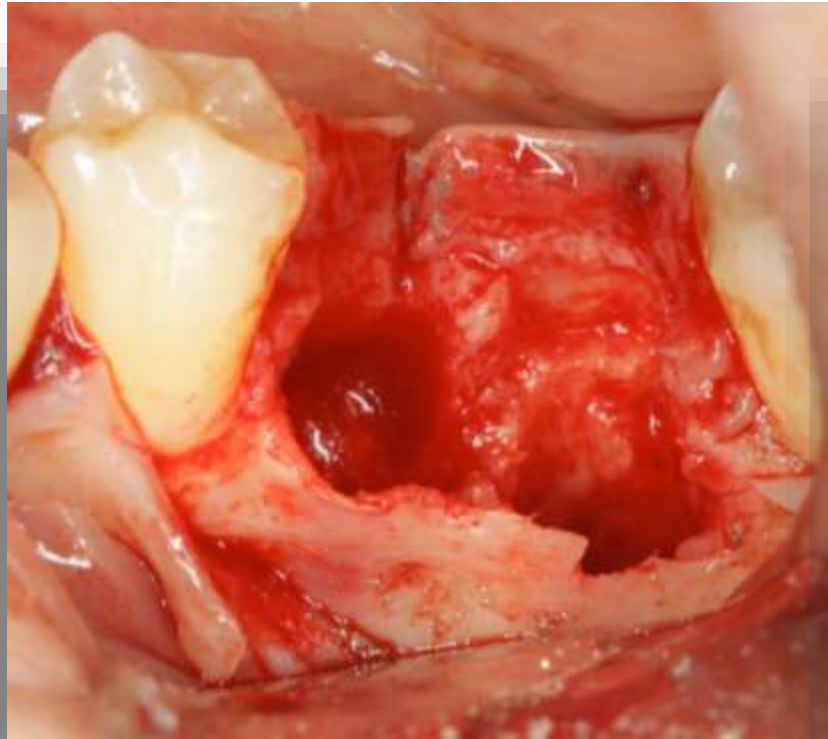
*One week after implants insertion*



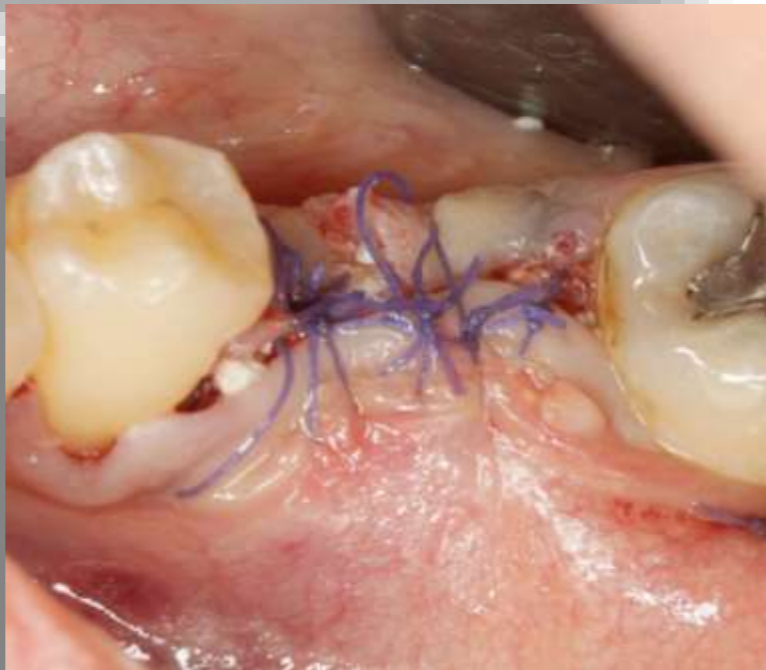
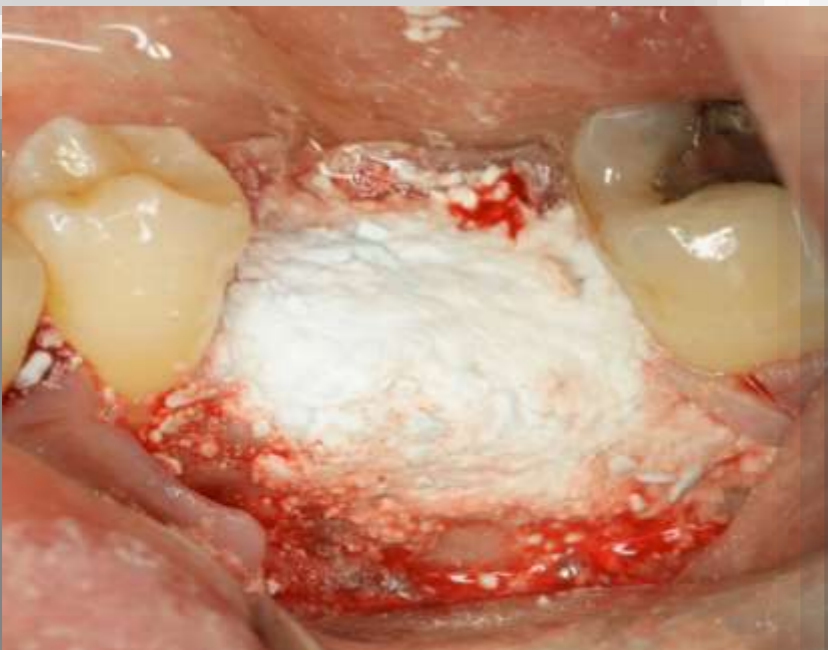
Large bone defect post hopeless tooth extraction



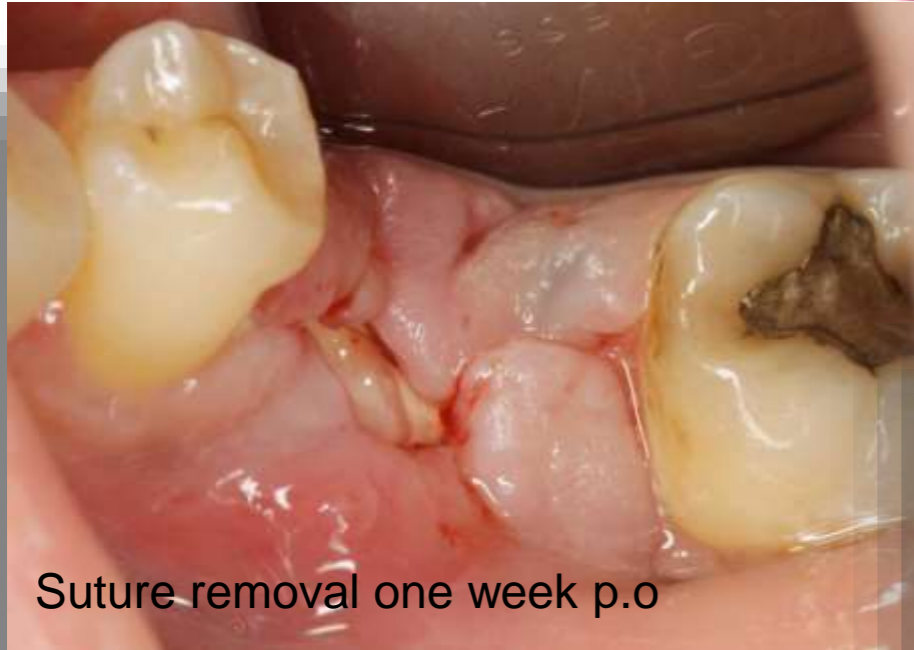

Bond Apatite in place

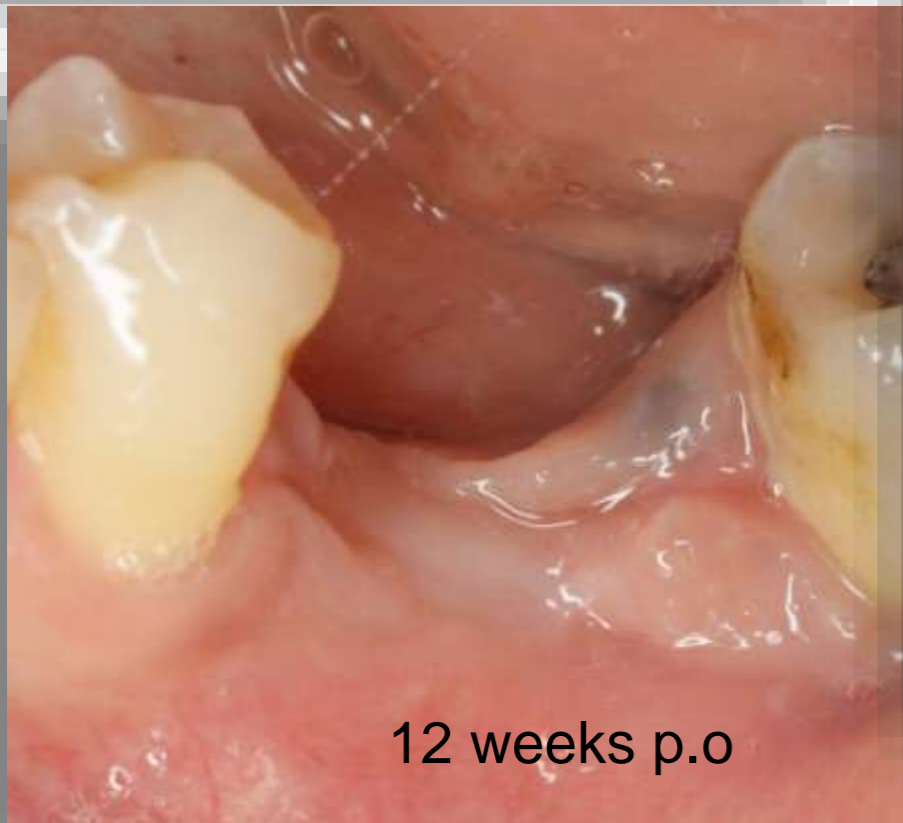
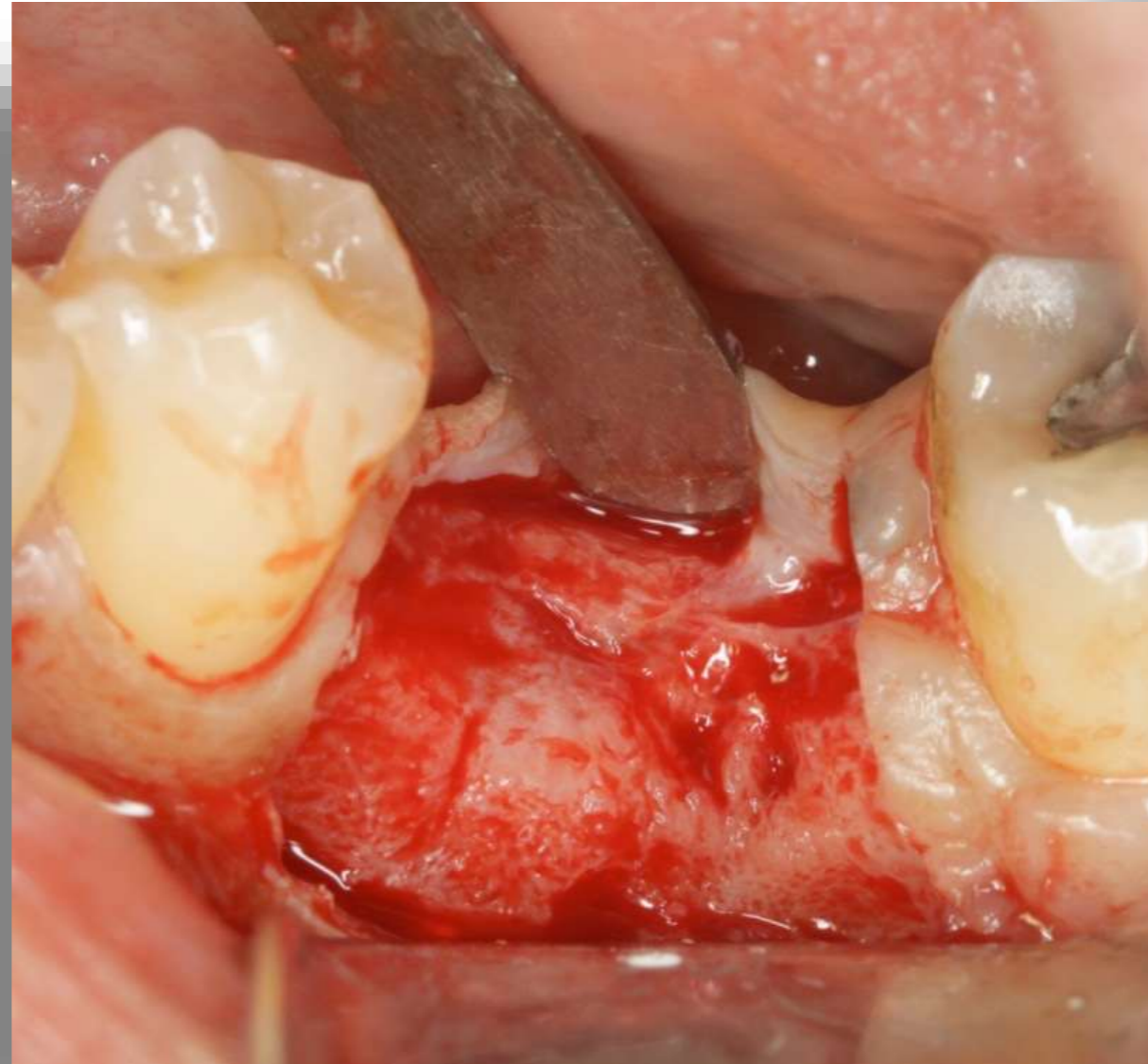
**Bond Apatite**<sup>®</sup>  
Bone Graft Cement

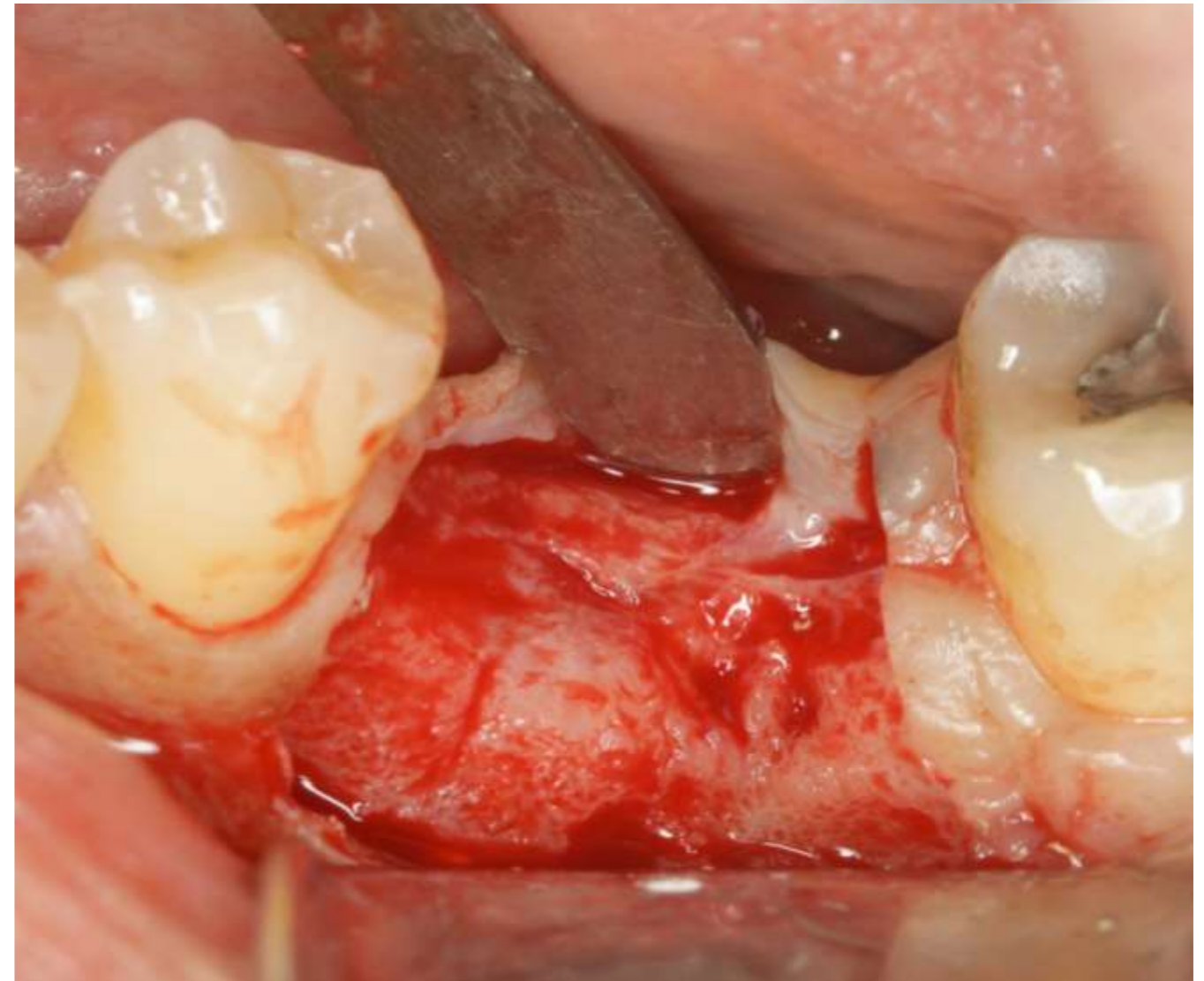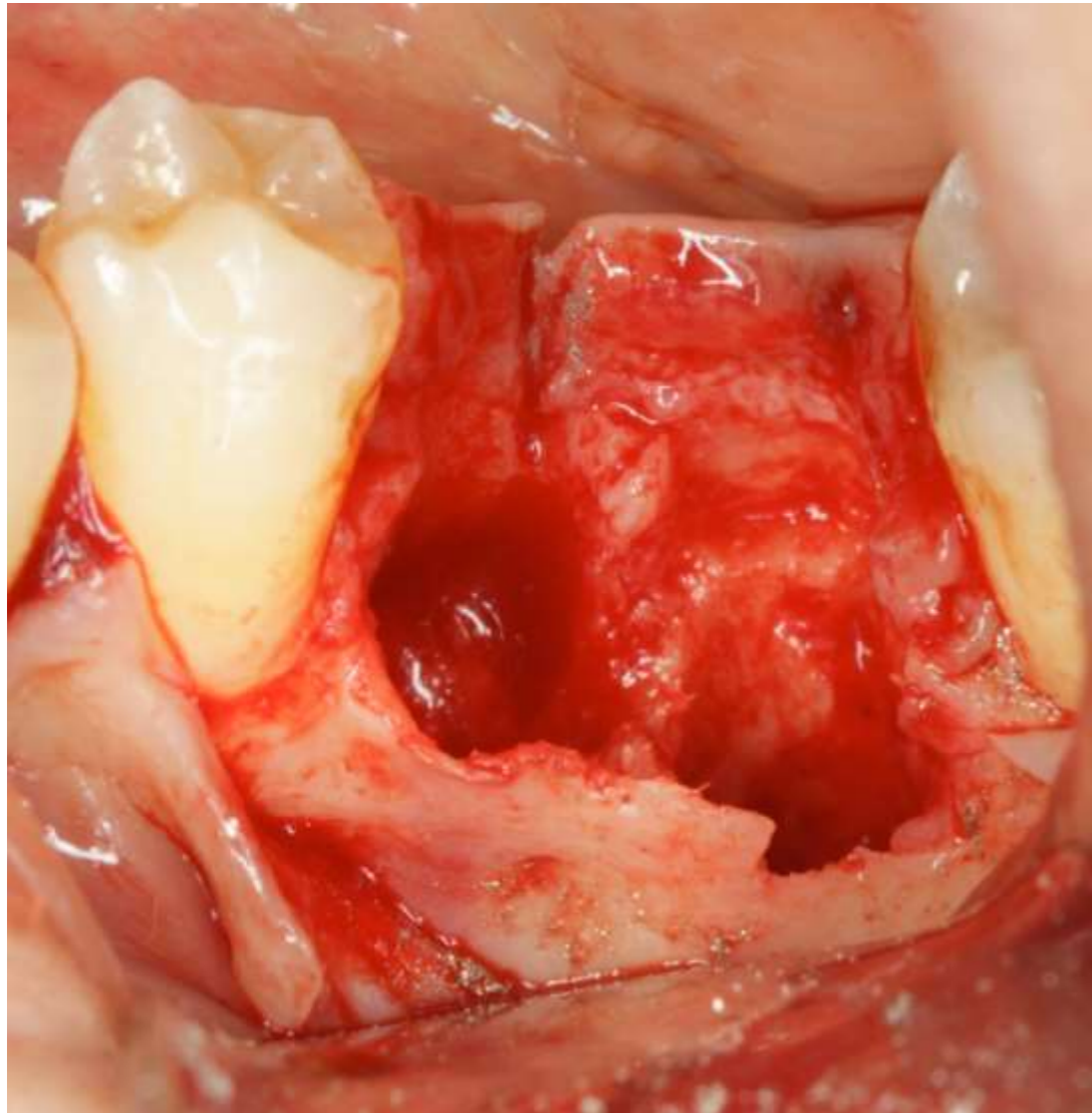

  
**Augma**  
BIOMATERIALS



Suture removal one week p.o

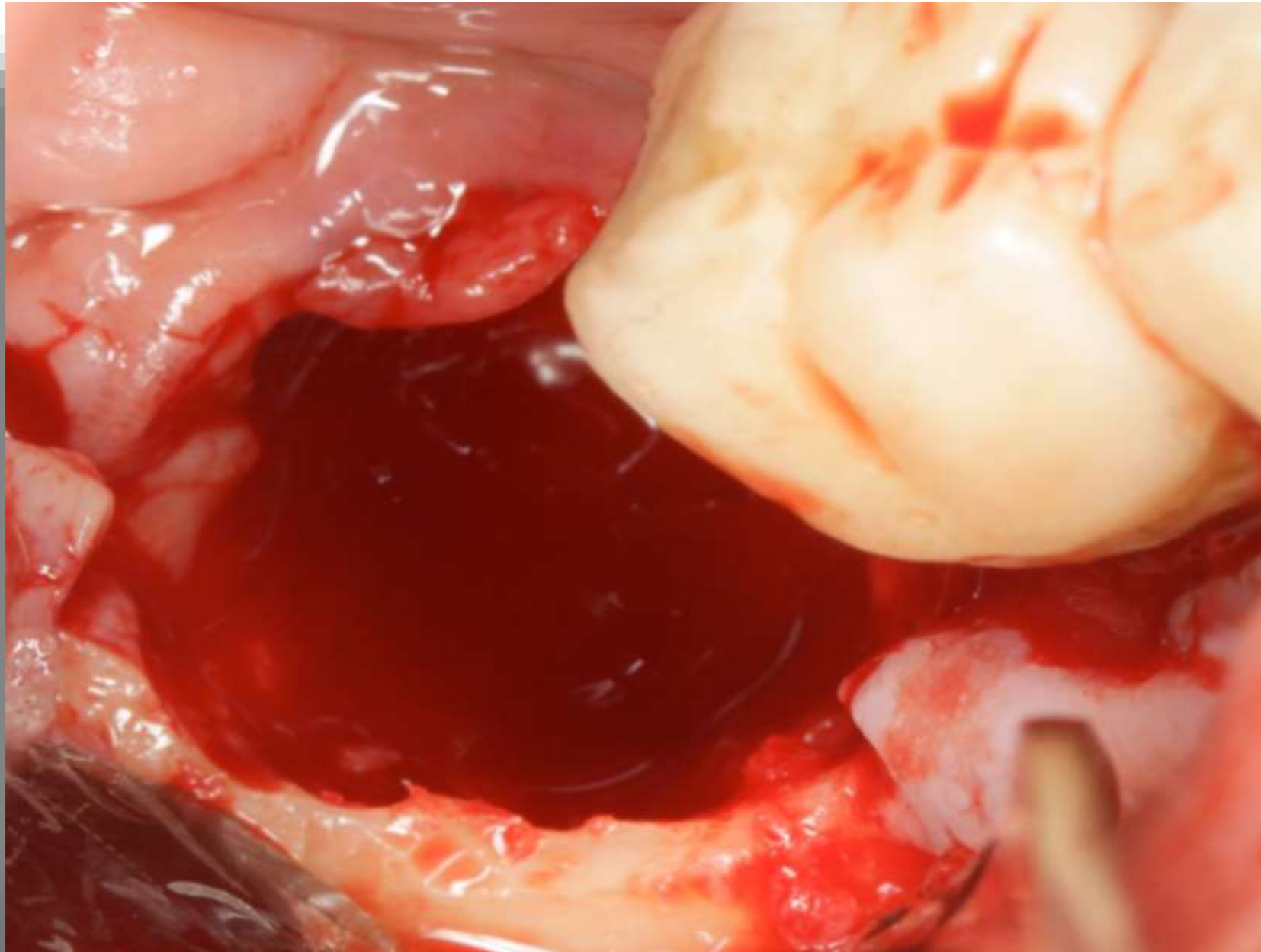


12 weeks p.o



**Bond Apatite<sup>®</sup>**  
Bone Graft Cement

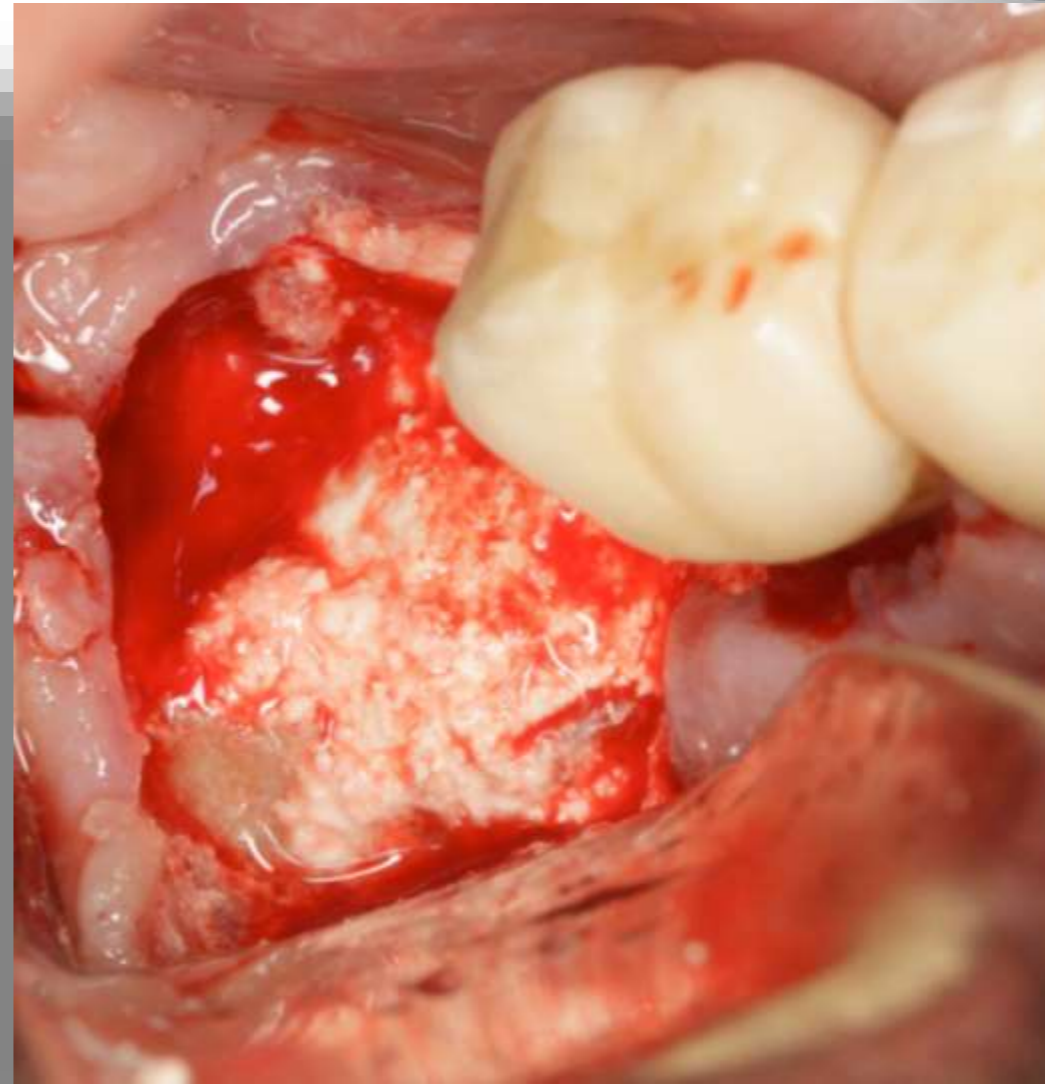
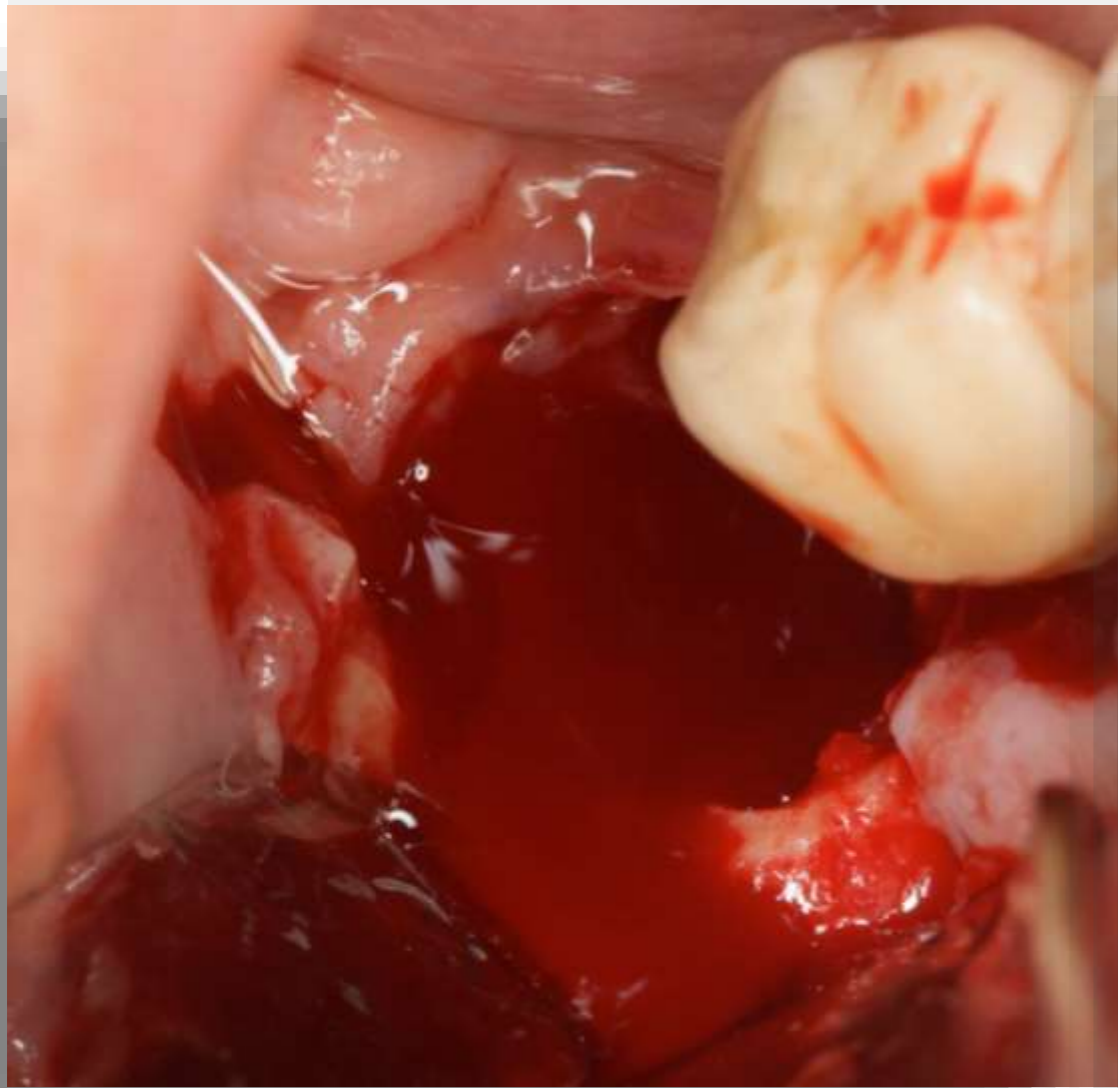

  
**Augma**  
BIOMATERIALS




Before augmentation

**Bond Apatite<sup>®</sup>**  
Bone Graft Cement

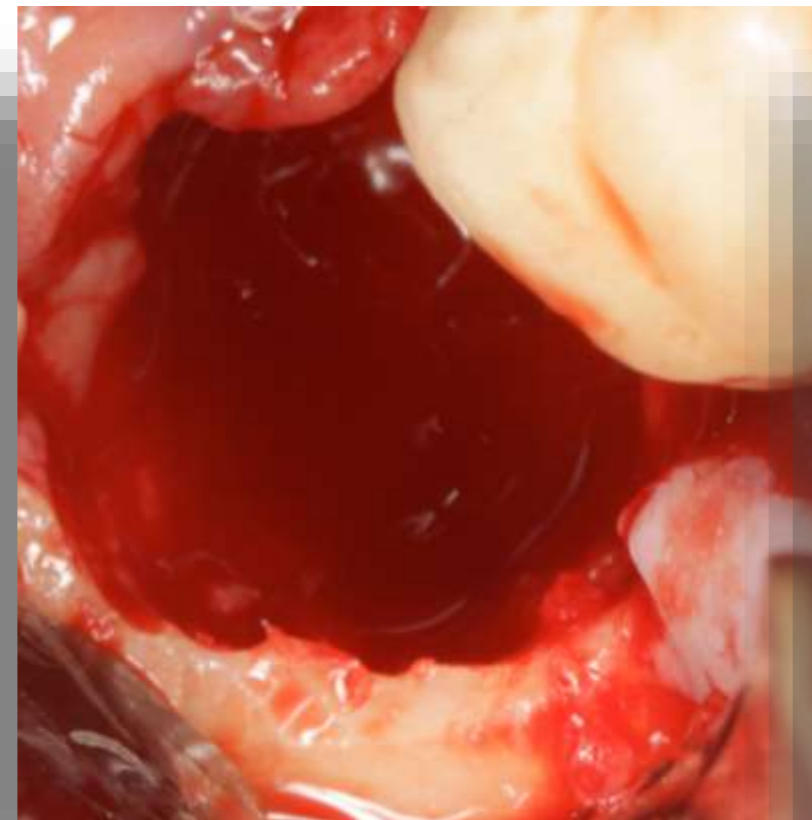
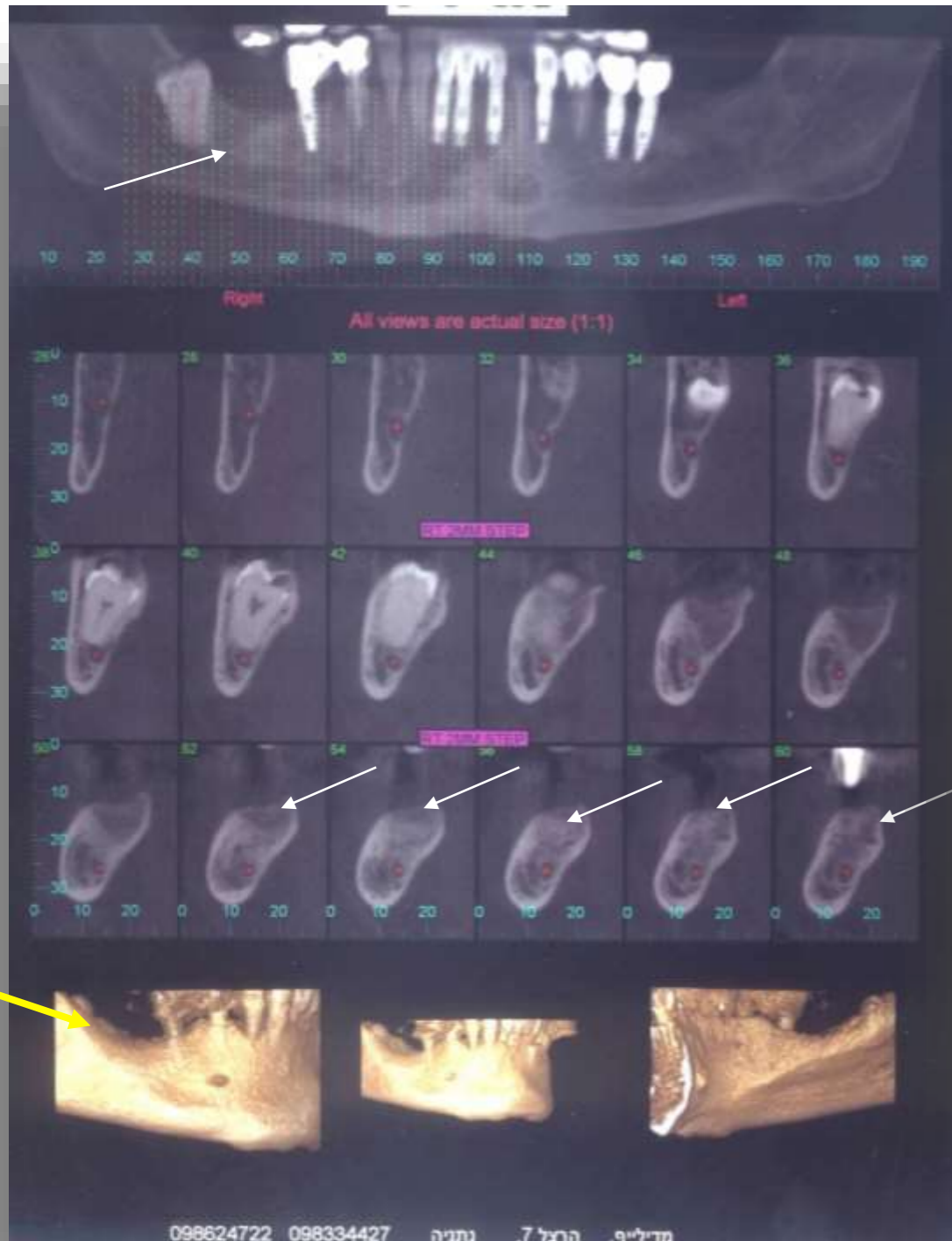  
**Augma**  
BIOMATERIALS



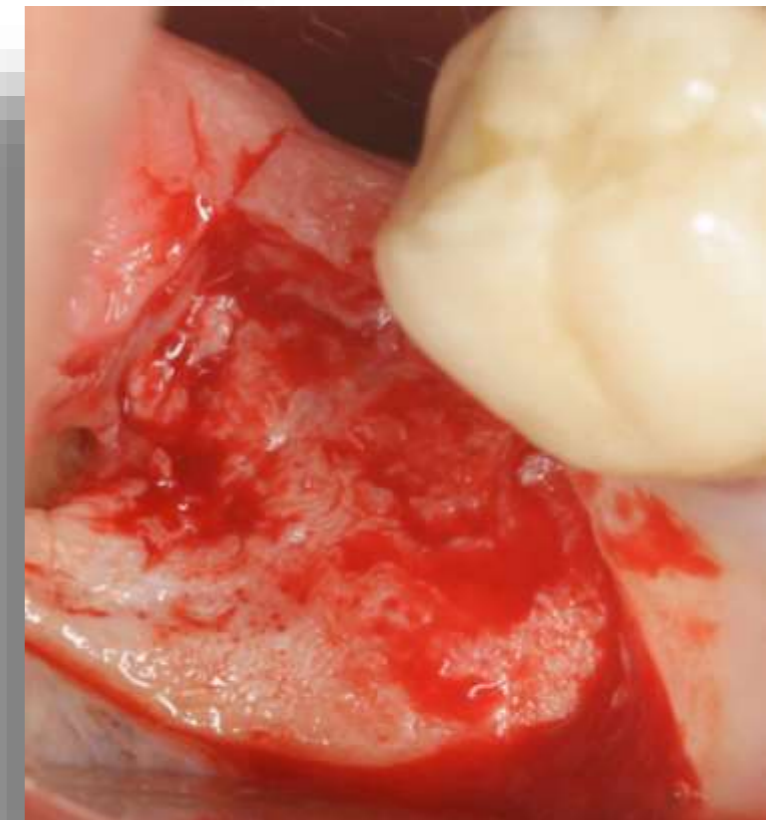
Bond Apatite® in place



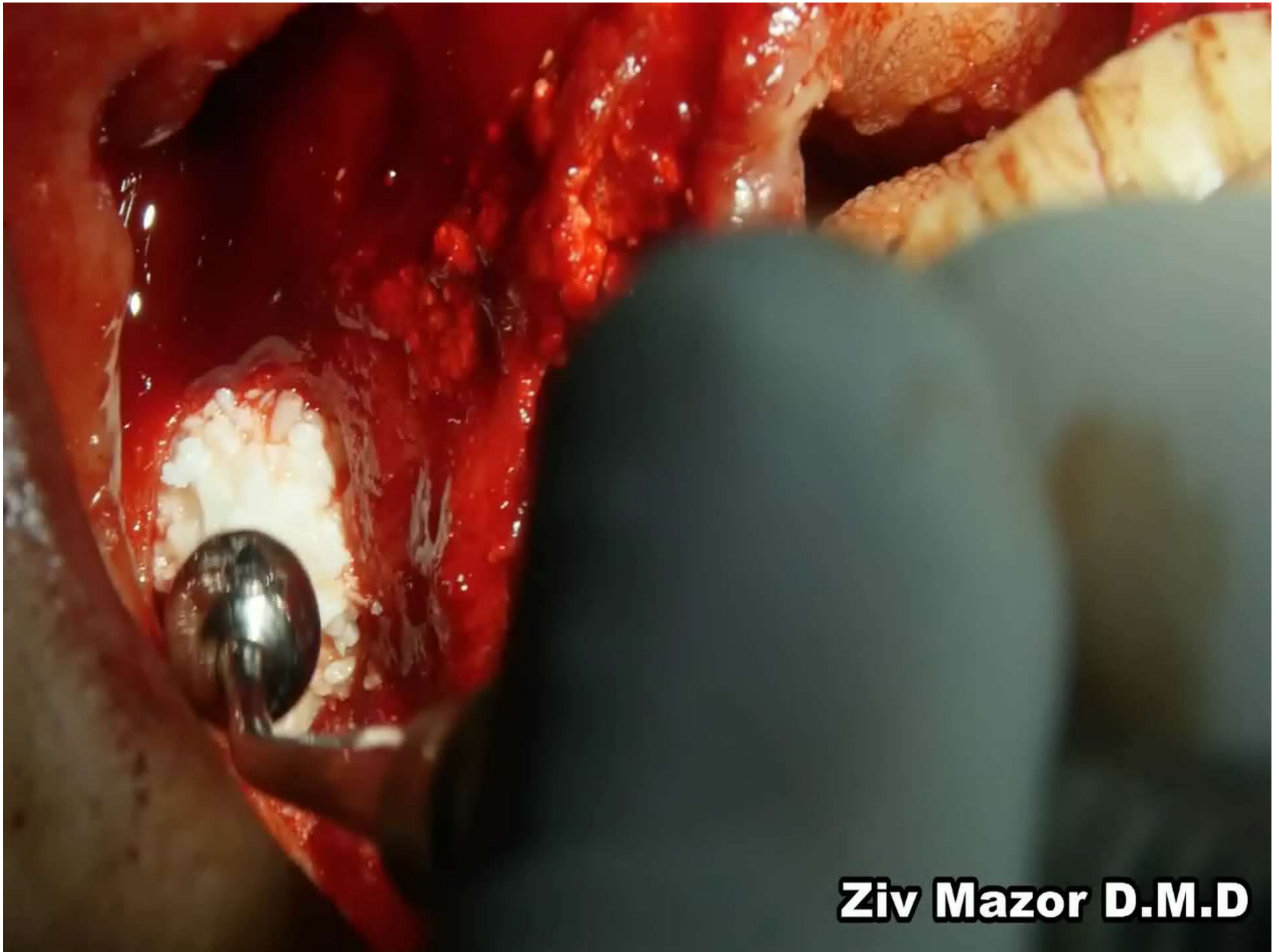
12 weeks post op



Before

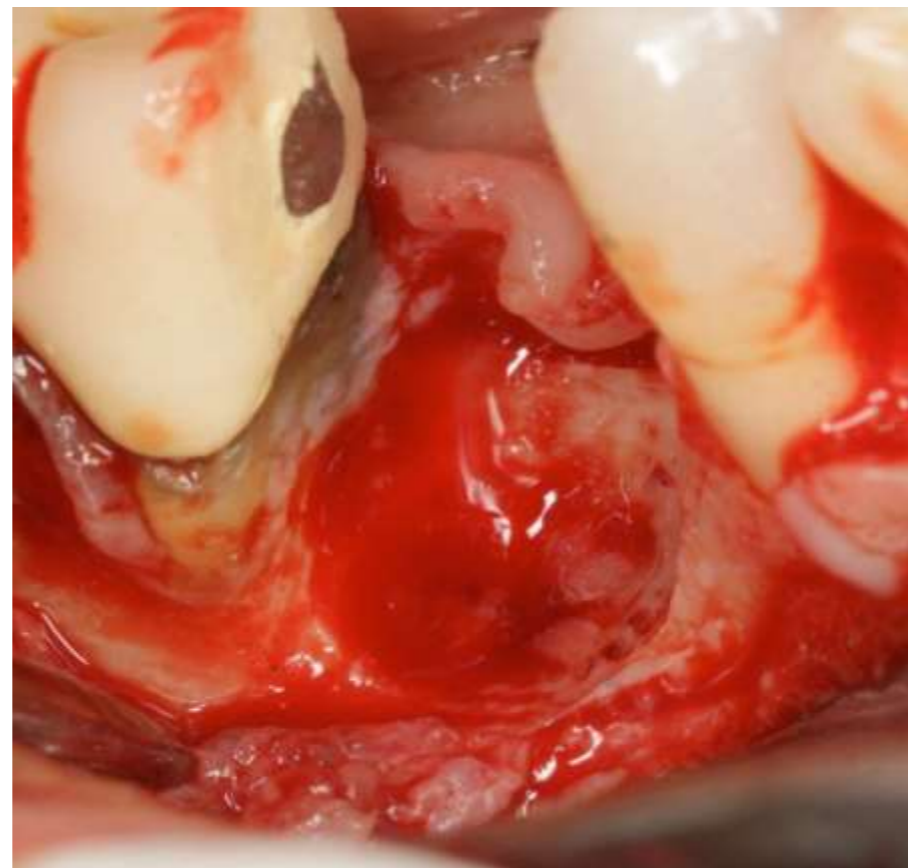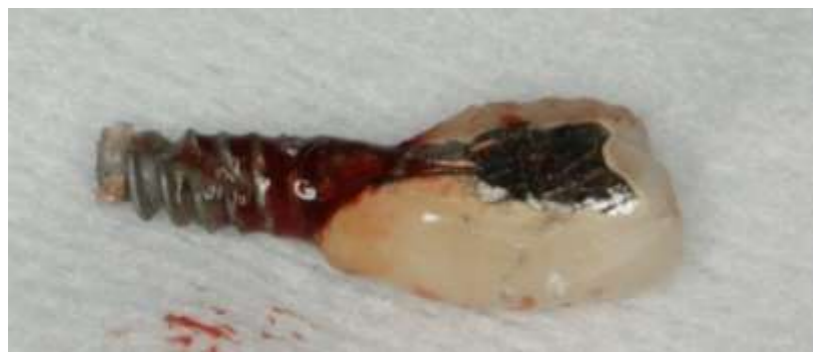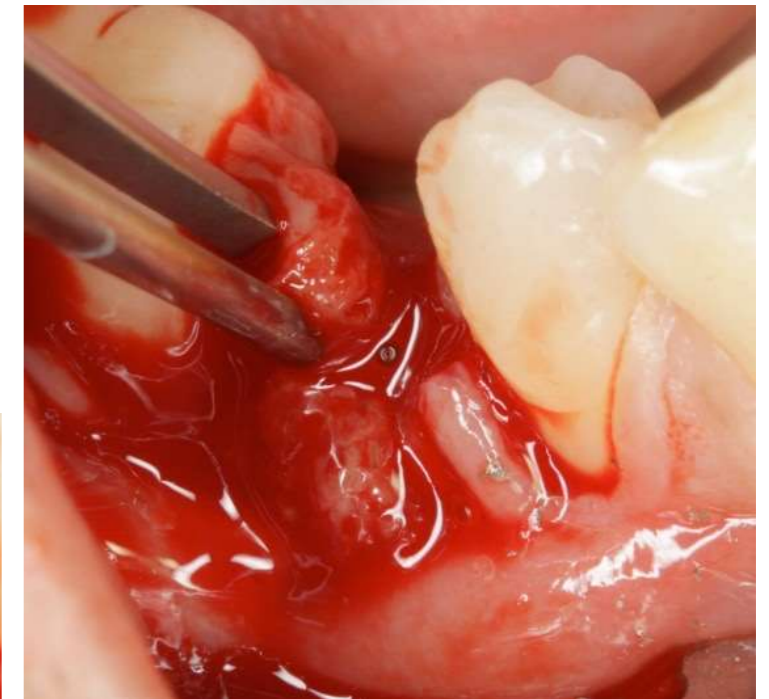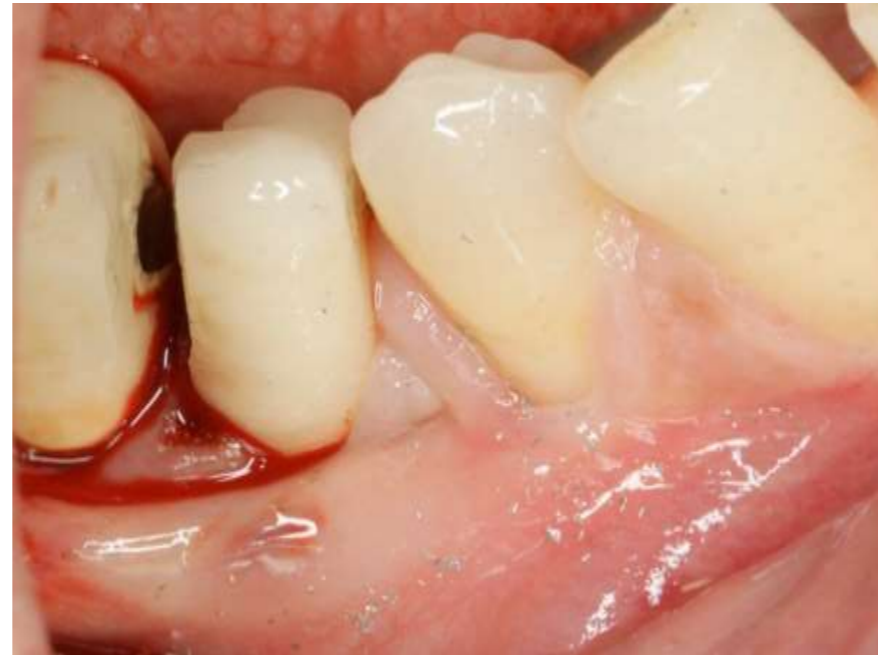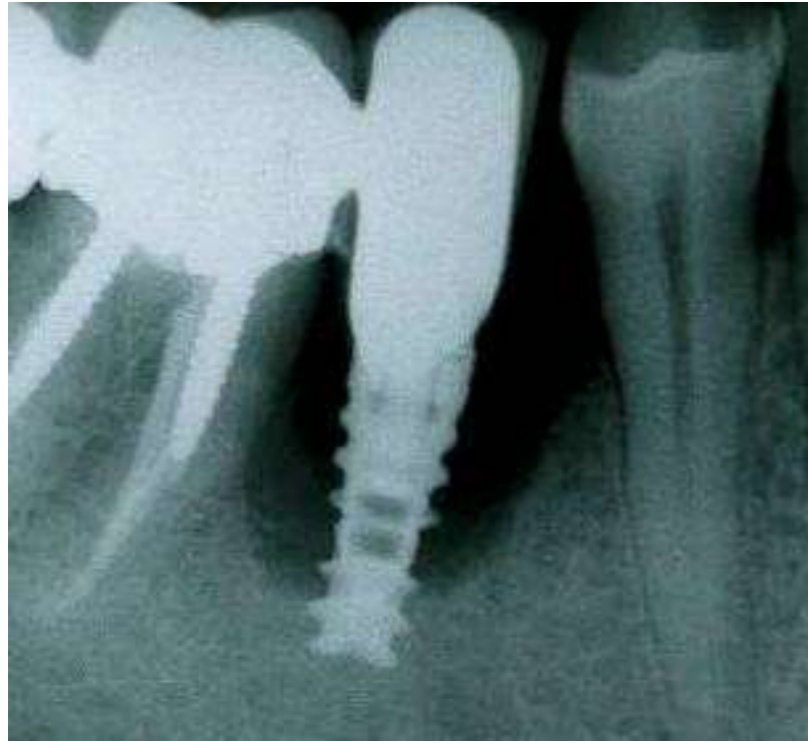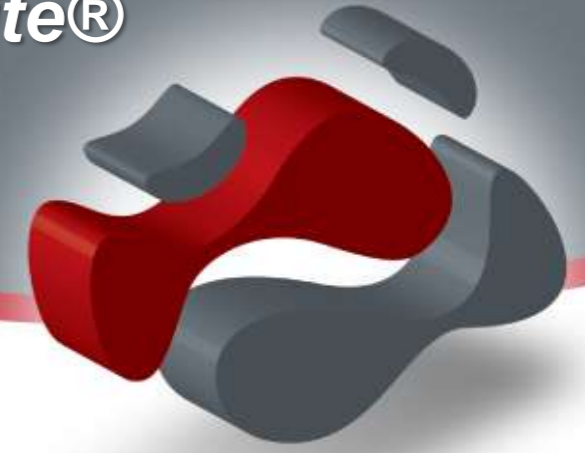


After



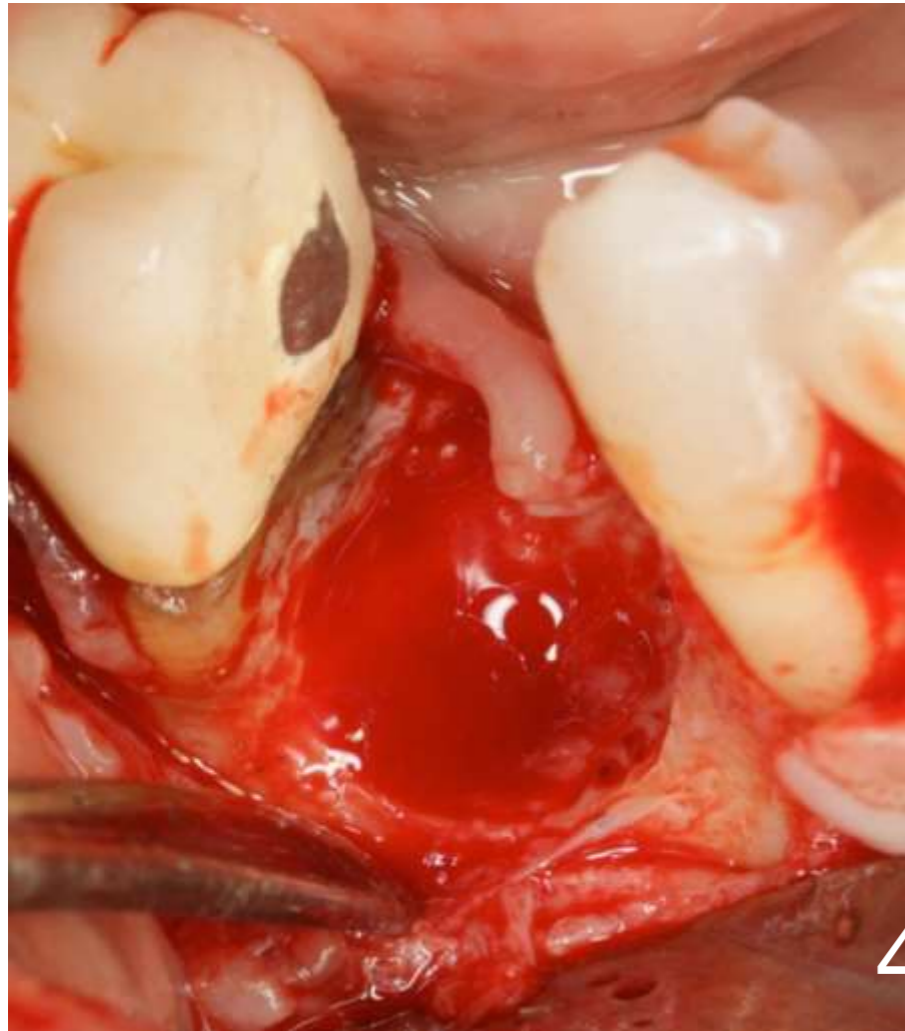
**Ziv Mazor D.M.D**

# Augmentation post implant failure using Bond Apatite®

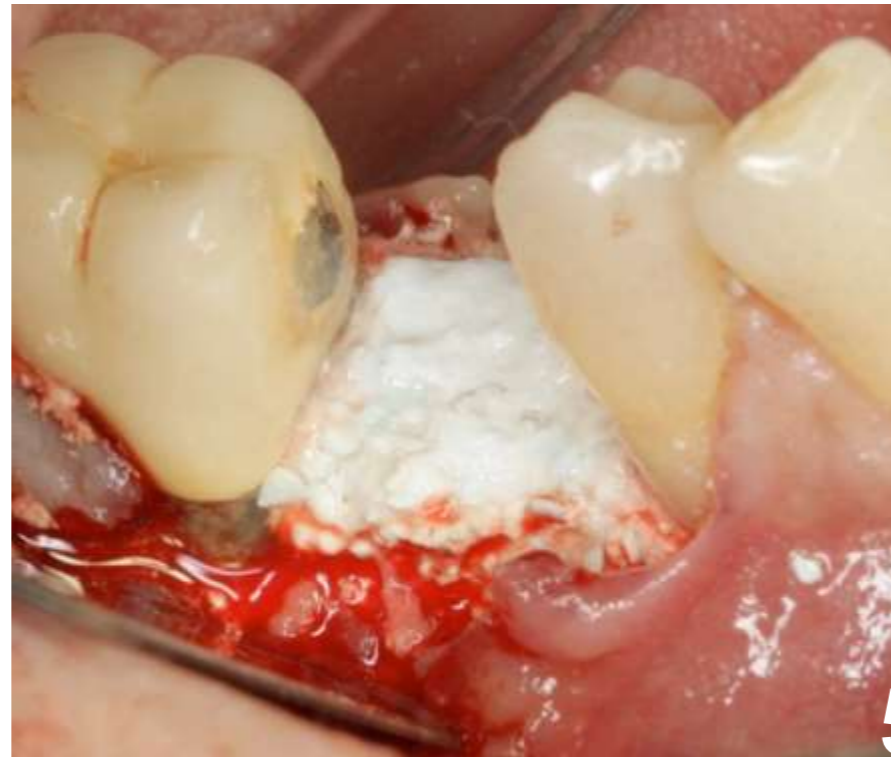

**Bond Apatite®**  
Bone Graft Cement

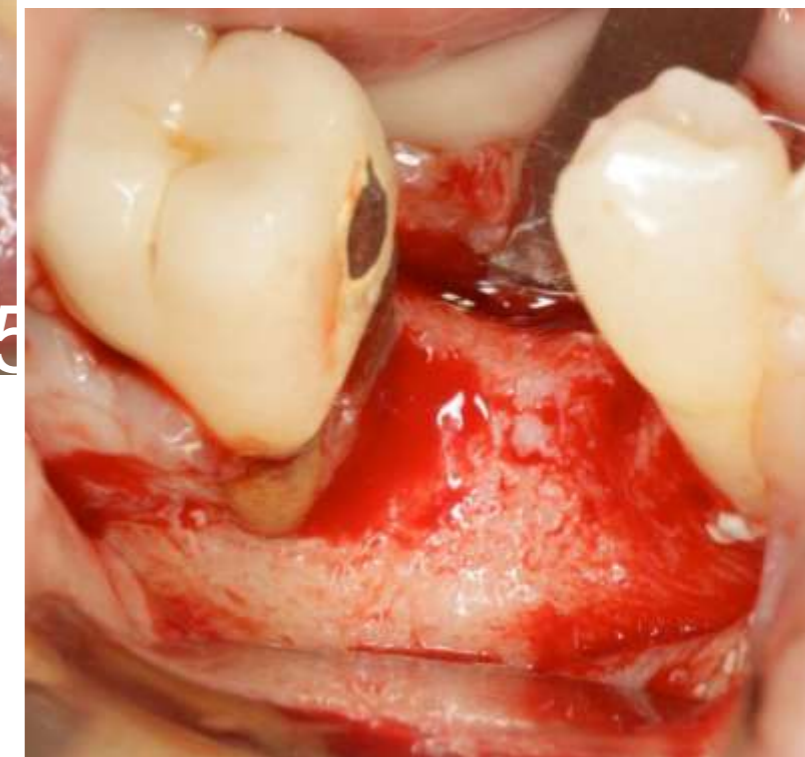  
**Augma**  
BIOMATERIALS



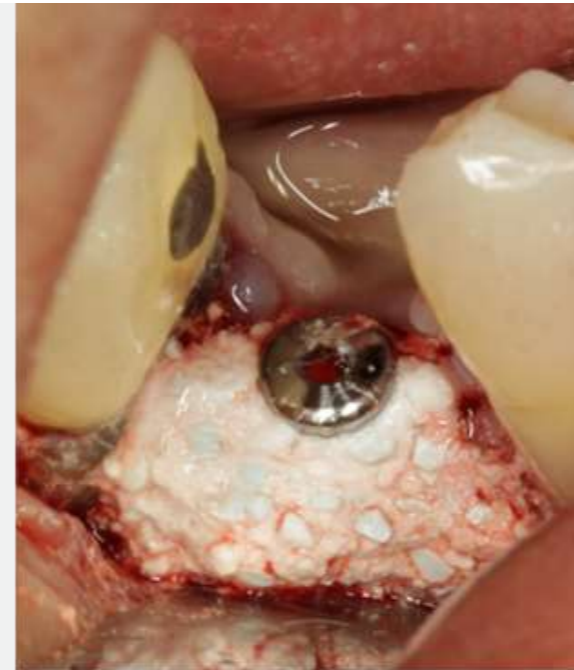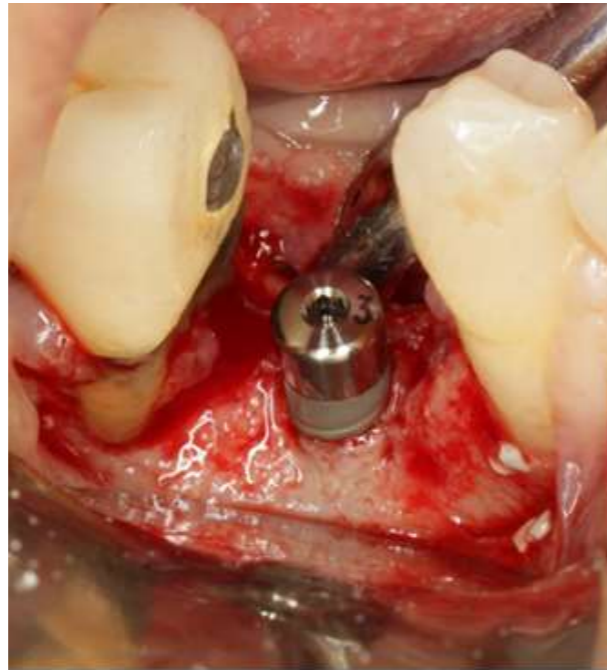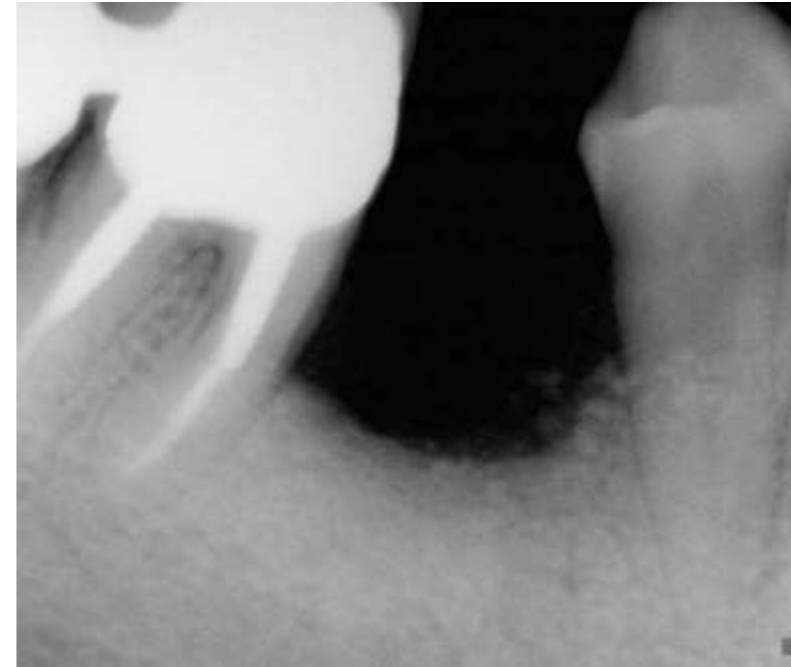
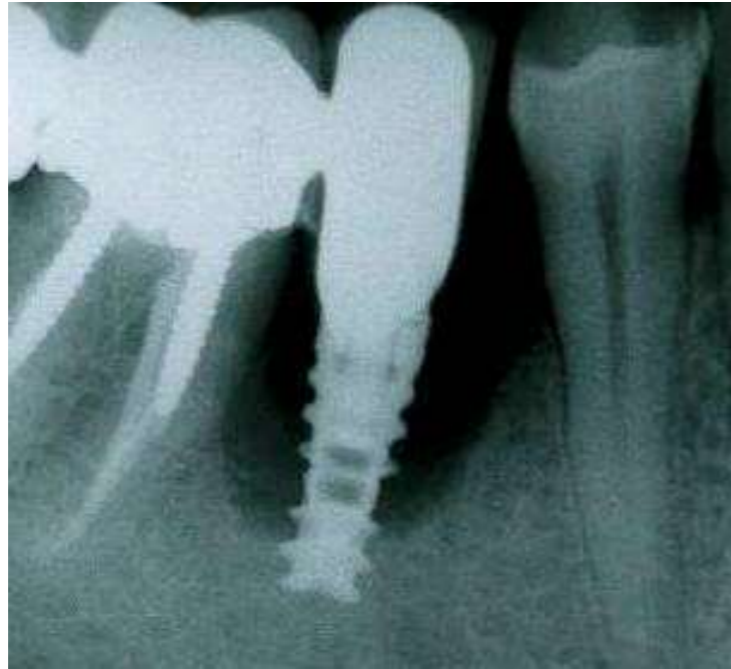Large bone deficiency  
Post implant removal



Bond Apatite® in place



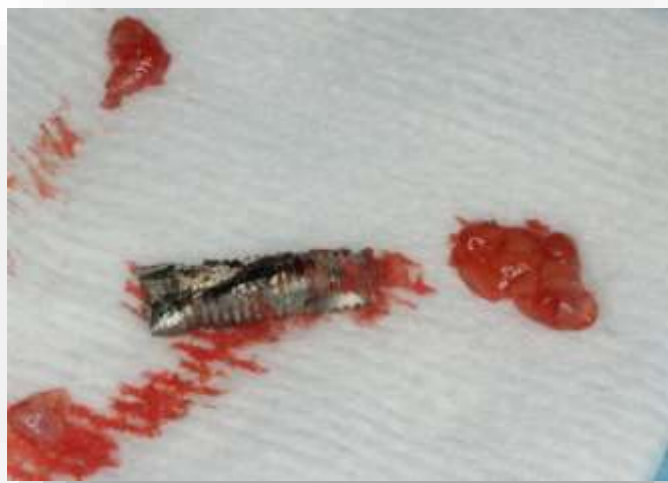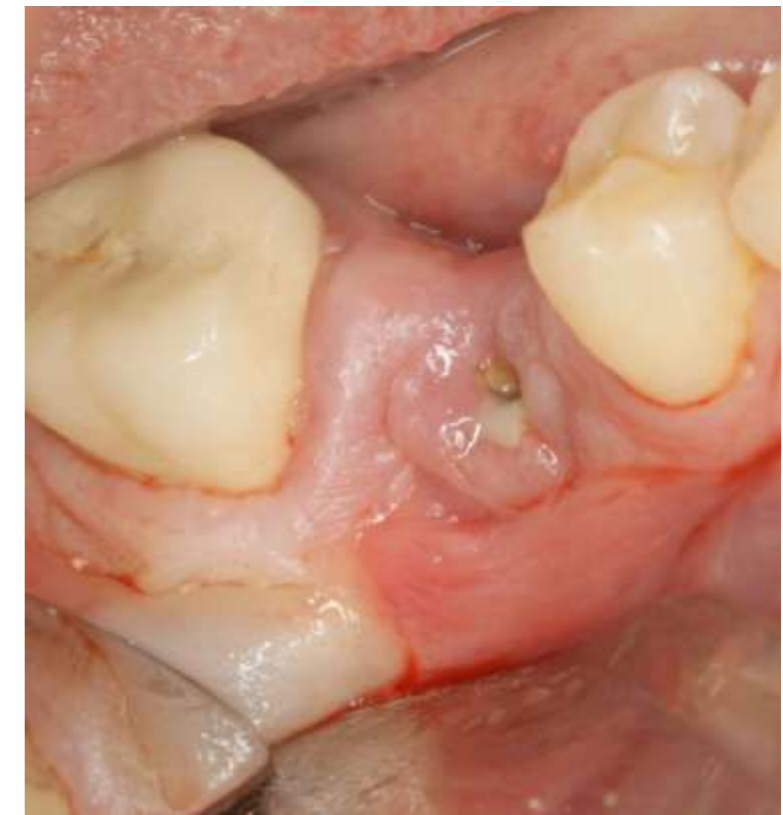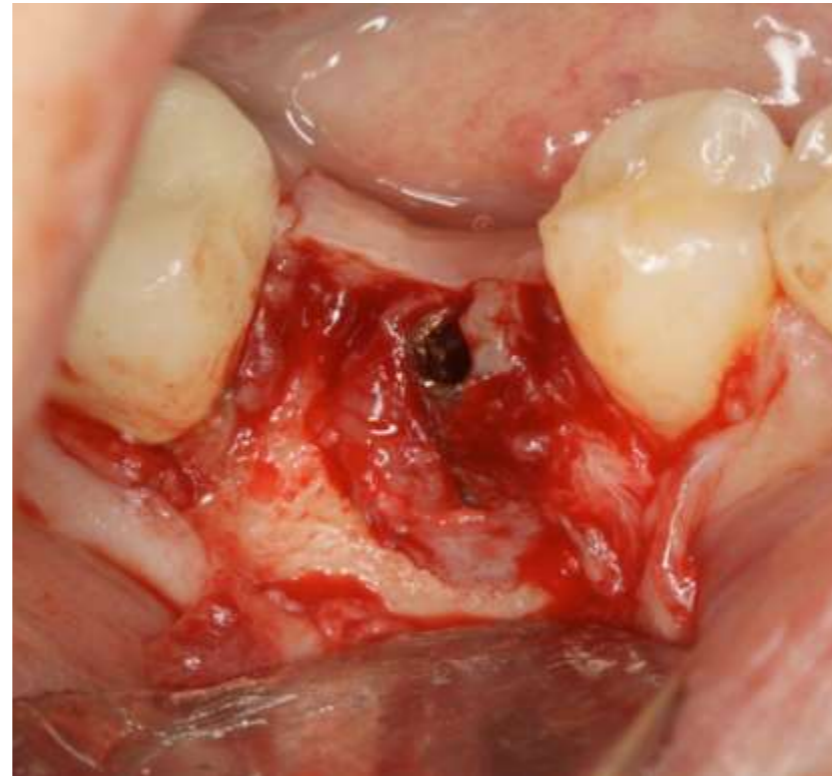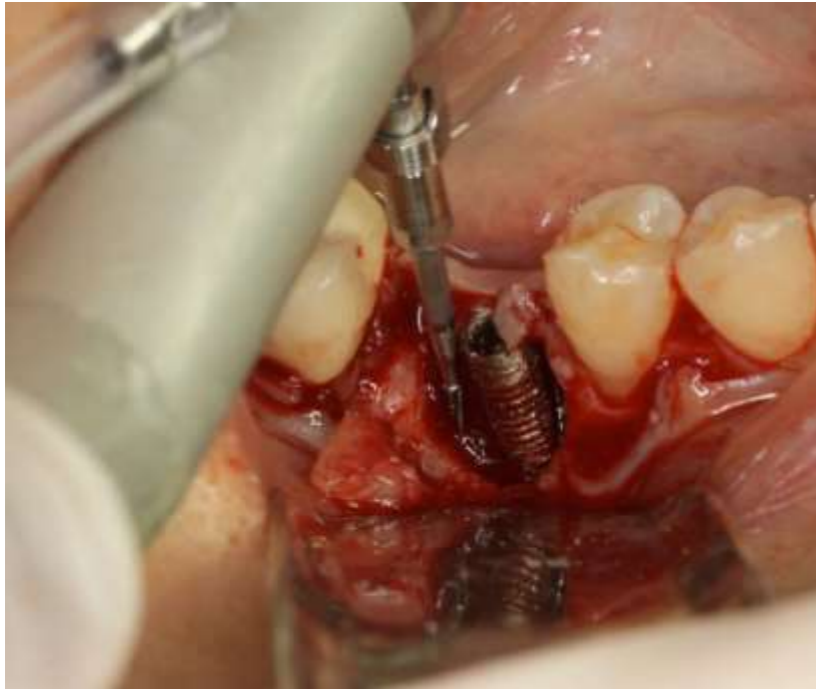
New bone formation 3 month post op



**Bond Apatite<sup>®</sup>**  
Bone Graft Cement

  
**Augma**  
BIOMATERIALS

# Removal of broken implant due to prosthetic failure



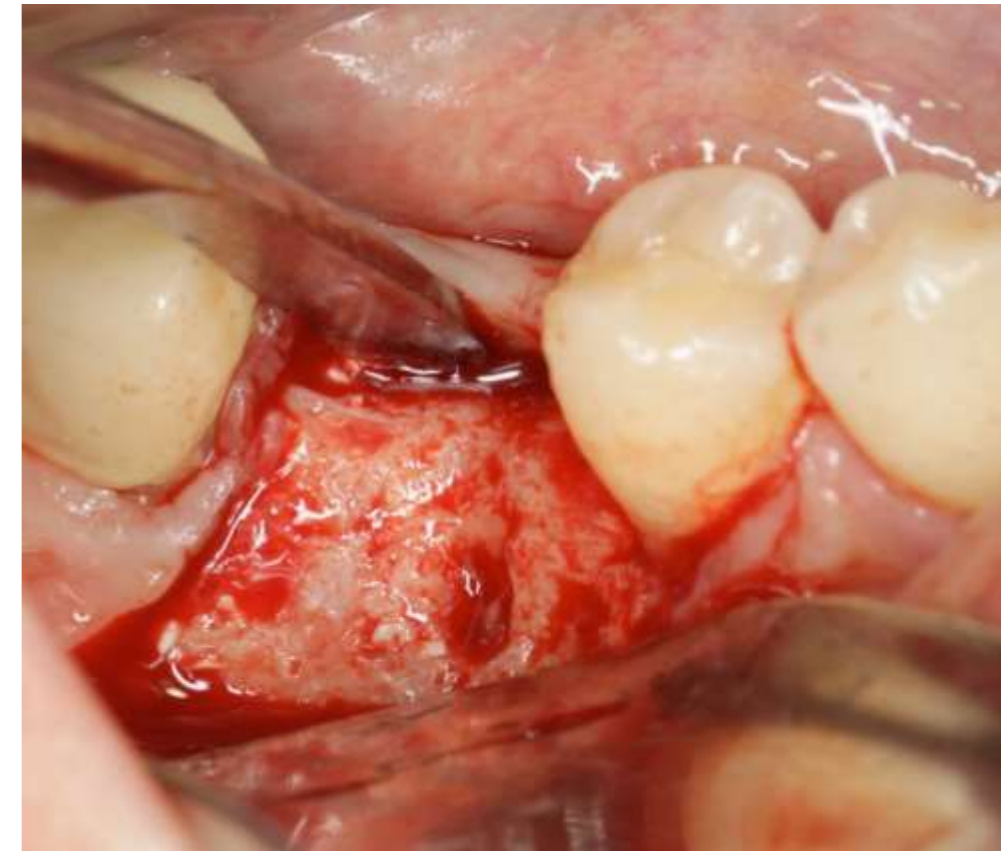
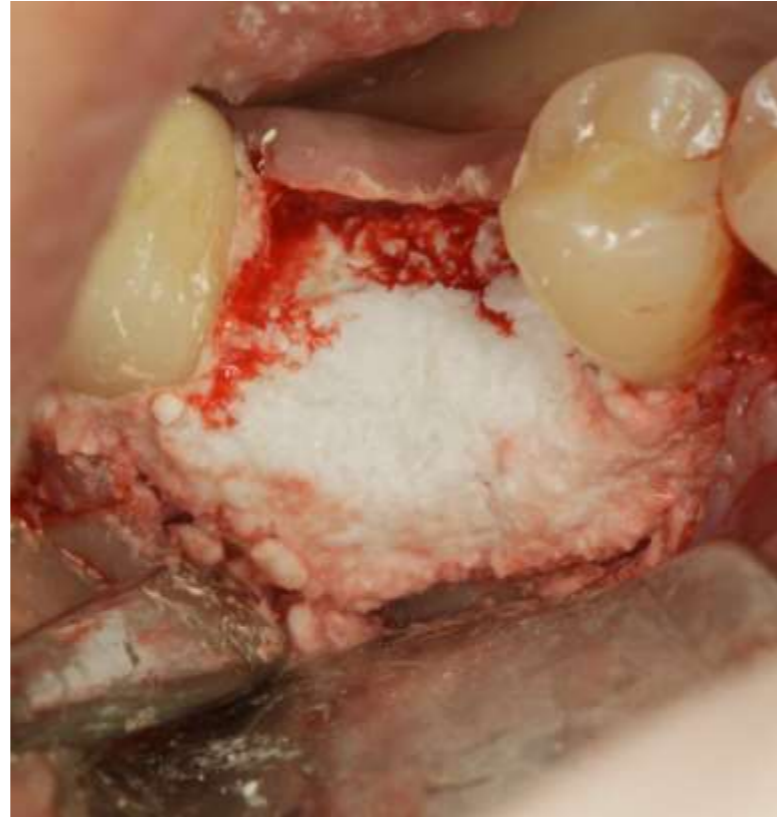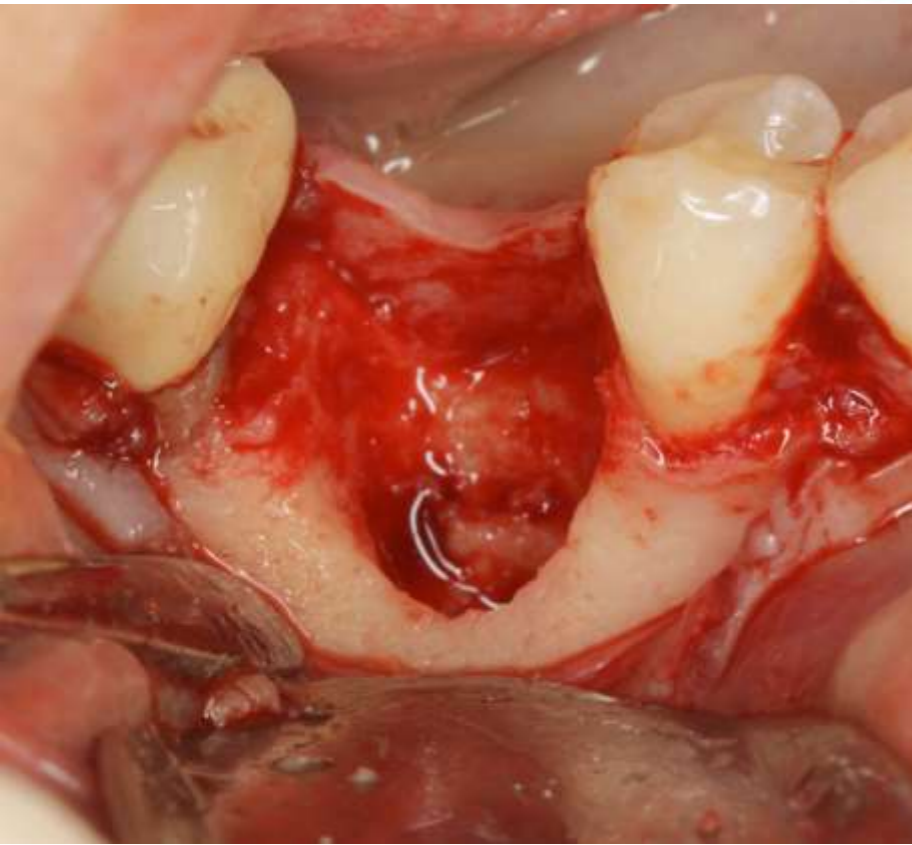
**Bond Apatite®**  
Bone Graft Cement

  
**Augma**  
BIOMATERIALS

# Augmentation using Bond Apatite®



3 month post op



# Soft tissue and radiographic appearance

